

Natural Tooth Pontic - A Support for Periodontally Compromised Dentition

Himanshu Aeran^{1,*}, Suresh DK², Jyotsna Seth³, Mehak Kaul⁴

¹Director Principal/Professor and Head, ³Reader, Department of Prosthodontics,
²Professor and Head, ⁴Postgraduate Student, Department of Periodontics and Implantology,
Seema Dental College & Hospital, Rishikesh, Uttarakhand, India

***Corresponding Author:**
E-mail: drhimanu@yahoo.com

ABSTRACT

Tooth loss in the anterior region is for most of the patients a deeply traumatic experience as they have to compromise with their aesthetics. Natural tooth pontic is the most simplest and cost effective treatment modality for the replacement of a periodontally involved tooth using a patient's own natural coronal portion. It can be considered a hygienic, non-invasive and long-term provisional treatment, providing superior aesthetics and functions. Besides having these many advantages an added advantage to it is that, it is a chairside technique without any time consuming laboratory procedures. This case report details the case selection, procedure with follow-up of a case where the natural extracted tooth of the patient was used as a pontic to replace a missing anterior tooth. This was done using a ligature wire and a composite with added benefit of periodontal stabilization.

Key words: *Natural tooth pontic, splinting, tooth mobility*

INTRODUCTION

Esthetics is the main concern to a patient and the main reason for which a patient consults a dentist. Tooth loss in esthetic zone can be because of trauma, any periodontal disease, failed endodontic therapy or root resorption and the treatment to this can be very challenging for dentist and such kind of patients who have their esthetics as of prime concern need immediate treatment. Most of the patients demand immediate treatment because they usually suffer from psychological trauma and their social life gets affected by compromised esthetics. One of the best ways for the replacement of a missing tooth is the placement of a dental implant, but high cost of implant prevents use of it and as a result less expensive treatment options should be considered. Another modality for the replacement of missing tooth is Fixed partial denture like bridge but it requires preparing of adjacent teeth and using them as abutments to support pontic and it is not a very conservative type of restoration because there is always chance of loss of adjacent prepared teeth by caries or periodontal disease. Another method for replacement of missing tooth is removable partial denture which is not acceptable by many patients.¹ For a periodontally compromised dentition splinting teeth to each other allows weakened teeth to gain support from neighbouring ones. When used to connect periodontally compromised teeth, splinting can increase patient comfort during chewing.²

Use of patient's own tooth as a pontic and bonding it to adjacent teeth is more conservative and less time consuming when compared to other techniques. As these kind of patients suffer from

severe psychological trauma due to loss of tooth in esthetic zone, this technique is of great use because it brings the patient's smile back to his or her face and more than patient's tooth, their confidence gets restored.¹

A natural tooth pontic offers the benefits of being the right size, shape and color. When the crown of the tooth is in good condition, it can be temporarily bonded easily to the adjacent teeth with light-cured restorative material. This paper describes clinical steps of natural tooth pontic as a restorative option for replacement of extracted periodontal compromised mandibular right central incisor.

CASE REPORT

A male patient aged 38 years reported to the Department of Periodontology, Seema Dental College and Hospital, Rishikesh with the chief complaint of loosening of lower right front tooth. The patient was diagnosed with generalized chronic periodontitis. In particular to the tooth i.e. 41 in which he desired immediate treatment, clinical examination revealed gingival recession with 8 mm loss of attachment. Diagnosis was made as Miller's Class IV gingival recession along with grade III mobility. On radiographic evaluation it was seen that the bone loss exceeded beyond the apical third of the root so the tooth was indicated for extraction due to poor periodontal condition. Patient had no relevant past medical or dental history. The periodontal health of 32 and 42 was not favourable for fixed prosthesis. Phase I periodontal therapy was carried out and patient was recalled after 4 weeks for re-evaluation. After assessing the condition and considering the

patients need for immediate replacement and esthetic concerns, a Natural tooth Pontic was planned after extraction of 41 as the crown portion was intact a ligature wire of 0.25mm was used as a retainer to impart strength.

Under local infiltration, using a periosteal elevator the diseased tooth was extracted carefully without any trauma to the tooth. Following extraction, root was resected. The root of tooth was resected 4 mm below cement-enamel junction with a 556 bur (SS White Burs), pulp chamber was opened, pulp was extirpated and obturation was done at chairside. Resected part was finished and polished with pumice, washed and dried. Recess grooves were placed into the pontic and the adjacent abutment teeth.

A modified ridge lap design was given to the natural tooth pontic which satisfied both oral hygiene and esthetics. Ligature wire was embedded into this preparation and bonded with composite, which increased the retention of the tooth pontic. This was then bonded to the adjacent teeth using light cure composites. Stability was checked and oral hygiene instructions were given. Patient was recalled after 4 weeks.

DISCUSSION

Tooth mobility refers to any degree of perceptible movement of faciolingually, mesiodistally or axially when a force is applied to tooth. The various causes are chronic inflammation, trauma from occlusion, pregnancy and periodontal involvement which is the most common cause of mobility.³ Tooth splinting may be indicated for individual mobile teeth as well as for an entire dentition in cases where extraction and implant therapy is not a viable alternative. These can be successfully managed by retaining the tooth through more conservative methods like splinting. The overall objective of splinting is to create an environment where the tooth movement can be contained within physiological limits, thereby improving patient comfort and the restoration of function.⁴

Provisional splints are indicated for a limited time period. They will provide information as to whether teeth stabilization will have benefits before planning comprehensive treatment. Examples include ligature wires, nightguards, and interim fixed prosthesis, composite resin splints (with or without wire and fiber support). Definitive splints are placed only after completion of periodontal therapy and achievement of occlusal stability. They are intended to increase functional stability and improve esthetics on a long term basis.⁴

When a periodontally compromised tooth in the visible or esthetic zone is planned for extraction, the primary concern of the patient is of esthetics. There are various options which can be given to the

patient like acrylic RPDs or the extracted natural teeth can be used as a pontic. The acrylic RPDs are bulky and uncomfortable to the patient. Prefabricated denture teeth can be used as a pontic when bonded to the adjacent teeth. They present challenges with regard to color matching, size and shape matching. They may require substantial modifications to achieve an acceptable appearance. Implant supported prostheses may not be the best option due to severe localized soft and hard tissue loss.

Using the natural tooth as a pontic offers the benefits of being the right shape, size, and color. Moreover, the patient gets an added boost on seeing his own tooth being used instead of an artificial one. These natural tooth pontics can be splinted to the adjacent teeth by composite resins, with or without wire reinforcement.¹ Splint using ligature wire is quite beneficial to the patient and is often used when anterior teeth require splinting. Ligature wire is a soft round stainless steel wire with a diameter of 0.25 to 0.30 mm which is often used and most recommended for splinting in periodontally compromised dentition.⁵

This technique cannot be used for every patient and some important factors should be considered before performing such restorations which among them are: patient's bite, interfering parafunctional habits, inadequate occlusal clearance space for reinforced fiber or orthodontic wire composite resin bonding, inability to maintain isolation of field during bonding procedures, primary dentition and high esthetic expectations of patient, but this technique also has some advantages like: good aesthetic results, preservation of natural crown structure, no laboratory work required, reduced psychological impact on the patient, this technique is reversible and allows other restorative options to be evaluated, micro-resiliency of pontic allows stimulation of underlying tissue and avoids excessive post-extraction ridge resorption.¹ In a study by Kermanshah and Motevasselian⁶ the number of patients treated by them were limited and cavity preparations was done on the adjacent teeth which were restored with composite resin along with the splint material and the reported study did not elaborate on the potential discoloration of the pontic over the years. Quirynen et al.⁷ have done a long term prospective study using natural teeth and acrylic resin teeth as pontics following loss of lower anterior teeth due to periodontal breakdown have reported a favorable long term results. It must be emphasized to the patient to avoid heavy biting pressure on the splinted teeth. All eccentric movements should be recorded and relieved. In case of accidental trauma to that area and loss of the pontic, the option of using an artificial denture tooth can be used.⁴

CONCLUSION

This immediate provisional restoration allows for exact repositioning of the coronal part of the extracted tooth in its original intraoral three dimensional position and thus relieves the apprehension of the patient caused by the sudden loss of an anterior tooth. Thus this procedure to a great extent helps in regaining esthetics and providing patient satisfaction. Appropriate patient education and instruction to clean the gingival embrasures and avoid having heavy bite is very critical and important.

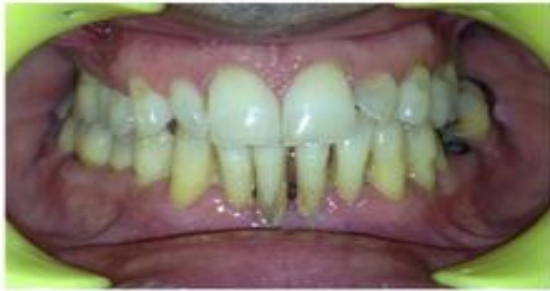

Fig. 1: Before SRP

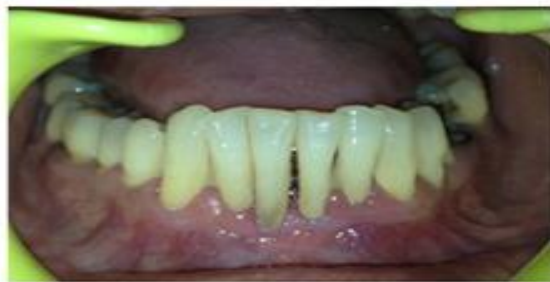

Fig. 2: 4 Weeks Post SRP

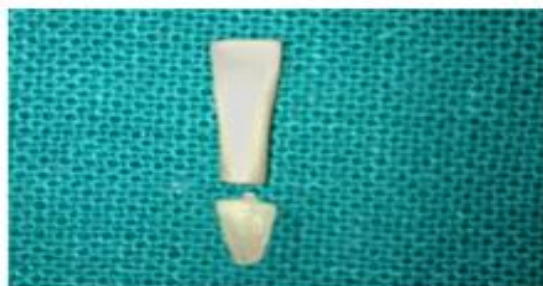


Fig. 3: Root Resection 4mm below CEJ

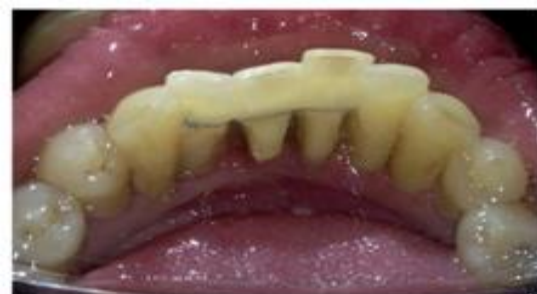

Fig. 4: Composite Splinting with Wire

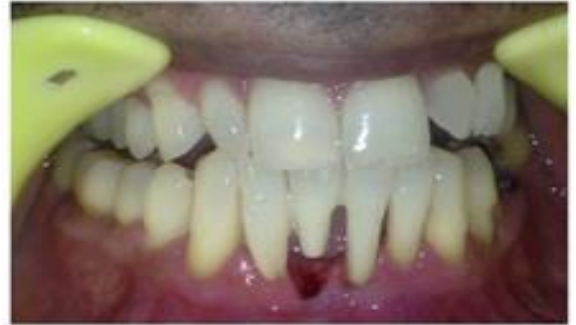

Fig. 5 Natural Tooth Pontic

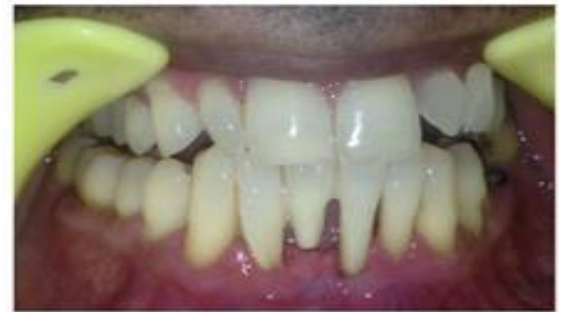

Fig. 6: Post Operative after 4 Weeks

Conflict of interest: None

REFERENCES

1. Moezizadeh M. Natural tooth pontic in periodontally compromised tooth. *Int J Dent* 2011; 1(3):20-4.
2. Barzilay I. Splinting Teeth — A Review of Methodology and Clinical Case Reports. *J Can Dent Assoc* 2000; 66:440-3.
3. Mohan R, Jain R, B J Amarnath J, M Krishna K. Natural tooth pontic: Single visit fibre reinforced splinting. *J Adv Med Dent Scie* 2013; 1(2):144-146.
4. Srinidhi G, Raghavendra SS. Natural tooth pontic with splinting of periodontally weakened teeth using fiber-reinforced composite resin. *J Dent Allied Sci* 2014;3:43-6.
5. Bernal G, Carvajal JC, Munoz-Viveros CA. Clinical management of mobile teeth. *J Contemp Dent Pract* 2002; 4(3):10-22.
6. Kermanshah H, Motevasselian F. Immediate tooth replacement using fiber-reinforced composite and natural tooth pontic. *Oper Dent* 2010; 35:238-45.
7. Quiryren M, Mongardini C, Lambrechts P, Geyseler CD, Labella R, Vanherle G, et al. A long term evaluation of composite bonded natural/resin teeth as replacement of lower incisors with terminal periodontitis. *J Periodontol* 1999; 70:205-12.