

MAXILLARY GROWTH CONTROL WITH HIGH PULL HEADGEAR

Nadeer. T^{1,*}, Rosaline Tina Paul², Althaf T. Rasheed³, Midhun Vinod⁴,
Saveen NS⁵, Lakshmi Lakshmanan⁶

^{1,2,3,4,5}Post Graduate Student, ⁶Senior Lecturer, Dept. of Orthodontics, Royal Dental College, Palakkad.

***Corresponding Author:**

E-mail: nadeert1987@gmail.com

ABSTRACT

The use of headgear has several clinical applications like distalization, restricting maxillary growth and anchorage control. The main being control of the vertical maxillary excess. In this article a 10 yr old patient with a high pull headgear for a period of 8 months is detailed. Cephalometrically the result indicates the use of high pull headgear causes both skeletal and dentoalveolar changes.

Key Words: High pull headgear, Maxillary splint, Intrusion

INTRODUCTION

Class II malocclusion can be dental and/or skeletal, involving, maxillary excess, mandibular deficiency, or a combination of both. The characteristic finding of increased maxillary growth resulting in vertical maxillary excess can be observed as a gummy smile, an increased lower anterior facial height or increased display of incisors. Excessive growth of the maxilla in children with class II malocclusion has more of vertical than anteroposterior component, and if the maxilla moves downward, the mandible rotates downward and backward¹.

The treatment modality to correct vertical maxillary excess is by using a high pull head gear in growing patient and orthognathic surgery in non growing patients. Usage of mini implants is also another alternative in such patients.

The use of headgear dates very long back and has found a variety of clinical application in contemporary orthodontics like distalization, restricting maxillary growth and anchorage control. Animal studies reveal that absolute distalization of maxilla and maxillary dentition is possible by heavy head gear forces for prolonged period.

The force vector should travel through the centre of resistance of the maxilla² when we want a bodily movement of the maxilla. The centre of resistance of maxilla exists at the posterior-superior aspect of the zygomatico-maxillary suture (fig 1).

In this paper, we present a case demonstrating the maxillary growth control with high pull head gear. The high pull head gear with maxillary splint allows vertical forces to be directed against all the maxillary teeth-not just the molars-and appears to have a substantial maxillary dental and skeletal effect with good vertical control.

CASE REPORT

A 10 year old female patient, in her pre-pubertal growth status exhibited a prognathic maxilla, retrognathic mandible with a vertical growth pattern and class II skeletal base. There was an increased incisor exposure at rest and smile with proclined incisors.

The treatment objective was to restrain the forward and downward descent of the maxilla due to growth. It was decided to treat the patient with are movable high pull head gear splint (fig 2). The length of the outer bow was kept short so that forces passed through the centre of resistance of the maxilla with a force magnitude of 600 gm per side (fig 3). The patient was instructed to wear the head gear full time except while eating brushing and bathing. As the patient had potentially incompetent lips, she was also instructed to perform lip exercise by forcefully closing her lips on to the bows.

Recall visits were scheduled at 3 weeks interval and force levels were checked and maintained. The force values of the head gear module were measured during each visit and the patient was advised to step up the attachment to the next hole accordingly.

RESULTS

After 8 months of full time wear of the appliance (as recommended by Marcotte)³ the bite was opened, with a reduction in incisor visibility (fig 4 & 5). The over jet was reduced from 5mm to 3mm (fig 6 & 7). Pre and Post treatment cephalometric tracing (fig 8 & 9) showed that growth of the maxilla was restrained. (Table 1)

The cephalometric changes showed that the mid face height was reduced by 2 mm (N-ANS). The lower anterior facial height reduced by 5 mm. There was dento-alveolar intrusion as the distance of incisal tip to the palatal plane reduced by 6 mm. The SNA angle improved indicating a reduction in maxillary

growth. The SNB angle mildly improved due to forward and upward rotation of mandible, which is

also indicated by mild reduction in mandibular plane angle.

Table 1:

Measurements	Normal	Pre Rx	Post Rx
Nasion -ANS	50 ± 2.4 mm	51 mm	49 mm
ANS-Gnathion	61.3 ± 3 mm	68 mm	63 mm
Perpendicular distance from palatal plane to incisal tip	27.5±1.7 mm	31 mm	25 mm
SNA	82±2 ⁰	85.3 ⁰	81.9 ⁰
SNB	80±2 ⁰	74.6 ⁰	75.9 ⁰
ANB	2±2 ⁰	10.7 ⁰	6 ⁰
Inter incisal angle	131 ⁰	109.8 ⁰	102.7 ⁰
Go-Gn to SN	32 ⁰	36.8 ⁰	35.5 ⁰

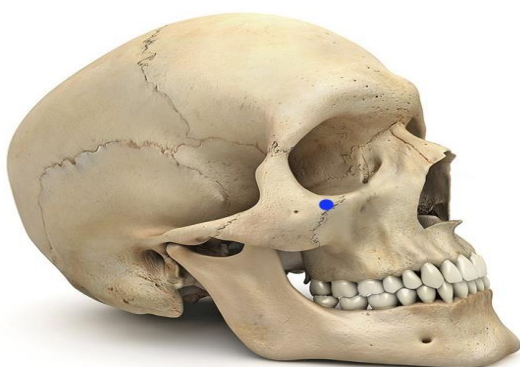

Fig. 1: Centre of Resistance of Maxilla

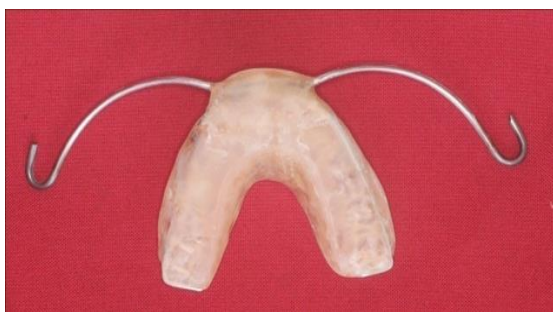

Fig. 2: Intra Oral Splint



Fig. 3: Patient with High Pull Headgear

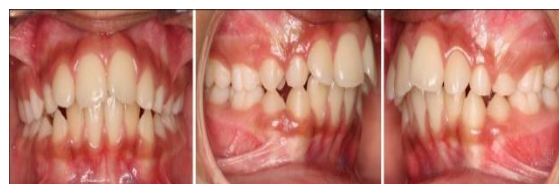

Fig. 4: Pre Treatment Intraoral View

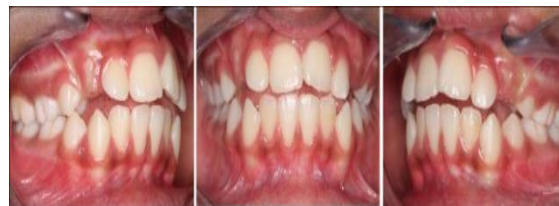

Fig. 5: Post Treatment Intraoral View



Fig. 6: Frontal View-Pre and Post Treatment Photographs

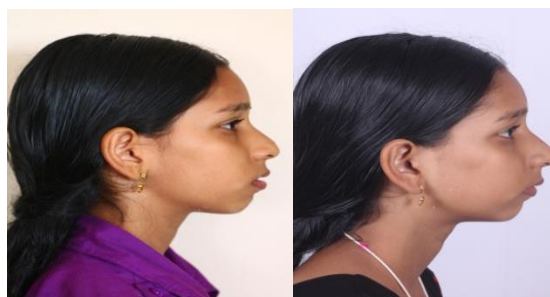

Fig. 7: Lateral View-Pre and Post Treatment Photographs

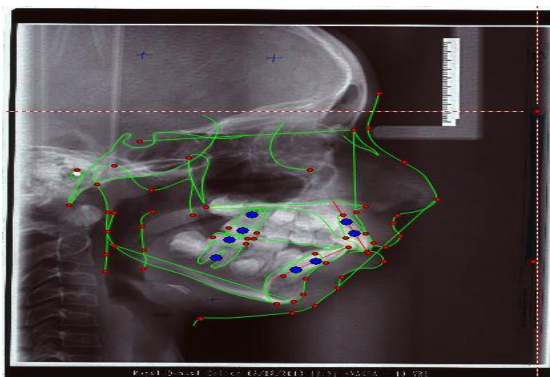


Fig. 8: Pre Treatment Lateral Ceph

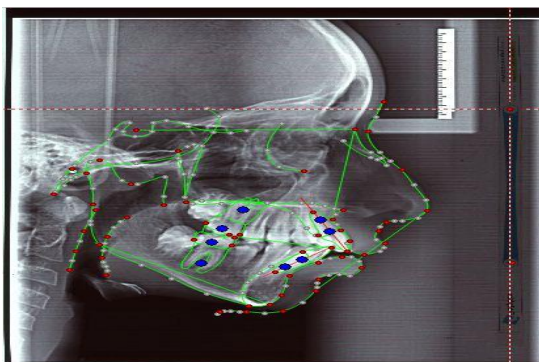


Fig. 9: Post Treatment Lateral Ceph

DISCUSSION

Caldwell et al⁴ used a maxillary splint appliance for a period of 4-20 months and noticed that the maxillary dentition was both tipped and displaced distally, and downward development was inhibited or even slightly reversed. Martin set al⁵ also used similar appliance for a period of 1.7 yrs and noted that the head gear corrected the Class II primarily by dento-alveolar changes. Orton et al⁶ used a high pull headgear with maxillary splint for a period of 1.1 yrs and noted slight maxillary restraint in both sagittal and vertical planes was obtained showing that principal effect was in the maxillary teeth. Under et al⁷ used a similar appliance for 11 months and revealed that the splint had both orthopedic and orthodontic effects on the growth pattern of the dento-skeletal structures.

In our case a full time wear for a period of 8 months has led to both skeletal and dental changes which are evident in the improvement of SNA angle indicating the reduction in maxillary growth. The reduction of lower anterior facial height indicates the upward and forward auto rotation of the mandible which has subsequently improved SNB angle also. Inter incisal angle has reduced indicating proclination of incisors during the treatment. The growth of mandible is unhindered and the absence of an appliance in the lower arch could be the reason for such a proclination in the lower incisors. The

reduction in the mandibular plane angle indicates auto rotation of the mandible.

CONCLUSION

The high pull head gear brought about significant clinical and cephalometric changes in the patient. The advantage of this maxillary splint with high pull head gear were (1) Skeletal and dental changes were significant within a period of 8 months (2) Second phase of fixed appliance therapy was made faster (3) High pull headgear with proper biomechanics at correct period of time with patient cooperation has led to the success of the treatment.

REFERENCES

1. William R Proffit- Contemporary Orthodontics- fifth edition.
2. Biomechanics & esthetic strategies in clinical orthodontics Ravindra Nanda, Elsevier Inc. copyright 2005.
3. Michael R Marcotte. Biomechanics in orthodontics, copyright 1990, Decker publisher.
4. Caldwell SF, Hymas TA, Timm TA. Maxillary traction splint: a cephalometric evaluation. *Am J Orthod.* 1984; 85(5):376-84.
5. Martins RP, Martins JCR, Martins LP, Buschang PH. Skeletal and dental components of class II correction with the bionator and removable headgear splint appliances. *Am J Orthod Dentofacial Orthop.* 2008; 134(6):732-41.
6. Orton HS, Slattery DA, Orton S. The treatment of severe "gummy" class II division 1 malocclusion using the maxillary intrusion splint. *Eur J Orthod.* 1992; 14(3):216-23.
7. Üner O, Yücel-Eroğlu E. Effects of a modified maxillary orthopae dicsplint: a cephalometric evaluation. *Eur J Orthod.* 1996; 18(3):269-86.
8. Class II malocclusion treatment using high-pull headgear with a splint: a systematic review-Helder B. Jacob et al- *Dental Press J Orthod.* 2013 Mar-Apr; 18(2):21.e1-7.
9. Efficacy of high pull headgear in restricting maxillary growth: A clinical study- Namitha Ramesh P.V et al - *JIOS.* 2008 Jan-Mar; 42(1):14-18.