

## POST & CORE: AN EASY AND EFFECTIVE TREATMENT MODALITY FOR SEVERELY DAMAGED TEETH

Shashank Uniyal<sup>1</sup>, Himanshu Aeran<sup>2</sup>, Bhartendu Kwatra<sup>3</sup>, Akanksha Nautiyal<sup>4</sup>

<sup>1</sup>Senior lecturer, <sup>2</sup>Director Principal, Professor & Head, <sup>4</sup>Lecturer, Department of Prosthodontics, <sup>3</sup>Reader, Department of Conservative and Endodontics, Seema Dental College and Hospital, Rishikesh.

**Corresponding Author:**

E-mail: drhimanu@yahoo.com

---

### ABSTRACT:

*The successful treatment of teeth with substantial damage to the tooth structure not only depends on good endodontic treatment, but also by prompt prosthodontic reconstruction of the tooth after the completion of the same. The primary purpose of the post is to retain a core that can be used to retain a definitive prosthesis. A post and core helps to prevent fracture when the remaining tooth structure is very less. When a large amount of tooth structure is lost, a custom cast post and core is indicated. The following case reports depict the interdisciplinary approach to restore function and aesthetic of severely damaged treated teeth by means of full veneer crowns after custom cast post. Coordinated by prosthetic, endodontic treatments with careful consideration of patient's expectations and requirements were critical for a successful outcome & patient satisfaction.*

**Keywords:** Custom cast post & core, Endodontic treatment, Pattern resin, Restoration.

---

### INTRODUCTION

Excessive loss of dental hard tissues creates difficulties for the aesthetic outcome of subsequent prosthetic restorations. In such instances, an interdisciplinary approach is necessary to evaluate, diagnose & restore aesthetic problems using a combination of endodontic and prosthetic treatment. A large variety of materials, techniques to restore structurally compromised endodontically treated teeth.<sup>1</sup> Post and core is endodontically teeth have been utilized for more than a century. Post is a dental material placed in the root of structurally insufficient tooth when additional retention is needed to retain the core & coronal restoration. The objective of the post and core is primarily to replace missing coronal tooth structure sufficiently to provide adequate retention & resistance for the crown that will eventually restore the function and the aesthetic of the tooth.<sup>2,3</sup>

The use of Post & core is still an area of great debate within Dentistry. This debate ranges from dentist who only does cast post, to dentist who uses any of a variety of prefabrication system. Posts can be either prefabricated or custom based post. Prefabricated posts are best suited for circular canals while custom-cast posts and cores possess superior adaptation to all root canals. Custom cast post and core allow for a close adaptation of the post to post space preparation and should fit optimally. Cast posts and cores do not require an auxiliary retention such as pins to retain the core as in some prefabricated systems.<sup>4</sup>

The indications for a post and core restoration are tooth with extensive crown loss, crown susceptible to cervical area fracture, grossly discolored tooth, loss of two proximal surfaces, shortened tooth with insufficient retention form with

favorable periodontal and periapical condition.<sup>5</sup> The fit of the post with the canal walls depends on the configuration and size of the root canal.<sup>6</sup> Prefabricated metal, carbon fiber, ceramic, and glass fiber posts are available. These last two options provide esthetic alternatives to metal posts. They are used in conjunction with a plastic material such as composite resin, amalgam, or glass ionomer. Although one-piece post-crowns were once made, such prostheses are of historical interest only. Superior results can now be obtained with a two-step technique consisting of a post-and core foundation and a separate crown. Most often a metal post is used, which provides the necessary retention for the core. This replaces any lost coronal tooth structure of the tooth preparation. The shape of the residual coronal tooth structure, combined with the core, should result in an ideal shape for the preparation.

With the two-step approach of fabricating a separate crown over a cast post-and-core, achieving a satisfactory marginal fit is easier because the expansion rate of the two castings can be controlled individually.<sup>7</sup> a cast post and core needs to be slightly smaller than the canal to achieve optimal internal seating, whereas the crown needs to be slightly larger to achieve optimal seating. The use of custom- made post is usually accomplished in canals that have a non- circular cross section or extreme taper. Enlarging canals to a pre- formed post may lead to root weakening & perforation.<sup>8</sup> The quick fabrication and exact fitting is the aim of fixed postodontic clinicians, fabrication the resin pattern by the bead-brush technique may lose time and effort for the Dentist.<sup>9</sup> The two-step approach further permits fabrication of a replacement crown, if necessary, without the need for post removal. Finally, a different

path of placement than the one selected for the post-and-core may be selected for the crown. This is often helpful when the tooth is restored to serve as an abutment for a fixed partial denture.

In the case reports that follow, the use of custom cast posts to rehabilitate patients facing esthetic challenges.

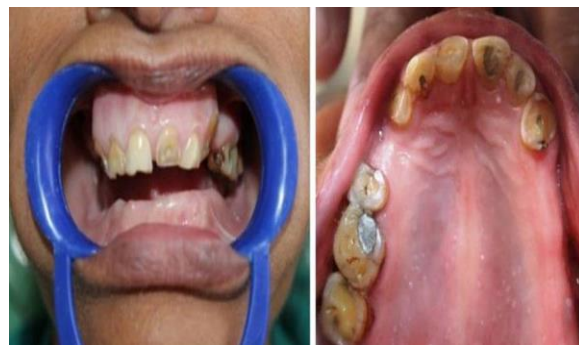### CASE REPORT 1

A 52 year old female patient reported with chief complaint of difficulty in chewing and unesthetic appearance of face because of grossly dilapidated anterior teeth as a result of attrition and abrasion. On Intra oral Examination, teeth 21, 23, 13 were found to have highly destructed crown structure to barely support a restoration. (Figure 1) But the teeth were found to have good periodontal support and were endodontically treated. The root canal obturation was found to be appropriate and there was no sign of periapical pathology in the radiographs. Maxillary teeth 14, 15,16,17 24 and All mandibular teeth were extracted 4 to 5 years back and was wearing conventional complete mandibular denture since 4 years. (Figure 2) Due to Loss of vertical dimension and as her phonetics was altered so the heights of the crowns were estimated according to the smile line. The patient was in good general health, the medical & dental histories were non-contributory. Treatment planning was done after a thorough clinical examination.

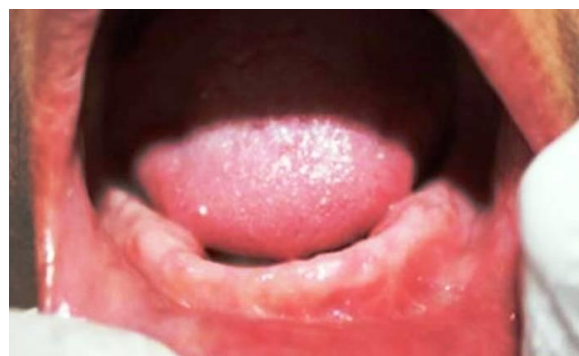### Procedure:

1. The tooth preparation was done in respect to 11, 12, 13, 21, 22, 23 and the canals were prepared using the peeso reamers. Approximately 3-5 mm of guttapercha was left in the canal and the length of the post space was measured with the help of calibrated probe.
2. The post and core patterns were fabricated using plastic tooth pick and pattern resin material. The core portion of the crown was shaped keeping in mind, the position of the future prosthetic teeth. (figure 3)
3. These post and core patterns were sprued and invested and the casting was carried out. (figure 4) The retrieved castings were tried on to the patient's mouth and the final finishing was done intraorally.
4. On luting these posts to the respective teeth, the final impression was made using poly vinyl siloxane impression material using a two stage double mix technique. (figure 5)
5. Metal copings were fabricated for an individual crowns and the try-in was done. (Figure 6)
6. Finally, the finished prosthetic crowns were luted and the jaw relations were recorded for the fabrication of the removable prostheses.(Figure 7)

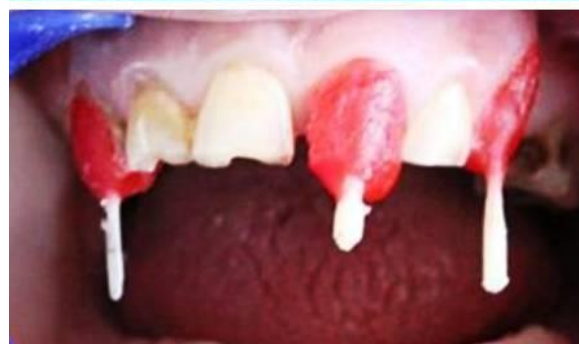
7. The removable prostheses for the maxillary and mandibular arch were finished and inserted into the patient's mouth. (Figure 8)



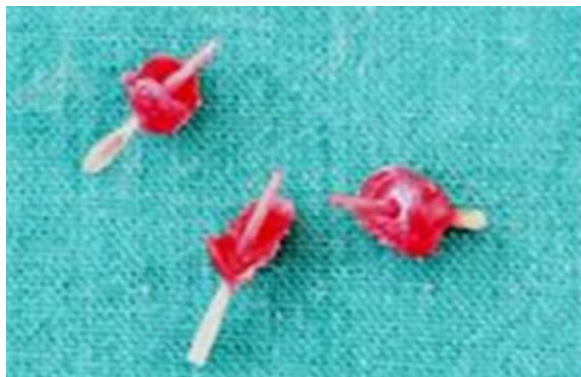**Figure 1: Frontal and Occlusal Pre-operative view of maxillary arch.**



**Figure 2: Pre-operative view Mandible.**



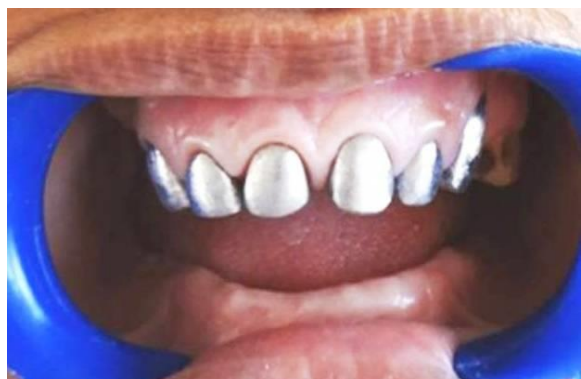**Figure 3: Plastic Tooth picks and Resin post & core patterns (intra -oral)**



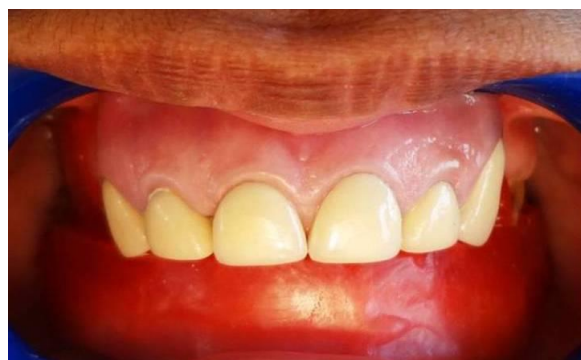**Figure 4: Post and core patterns.**



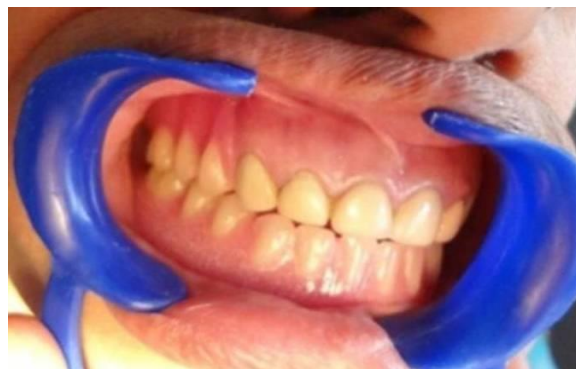**Figure 5: Final Impression.**



**Figure 6: Metal try-in stage.**



**Figure 7: Jaw relations.**



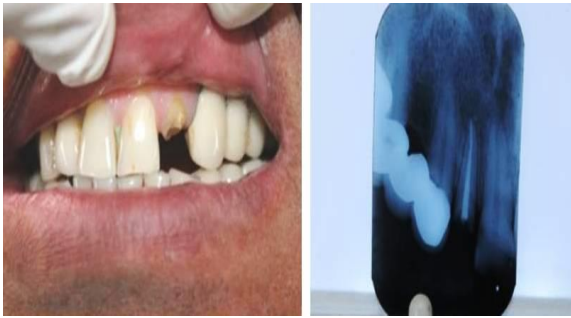**Figure 8: Anterior crown cemented in the patient's mouth.**

### CASE REPORT 2

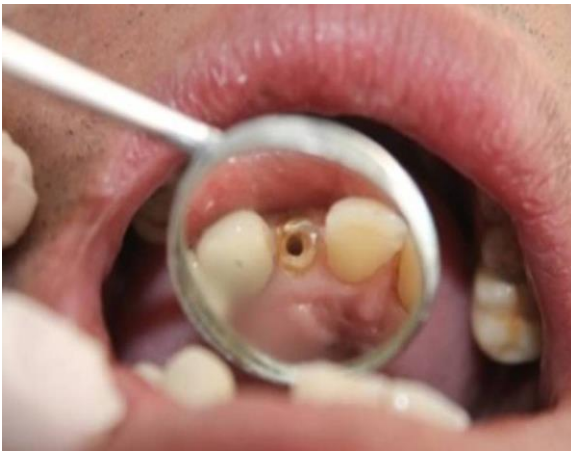A 32 year old patient presented with a chief complaint of left front broken tooth and wanted a fixed replacement for the same. (Figure 9) On examination, the tooth 22 was endodontically treated and fractured. The periodontal support was found to be good with 2mm coronal structure remaining. The endodontic treatment was satisfactorily done and there was no sign of any periapical pathology from the periapical radiograph. A full veneer crown retained by custom made post and core was planned for the tooth after thorough examination.

### Procedure:

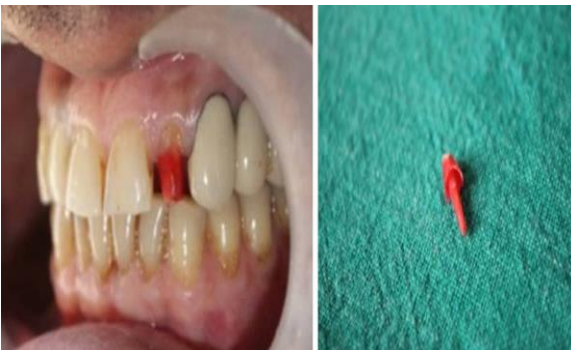1. The gutta-percha was removed from the pulp chamber, leaving 4 mm of gutta-percha in the apical portion of the canal. The canal was shaped with Peeso reamers (Dentsply) to a final diameter of 1.25 mm and a depth of 8 mm from the prepared coronal surface. (Figure 10)
2. The fabrication of custom made acrylic post was done using wooden tooth-picks. The tooth pick was shaped with the help of a scalpel and inserted into the distal canal upto the calculated length; it was made sure that it snugly fit into the canal. After coating the canal with petrolatum gel, pattern resin was added on the tooth pick by brush bead technique. The post was inserted into the canal while the material was still in dough stage. (Figure 11)
3. The post was sprued and invested. On reaching the burnout temperature, the casting was carried out. The casting was retrieved and was tried in the patient's mouth. The finalised post was cemented using the zinc phosphate cement. (Figure 12)
4. The final impression was made for the patient using addition silicone putty and light body with the putty-reline technique. Porcelain fused to metal crown was fabricated. The final cementation of the crown was done and the patient was satisfied with the esthetic outcome. (Figure 13)



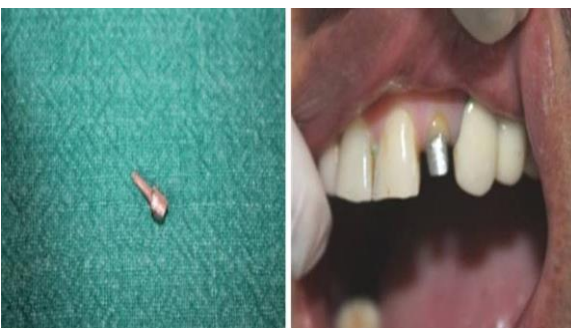**Figure 9: Intra Oral view with preoperative Radiograph.**



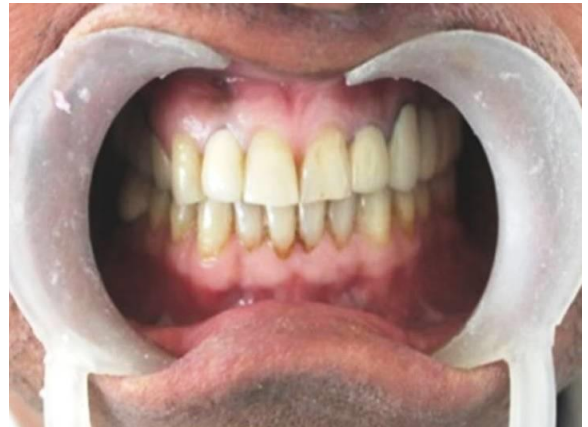**Figure 10: Post space Preparation.**



**Figure 11: Resin Pattern Fabrication of post and core.**



**Figure 12: Custom cast post retrieved and was cemented in patient's mouth.**



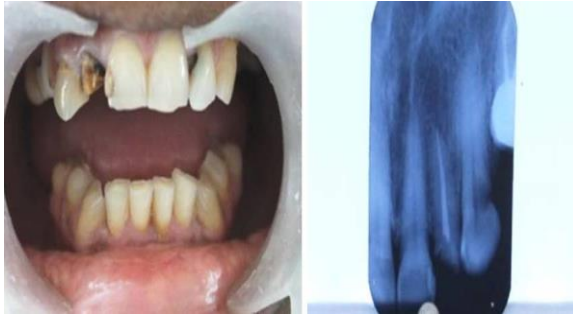**Figure 13: Final prosthesis cemented.**

### CASE REPORT 3

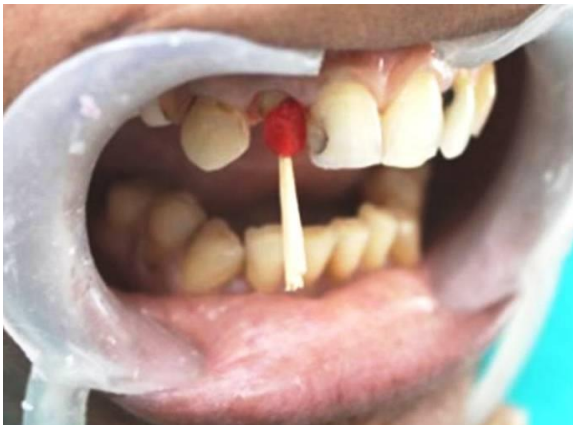A 38 year old patient reported to the department with a chief complaint of broken and decayed tooth. On examination, the tooth remaining portion of the clinical crown in respect to 12 was found to be carious and the excavation was done which resulted in the approximation of cemento-enamel junction. (Figure 14) Post space was prepared and the coronal portion of the crown was given a sub gingival margin to enhance retention. The tooth was replaced with a ceramo-metal crown supported by a metal post.

### Procedure:

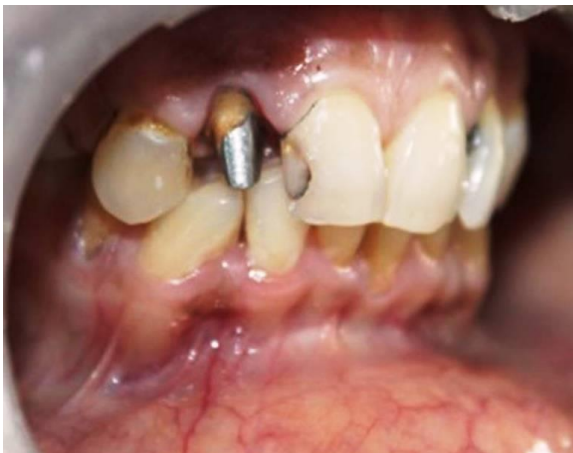1. After removing the gutta percha, the canals were prepared with the help of peizoreamers while leaving 4 mm of guttapercha for the apical seal.
2. The canal was lubricated and the loose fitting plastic dowel was notched and the extension was made till the full depth of the prepared canal. The bead-brush technique was used to add resin to the dowel and the dowel was reseated into the prepared canal. Once the pattern was complete, additional material was added for the fabrication of the core. (Figure 15)
3. The final pattern was sprued, invested and cast in base metal alloy. After finishing, the casting was luted with the help of resin cement using a metal primer. (Figure 16)
4. The final impression of the patient was made after the post cementation and the temporization was done. In the following appointment, the final prosthesis was cemented and an esthetics outcome achieved. (Figure 17)



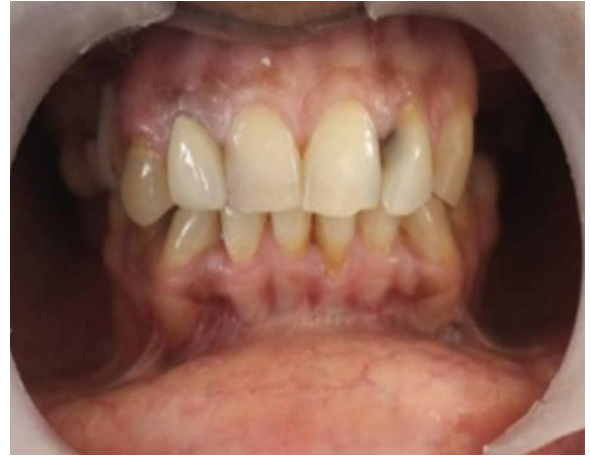**Figure 14: Intra Oral view with preoperative Radiograph.**



**Figure 15: Fabrication of resin pattern.**



**Figure 16: Custom cast post cementation.**



**Figure 17: Final prosthesis cemented.**

## DISCUSSION

A post-and-core restoration is placed in a badly broken-down tooth to restore the bulk of the coronal portion of the tooth to facilitate the subsequent restoration of the tooth by means of an indirect extracoronal restoration. In this case series a custom-cast posts and cores were considered a state of the art for rebuilding endodontically treated teeth. Nowadays, prefabricated posts are becoming much more popular than custom-cast posts and cores.<sup>10</sup> But Cast posts and cores have its own advantages, they include preservation of the maximum tooth structure as the post is fabricated to fit the radicular space with a superior adaptation to the root canal.<sup>11</sup> As core is an inherent part of the post, it does not need to be retained by the post. The anti-rotational property is also an additional advantage.<sup>12</sup> However; it has a disadvantage of involving multiple-visit procedures. Prefabricated cylindrical posts, on the other hand, rely principally on the cement for retention. Disadvantages of this type of posts include decreased core retention to the post and the potential for rotation.<sup>13</sup> as treatment goals must be based upon a multitude of factors and are specific for each patient. The status of the root to be restored is considered to be critical.<sup>14</sup> A brief review of the major concerns in radicular anatomy before restoring an endodontically treated tooth is indicated if a post is to be used. The post preparation should minimally alter the internal anatomy of the root canal. It is essential to leave adequate dentine for support and distribution of post stresses.

The above technique helps in achieving the internal reinforcement by posts to the residual root that provides retention and adds stability to the prosthesis.

## CONCLUSION

The number of endodontic procedures has increased steadily in the past decades with highly predictable results. Therefore, restoration of teeth

after endodontic treatment is becoming an integral part of the restorative practice in Dentistry. The treatment described in the case reports is simple and effective also represents a promising alternative for rehabilitation of grossly destructed or fractured teeth. This technique of custom made post and core has shown promising results has presented.

#### REFERENCES:

1. J.R. Pereira, *et al.* Influence of intraradicular post and crown ferrule on the fracture strength of endodontically treated teeth. *Braz Dent J*, 2009; 20: 297–302.
2. M. Naumann, S. Kiessling, R. Seemann. Treatment concepts for restoration of endodontically treated teeth: a nationwide survey of dentists in Germany. *J Prosthet Dent*, 2006 Nov; 96: 332–38.
3. A.S. Fernandes, G.S. Dessai. Factors affecting the fracture resistance of post-core reconstructed teeth: a review. *Int J Prosthodont*, 2001 Jul–Aug; 14: 355–63.
4. Brandal JL, Nicholls JI, Harrington GW. A comparison of three restorative techniques for endodontically treated anterior teeth. *J Prosthet Dent*. 1987; 58: 161–5.
5. Chadwick J, Gonzales A, McLean C, Naghavi A, Rosati S, Yau S. Restoration of endodontically treated teeth: An evidence based literature review. University of Toronto, Faculty of Dentistry-Community, Dentistry 2008; 1–21.
6. Fernands AS, Shetty S, Coutinho I. Factors Determining Post selection: A Literature Review. *J Prosthet Dent* 2003; 90: 556-62.
7. Velmurugan N, Parameswaram A. Custom made resin post and core. *Oper Dent* 2004 Jan-Feb; 29: 12-4.
8. Awad MA, Abdulghaffar HS. Custom made Post & core Part I: Technique to fabricate direct custom made post with resin pattern. *J Dent Health Oral Disorder ther*. 2014; 1; 00013.
9. Rosenstiel SF, Land MF, Fujimoto J. Contemporary fixed Prosthodontics. 2006: Ed 4; 340-65.
10. Christensen, G.J.: Posts: Necessary or unnecessary? *J. Am. Dent. Assoc.*, 127: 1522, 1996.
11. Goerig, A.C. and Mueninghoff, L.A. Management of the endodontically treated i. oth. Part I: Concept for restorative designs. *J. Prosthet. Dent.*, 49: 340, 1983.
12. Silvers, I.E. and Johnson, W.T.: Restoration of endodontically treated teeth. *Dent. Clin. North Am.*, 36: 631, 1992.
13. Christensen, G.J. and Christensen, R.P.: Product use survey. *Clinical Research Associates Newsletter*, 1995; 19: 3,
14. Guttman, J.L.: The dentin-root complex: Anatomic and biologic considerations In restoring endodontically treated teeth. *J. Prosthet. Dent*. 1992; 67: 458.