

GINGIVAL RETRACTION USING BLOTTING ROLL METHOD: A PEDO FRIENDLY APPROACH

Pradeep Kumar Rastogi¹, Himanshu Aeran^{2,*}, Keerti Chandail³, Satyam Dutt Sharma⁴

¹Professor & Head, ^{3,4}Post Graduate Student, Dept. of Pedodontics & Preventive Dentistry,
²Director Principal, Professor, Dept. of Prosthodontics, Seema Dental College & Hospital, Rishikesh

***Corresponding Author:**

E-mail: drhimanu@yahoo.com

ABSTRACT

Oral cavity of a child is not an easy area to treat. Constraints of cheek, lip and tongue and the presence of saliva along with limited mouth opening pose challenges to visualize, gain access and manipulate instruments and materials in the oral cavity. The position of teeth in relation to gingival tissues which bleeds profusely if improperly managed complicates the problem. Gingival management and displacement is of utmost importance for obtaining accurate impression for fabrication of prosthesis with adequate marginal fit and emergence profile¹. Methods of gingival retraction can be broadly classified into surgical and non-surgical. Amongst all methods "mechanical-chemical method" is most popular in clinical practice. This clinical method has some limitations. To overcome these limitations, a Pedo friendly method named "Blotting Roll Method" has been developed. It is a modified form of mechanical-chemical method. Here blotting paper rolls are used for gingival retraction and placed over tooth preparation, which on removal results in a dry and clean sulcus.

Keywords: *Gingival retraction, Blotting paper roll, Impressions*

INTRODUCTION

A common objective of impression making for interim crowns or fixed dental prostheses is to register the prepared abutments and finish lines accurately. For all impression procedures, the gingival tissue must be displaced to allow the sub gingival finish lines to be registered. Retraction is the temporary displacement of the gingival tissue away from the prepared teeth.² The aim of gingival retraction is to a traumatically allow access for the impression material beyond the abutment margin and to create space in order to provide sufficient thickness of impression material in gingival sulcus region so that it can better withstand the tearing forces encountered during removal of impressions. The fiber-rich, highly organized periodontal complex surrounding natural teeth provides support for gingival tissues when they are retracted, mitigating the collapse of the tissues when the retraction agents are removed before making the impression⁵. These measures are accomplished by one or more of three techniques: mechanical, chemicochemical and surgical. The surgical techniques can be further broken down into rotary curettage and electrosurgery.¹ The most commonly used method is the mechano-chemical one. The three criteria for a gingival retraction material are: 1) effectiveness in gingival displacement and hemostasis, 2) Absence of irreversible damage to the gingiva, and (3) paucity of untoward systemic effects.¹ Use of the mechanochemical method leads to violation of biological width, causing bone loss and recession. Studies on the chemicochemical and purely mechanical cord retraction techniques have shown various degrees of necrosis and/or stripping of the

gingival sulcus. Gingival electro surgery for crevicular toughing involves a considerable risk of producing permanent periodontal damage.³ None of the above mentioned methods fulfils all the criteria's for an ideal gingival retraction technique, hence a new technique has been developed to help the clinicians to effectively retract the gingival using Blotting Roll method.

Various methods of gingival retraction are:

A) MECHANICAL METHOD

In this method copper bands are used for gingival retraction while making impressions. Copper bands are prepared 2mm wider than mesiodistal width of the tooth. Oversized copper bands are placed over tooth preparation so that margins of tooth preparation get exposed.

To keep copper bands stable over tooth preparation, a resin or compound plug is placed on the top of the band. Copper band is vented or sides for escape of excess impression material, while making impression. A dental floss is threaded through the vent for easy removal of band after complete setting of impression material.

Limitations

1. Excessive pressure should not be exerted during placement of copper band. A little more pressure will cause stripping (or tearing) of gingival tissues.
2. Time consuming method.
3. It retracts only gingival, but does not stop gingival bleeding.
4. A little expensive method.

B) MECHANICAL-CHEMICAL METHOD

This is the most popular and commonly used method for gingival retraction. In this method, a cord impregnated with aluminium chloride is placed into the sulcus, space beneath the margins of tooth preparations with the help of metallic instruments. Aluminium chloride has styptic action, as it stops bleeding. After 5 minutes, the cord is gently removed from sulcus. If re-bleeding occurs, sulcus is repacked for another 5 minutes.

Limitations

1. Technique is difficult and time consuming.
2. Placing cord in maxillary and mandibular 2nd molar region is extremely difficult.
3. Often blood clots are left in the gingival sulcus after removal of cord. Removal of clots often causes re-bleeding.
4. Metallic instruments are used for packing cord into sulcus, more pressure will cause more bleeding and tearing of gingiva.

C) ELECTRO-SURGICAL METHOD

The use of electro surgery has been recommended for enlargement of the gingival sulcus and control of hemorrhage to facilitate impression making. Tooth should be anaesthetized properly before electro-surgery. Different electrodes are used for different tooth. It varies according to the tooth and its position in the arch. Variable tip or straight wires are the most popular electrodes used for surgery.

Electrodes are adjusted to desired sub-gingival depth of tooth and surgery performed by repeated approaches around tooth in segments: 1st lingual, 2nd facial, 3rd mesial and distal.

If bleeding occurs, the coagulation current is used to control it.

Limitations

1. It is a surgical method and highly skilled hands are required
2. Electro-surgery kit is required
3. During surgical process an oral evacuator system is required to control odor
4. Post operative medication required
5. Time consuming method
6. Basically a method for crown lengthening

D) ROTARY CURETTAGE

The concept of using rotary curettage was described by Amsterdam in 1954. Rotary curettage is a "troughing" technique, the purpose of which is to produce limited removal of epithelial tissue in the sulcus while a chamfer finish line is being created in tooth structure. The technique, which also has been called "gingetage" is used with the sub gingival placement of restoration margins. The removal of epithelium from the sulcus by rotary curettage is accomplished with little detectable trauma to soft tissue, although there is a lessened tactile sense for the dentist. Rotary curettage, however, must be done

only on healthy, inflammation-free tissue to avoid the tissue shrinkage that occurs when diseased tissue heals.⁵

Limitations:

1. Cumbersome
2. Difficult to perform in children

BLOTTING ROLL METHOD

To overcome the limitations of all the above mentioned methods, a new pado friendly approach has recently introduced. It is a modified form of the Mechanical-Chemical Method and is named as "Blotting Roll Method".

In this method pre-formed blotting paper rolls are used for gingival retraction in children. Custom made blotting rolls are used. Rolls of different diameters are used for different types of teeth.




Fig. 1: Blotting Paper rolls of different diameters

Incisors-5mm of roll diameter; Premolar-7mm of roll diameter; Molars-9mm of roll diameter

MATERIAL AND METHOD

Blotting paper roll, Metallic rods are used to prepare rolls for premolar and molar teeth. Instead of using metallic rods. "Handle of mouth mirror" (5mm diameter), a pencil (7mm diameter) or a gel pen (9mm diameter) can be used.

METHOD OF PREPARING BLOTTING ROLLS

1. Take a blotting paper of size 10*10 cm.
2. Take a metallic rod of diameter 9mm. (gel pen diameter)
3. Wrap the blotting paper over the rod and fix one end of the paper with rod. Give one rotation after first rotation, coat the blotting paper with glue (or fevicol) and wrap the paper again over the rod. Cut off the remaining blotting paper. Then wrap 3-4 rubber bands over the blotting paper cylinders at interval of 2cm (or wrap a thread over it). After half an hour, slowly remove the rubber bands. This way a cylinder of blotting paper is prepared.

4. Before removing the metallic rod, put marks over blotting cylinder at intervals of about 1cm.
5. Cut the cylinder at the marks with the help of B.P. knife to form 10 rolls. These rolls should be 9mm in diameter and 10mm in length.

CLINICAL PROCEDURE

1. Take a pre-formed roll.
2. Dip one end into aluminium chloride and place it over gingival sulcus of the tooth preparation.
3. Exert a little pressure over the roll with the help of the thumb. Put cotton over the roll and ask the patient to close the mouth. After about 2 minutes, remove the roll to get a dry gingival sulcus.

ADVANTAGES

1. Clinical time saving method
2. No skilled hand required
3. Waiting time is minimum (about 5 mins)
4. Not only stops bleeding from sulcus but also absorbs gingival fluid.
5. After removal, provides a clean and dry sulcus
6. No blood clot formation seen
7. No need to be careful during exerting pressure over blotting rolls while placing into sulcus, because blotting paper cannot cause trauma to gingival tissue, hence no chances of re-bleeding.

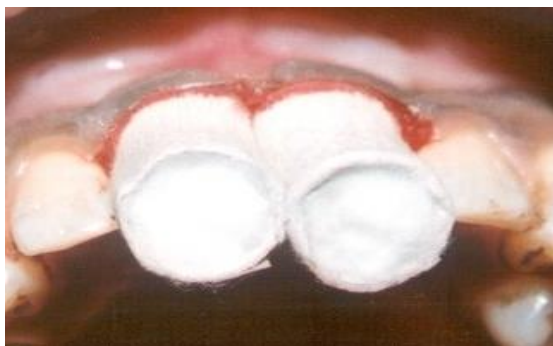

Fig. 2: Placement of blotting paper rolls on anterior central incisors packed with cotton dipped in aluminium chloride

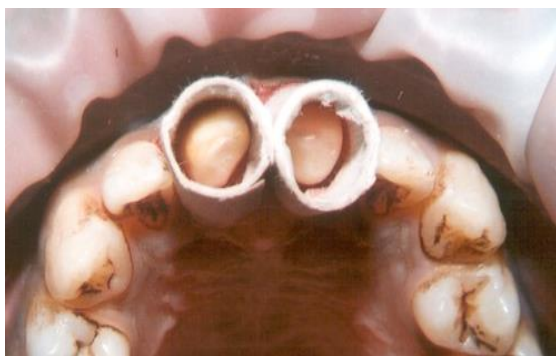

Fig. 3: Top View of anterior teeth with blotting rolls

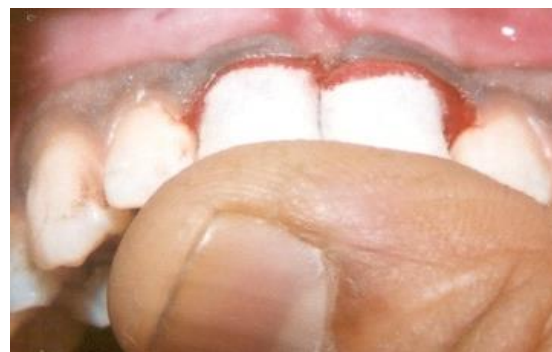

Fig. 4 Retracting gingiva by blotting rolls using Finger pressure

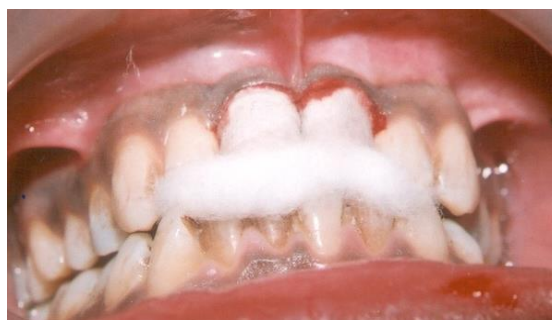

Fig. 5: Patient asked to bite by placing cotton in between the teeth

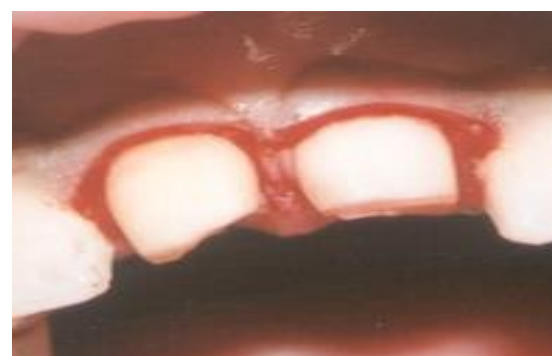

Fig. 6: Central incisors showing retracted gingiva

CONCLUSION

As stated by De Van, constant preservation of what remains is more important than meticulous replacement of what is missing. Respect to the gingiva abutting the tooth and harmony between the restoration and periodontium should be the aim of any dentist. Adequate gingival management in conjunction with an appropriate impression is a must for successful fixed prosthesis. Today a wide array of methods is present to achieve a predictable, safe and efficacious management of gingival tissues. Not much of pertinent literature and scientific evidence is available to establish the superiority of one technique over the other. Selection depends more upon preference of the operator and the given clinical condition.

REFERENCES

1. Madhok S, Rajput G, Singh G. Non-surgical gingival retraction past and current trends. Guident 2014.
2. Prasad DK, Hegde C, Agrawal G et al. Gingival displacement in Prosthodontics: A critical review of existing methods. *J Interdiscip Dentistry* 2011; 1(2):80-6.
3. Phatale S, Marawar P.P, Byakod G et al. Effect of retraction materials on gingival health: A histopathological study. *J Ind Soc Periodontol* 2010; 14(1):35-9.
4. Malone W.F.P , Koth DL, Cavazos Jr. E, Kaiser D.A and Morgano S.M. *Tylman's Theory and Practice of Fixed Prosthodontics*, Eighth edition, All India publishers and Distributors.1997.
5. Shilling burg HT. *Fundamentals of fixed prosthodontics*.3rd ed. Chicago: Quintessence Publishing Co.;1997.
6. Shilling burg HT, Jacobi R, Brackett SE. *Fundamentals of tooth preparations for cast metal and porcelain restorations*. 2nd ed. Quintessence Publishing Co.; 1991.