

## Free gingival graft for increasing the width of attached gingiva– a pilot study

Jose Paul<sup>1,\*</sup>, Johnson Prakash D'Lima<sup>2</sup>, Senny Thomas Parackal<sup>3</sup>, Deepak Thomas<sup>4</sup>, Linta Thomas<sup>5</sup>

<sup>1</sup>Professor & HOD, <sup>2,3</sup>Professor, <sup>4</sup>Senior Lecturer, <sup>5</sup>PG Student, Dept. of Periodontics, Annoor Dental College, Muvattupuzha, Kerala

**\*Corresponding Author:**

Email: drjospol@gmail.com

### Abstract

**Introduction:** The free gingival grafts have been used in periodontics to primarily augment the width of attached gingiva and to a lesser extent cover denuded root surfaces. An adequate width of attached gingiva is essential to maintain oral hygiene, to keep gingiva healthy and free of inflammation.

**Aim:** In this pilot study, 8 cases with 15 sites treated using the free gingival graft technique to increase the width of attached gingiva are evaluated clinically and statistically.

**Materials and Methods:** Graft material was obtained from the palatal donor site. Amount of recession, probing depth, clinical attachment level and width of attached gingiva were measured at baseline, one month and 3 months post operatively.

**Results:** Consistent gain in the width of the attached gingiva was seen in all the cases treated. Though root coverage was not the primary objective a few cases reported root coverage also.

**Conclusion:** The results of the pilot study indicate that free gingival grafting is an excellent technique to increase the width of the attached gingiva and to maintain stable periodontal health. Further long term studies with more subjects and proper standardization techniques are needed to confirm this.

**Keywords:** Free gingival graft, Attached gingiva, Periodontal plastic surgery

### Introduction

The keratinized gingiva extends from the marginal gingiva to the mucogingival junction and include both free and attached gingiva. Keratinized gingival width can normally vary from 1–9 mm. Histologically, the keratinized gingiva, in particular attached gingiva is more adapted to withstand mechanical irritations than non-keratinized mucosa.<sup>(1)</sup> An adequate width of keratinized gingiva is considered important for maintaining gingival health. This concept paved way to the introduction of numerous surgical procedures for increasing the dimension of keratinized tissue.<sup>(2)</sup> Free gingival graft technique is considered to be the technique of choice in adding dimensions to the existing gingiva.

When the patient's plaque control and oral hygiene are compromised and when there is a difficulty in proper brushing of teeth, appropriate plastic surgical techniques can be considered. In patients requiring prosthetic restorations, orthodontic treatment or having an abnormal frenal attachment procedures may be directed at increasing the attached gingiva if there is a deficiency. Pockets extending beyond mucogingival junction may need augmentation of attached gingiva after pocket elimination procedures. The significance of keratinized tissue has gained importance with the increased prevalence of periimplantitis around osseointegrated implants.

### Materials and Method

**Study Design and Patient Selection:** This study was conducted to evaluate the efficacy of free gingival graft for increasing the width of attached gingiva. A total of 8

subjects (2 men and 6 women) with 15 sites with attached gingiva width < 2 mm were selected irrespective of the type of recession. The subjects were selected from among the outpatient department of Annoor Dental College and Hospital, Muvattupuzha. The sites selected were the facial aspect of mandibular anterior region. The patients selected were in the age group of 25-55 years with mean age of 34.5. Phase 1 therapy was carried out in all the cases. The study design involved a screening appointment, followed by initial therapy, surgical therapy, and postoperative evaluation at baseline, 1 and 3 months follow up. All subjects were explained about the study protocol and their informed consent was obtained prior to the initiation of the study.

#### Inclusion criteria

Patients were evaluated for the following criteria:

1. Oral hygiene
2. Facial probing depth less than 2 mm
3. No removable partial denture in the area to be treated.
4. Patients without any systemic diseases or/and on any medication that can affect the periodontium or interfere with healing.
5. Nonsmokers.
6. No history of surgical therapy in the delineated area for atleast 2 years prior to the study.

**Initial therapy and clinical measurements:** Prior to surgical procedure, patients received professional oral prophylaxis, oral hygiene instructions, and occlusal adjustments as per individual requirements.

The clinical parameters assessed were:

- Width of attached gingiva

- Vertical depth of recession
- Probing pocket depth
- Clinical attachment level

A Williams graduated periodontal probe was used for all clinical measurements. Measurements were made to the nearest 0.5mm on the midbuccal aspect of the tooth. Roll technique was used to identify the mucogingival junction. The extent of recession was measured from the cemento-enamel junction to the gingival margin. The distance from the gingival margin to the base of the pocket was calculated as the probing depth, whereas the clinical attachment loss was the distance from the cemento-enamel junction to the base of the pocket.

**Surgical Procedure:** All the surgical procedures were done by one operator and all the patients received a classic free gingival graft technique (Fig. 1).

**Statistical Analysis:** Repeated measure ANOVA was used for the analysis. Means plot were also provided. In all the analysis significance level is taken to be 0.05 (i.e., if the p-value is less than 0.05, reject the null hypothesis or it can be concluded that the null

hypothesis is statistically significant). Statistical analysis was carried out using statistical package, SPSS (version 22.0.0.0).

## Results

All patients tolerated the surgical procedures well, no postoperative complications were experienced, and were compliant with the study protocol. Study teeth were free of visible plaque and gingival inflammation throughout the study. The donor site healed uneventfully in all the cases. The mean value of width of attached gingiva is lowest during baseline and is increasing as time period increases (Fig. 2). Although not the primary objective, there was a significant difference in mean value of recession among baseline and 1 month and among baseline and 3 months period (Fig. 3). There is significant difference in mean value of clinical attachment level ( $F(2, 13) = 12.517$ ,  $p\text{-value} = 0.001$ ) among baseline, 1 month and 3 months (Fig. 4). There is no significant difference in mean value of probing depth ( $F(2, 13) = 2.385$ ,  $p\text{-value} = 0.131$ ) among baseline, 1 month and 3 months period (Fig. 5).

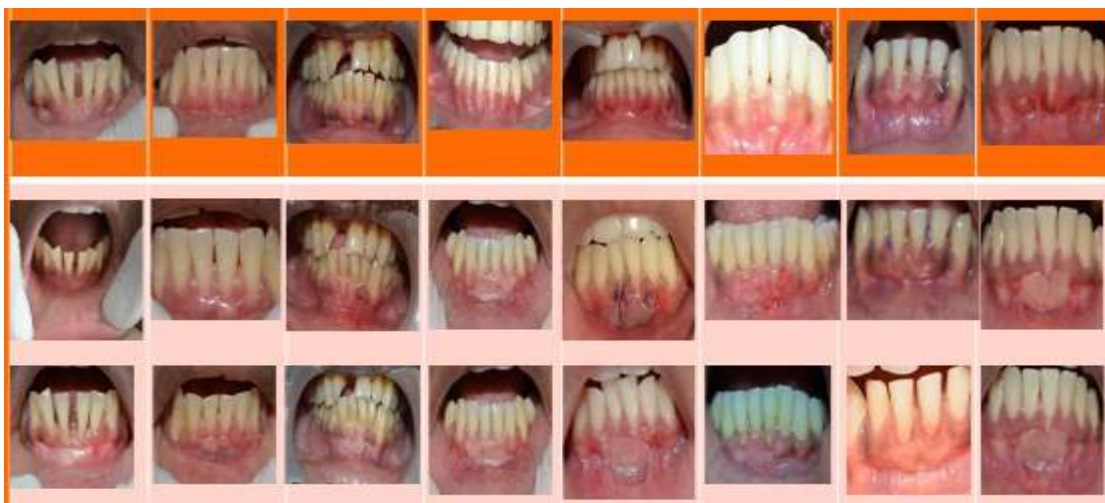

Fig. 1

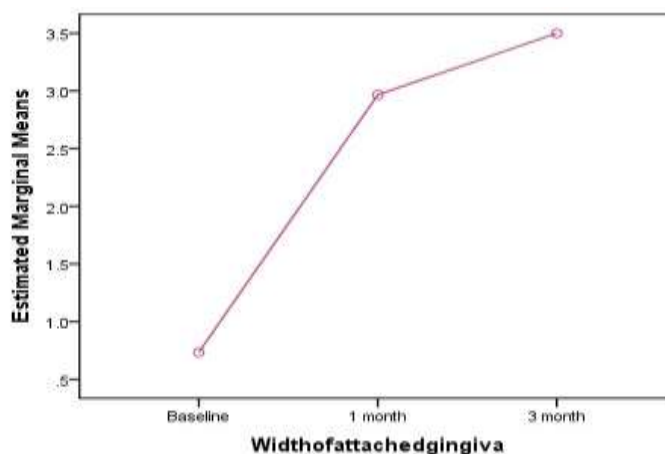


Fig. 2: Mean plots for width of attached gingiva

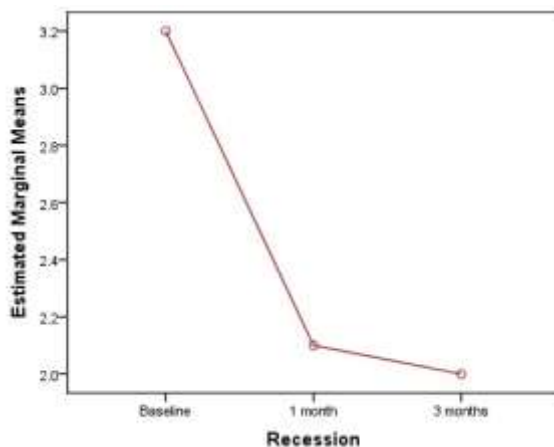


Fig. 3: Mean plots for recession

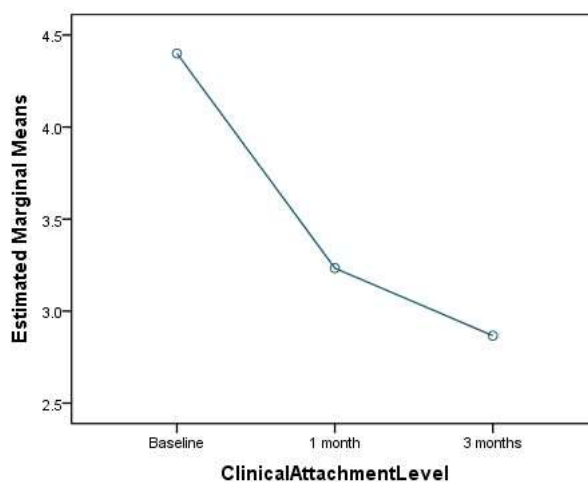


Fig. 4: Mean plot for CAL

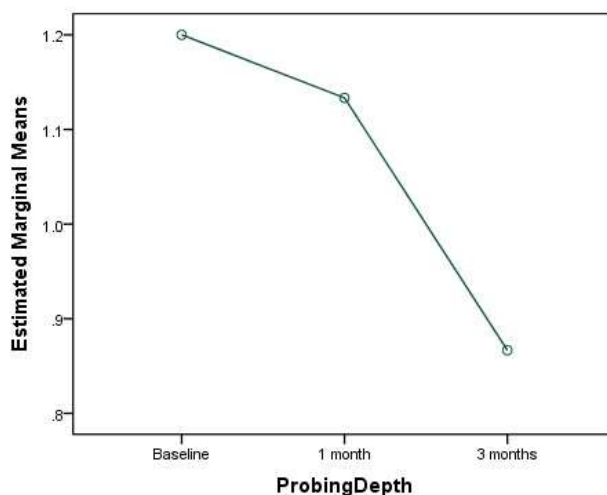


Fig. 5: Mean Plot for probing depth

**Discussion**

The role of the width of attached gingiva and the optimum dimension that is to be maintained for oral health is a topic of controversy. Various schools of

thoughts and opinions prevails regarding this. Free gingival graft was considered as a classic technique for increasing the width of attached gingiva and the results of this pilot study confirms the same. In our study, a

significant increase in the width of attached gingiva was obtained utilizing free gingival grafts. This result is in accordance with the results obtained by Dorfman et al. in 1980.<sup>(4)</sup> Root coverage was also obtained in some cases, although it was not the primary objective.

By the mid of the 19<sup>th</sup> century, an adequate zone of gingiva was considered critical for the maintenance of marginal tissue health and in the prevention of clinical attachment loss.<sup>(5,6)</sup> The concept gained much acceptance as this band of firm gingiva protects the underlying periodontium from injury caused by frictional forces during mastication. It also resulted in dissipation of the pull on the gingival margin created by the muscles of the adjacent alveolar mucosa. Regions with inadequate zone of attached gingiva resulted in subgingival plaque deposition which culminated in loss of attachment. Ineffective oral hygiene measures and the prevalence of food impaction were found to be significantly increased in regions with inadequate attached gingiva.<sup>(5,7)</sup> Literature give evidence<sup>(2)</sup> that when there is less than 1mm of attached gingival tissue, inflammation persists eventhough dental plaque is not detected clinically. This inflammation was unrelated to any muscle pull from frenal attachments. It is considered that 2mm was the minimum requirement for maintaining good gingival health.

Contrasting opinions were reported by different researchers regarding the minimum dimension of attached gingiva necessary. A few suggested that less than 1 mm of gingiva may be sufficient,<sup>(8)</sup> while others claimed that the apicocoronal height of keratinized tissue ought to exceed 3 mm.<sup>(9)</sup> A third school of thought opines that, any dimension of gingiva which is compatible with gingival health and prevents retraction of the gingival margin during movements of the alveolar mucosa may be considered as the minimal requirement.<sup>(10)</sup>

Later studies suggested that with maintenance of good oral hygiene and absence of microbial plaque, gingival health is possible in areas with minimal or no attached gingiva.<sup>(11,12)</sup> Some studies suggested that, if oral hygiene is maintained well, the amount of keratinized gingiva is not significant in relation to the health or function of teeth or implants.<sup>(13)</sup>

When considering the need of keratinized tissue around implants, some authors strongly believe that keratinized mucosa has better functional and esthetic results for implant restorations.<sup>(14)</sup> They concluded that keratinized mucosa is particularly thicker and denser than alveolar mucosa which is non-keratinized. This also forms a strong seal around implant, abutment, or restoration that is resistant to retracting with masticatory forces and oral hygiene procedures. Implants with coated surfaces demonstrate greater periimplant bone loss and failures in the absence of keratinized mucosa.<sup>(14)</sup> Inadequate keratinized mucosa around implant supported overdentures reported with

higher plaque accumulation, gingival inflammation, bleeding on probing and mucosal recession.<sup>(15)</sup>

A recent systematic review and metaanalysis on long term effects of untreated buccal gingival recession showed that even after maintaining good oral hygiene they had a high probability of progression during the two year follow up.<sup>(16)</sup>

## Conclusion

Even though some histological studies suggests that areas with narrow bands of gingiva possess the same resistance to continuous attachment loss as teeth with wide zones of gingiva, an adequate band of attached gingiva is required to maintain gingival health clinically. The clinical results of this pilot study indicate that free gingival grafting is an excellent method to increase the width of the attached gingiva and to maintain a stable periodontal health. Further long term studies with more subjects and proper standardization techniques are needed to confirm this.

**Conflicts of Interest/ Disclaimer:** None

**Budgeting and Funding:** No external source of funding was available for the study.

## Reference

1. Lozdan J, Squier CA. The histology of the mucogingival junction. *J Periodontal Res* 1969;4(2):83-93.
2. Lang NP, Löe H. The relationship between the width of keratinized gingiva and gingival health. *Journal of periodontology*. 1972 Oct;43(10):623-7.
3. Snyder AJ. A technic for free autogenous gingival grafts. *Journal of periodontology*. 1969 Dec;40(12):702-6.
4. Dorfman HS, Kennedy JE, Bird WC. Longitudinal evaluation of free autogenous gingival grafts. *Journal of clinical periodontology*. 1980 Aug 1;7(4):316-24.
5. Ochsenbein C. Newer concepts of mucogingival surgery. *Journal of periodontology*. 1960 Jul;31(3):175-85.
6. Matter J. Free gingival grafts for the treatment of gingival recession. *Journal of clinical periodontology*. 1982 Apr 1;9(2):103-14.
7. Friedman N. Mucogingival surgery. *Texas Dental Journal* 1957; 75: 358-62.
8. Bowers GM. A study of the width of attached gingiva. *Journal of Periodontology*. 1963 May;34(3):201-9.
9. Corn H. Periosteal separation—its clinical significance. *Journal of Periodontology*. 1962 Apr;33(2):140-53.
10. Trey E, Bernimoulin JP. Influence of free gingival grafts on the health of the marginal gingiva. *Journal of clinical periodontology*. 1980 Oct 1;7(5):381-93.
11. Miyasato M, Crigger M, Egelberg J. Gingival condition in areas of minimal and appreciable width of keratinized gingival. *Journal of Clinical Periodontology*. 1977 Sep 1;4(3):200-9.
12. Grevers A. Width of attached gingiva and vestibular depth in relation to gingival health. University of Amsterdam; 1977.
13. Wennström JL, Bengazi F, Lekholm U. The influence of the masticatory mucosa on the peri-implant soft tissue condition. *Clinical oral implants research*. 1994 Mar 1;5(1):1-8.

14. Beumer J, Roumanas E, Nishimura R. Advances in osseointegrated implants for dental and facial rehabilitation following major head and neck surgery. In *Seminars in Surgical Oncology* 1995 May 1 (Vol. 11, No. 3, pp. 200-207). John Wiley & Sons, Inc.
15. Adibrad M, Shahabuei M, Sahabi M. Significance of the width of keratinized mucosa on the health status of the supporting tissue around implants supporting overdentures. *Journal of Oral Implantology*. 2009 Oct;35(5):232-7.
16. Chambrone L, Tatakis DN. Long-Term Outcomes of Untreated Buccal Gingival Recessions: A Systematic Review and Meta-Analysis. *Journal of periodontology*. 2016 Jul;87(7):796-808.