

“Keep My Space”- A Review Article

Puja Khanna^{1*}, Sangeeta Sunda², Sunny Mittal³

¹Professor, ^{2,3}Senior Lecturer, JCD Dental College, Sirsa

***Corresponding Author:**

Email: mail@pujakhanna.com

Abstract:

Premature loss of primary teeth can result in the loss of arch length leading to malocclusion. Early interception and prevention of malocclusion in deciduous and early mixed dentition prevents the development of pronounced anomalies in the late mixed dentition and permanent dentition, thereby, reducing or eliminating the need for later comprehensive orthodontic treatment. Space maintenance forms an integral part of preventive and interceptive orthodontics. This article has reviewed and summarized some of the variables to be considered when effecting space control, the factors that dictate appliance selection, the indications and use of space maintainers in primary and mixed dentitions.

Keywords: Space maintainers, Interceptive orthodontics, Lingual arch, Premature loss

Introduction:

Primary teeth play a critical role in the growth and development of a child. In addition to their role in esthetics, eating, speech, encouraging normal growth and function, the other main function is to hold space for the permanent successor until it is ready to erupt.¹ Crowding and lack of space in the permanent dentition are amongst the most common orthodontic problems encountered in patients. Often the etiology of these problems is linked to premature loss of one or more deciduous teeth with corresponding loss of space.³ The pattern of space loss depends on many factors including age, stage of development, which teeth have been lost, the presence of crowding or spacing, and occlusal relationships.⁴ Space maintainers are appliances used to maintain space or regain minor amounts of space lost, so as to guide the unerupted tooth into the proper position in the arch. After the premature loss of a tooth, not only do space maintainers maintain function and preserve arch length, they also maintain esthetics, prevent encouragement of detrimental habits and eliminate any potential psychological damage, a child could face as a result of the premature loss of teeth. The space maintainer also allows the permanent tooth to erupt unhindered into proper alignment and occlusion.² The use of space maintainer appliance, or restoration of a carious primary tooth that can then act as a natural space maintainer, may potentially obviate the consequences of loss of arch length and the need for complex orthodontic treatment at a later stage.⁵

Careful consideration of many factors is required when deciding whether space maintenance is indicated. Radiographs and space analysis can be very helpful.⁴ This article has reviewed and summarized some of the variables to be considered when effecting space control, the factors that dictate appliance selection, the indications and use of space

maintainers in primary and mixed dentitions, and discussed the appliances commonly used for space maintenance.^{6,7,8}

Space maintainers are broadly classified as:

- Removable, fixed or semi-fixed
- Functional vs non-functional
- Active vs passive
- Unilateral vs Bilateral
- Combination of above

Indications:

- 1) To prevent drifting, tipping of teeth and to maintain the space
- 2) Prevent loss of arch length
- 3) Prevent midline shifts because of unilateral loss of deciduous tooth/teeth
- 4) Restore function
- 5) Esthetics
- 6) Psychological reasons
- 7) To prevent ectopic eruption

Requisites of space maintainer

- 1) Should maintain mesio-distal width of tooth
- 2) Simple, easy to fabricate and cost effective
- 3) Should restore function and prevent over eruption of opposing teeth
- 4) Should be strong enough to withstand the functional forces
- 5) It must permit maintenance of oral hygiene
- 6) It must not restrict normal growth and development which take place during the transition from deciduous to permanent dentition

Case selection⁹

- 1) Early exfoliation of 2nd primary molar.
- 2) In case of congenitally missing 2nd premolar, it is better to let the permanent molar drift forward naturally and fill the space.

- 3) In case of congenitally missing maxillary lateral incisor, it is better that cuspid naturally drifts.
- 4) Delayed eruption of permanent anterior teeth, leads to loss of arch continuity and patient tends to develop tongue thrust habit. A defect in speech may accentuate and make the child handicap psychologically.
- 5) In case of missing 1st permanent molar or extracted 1st molar, let the 2nd molar move forward and erupt into normal occlusion or hold the space open for a permanent bridge.

Contraindications for space maintainers:¹⁰

- 1) When the mesiodistal width of the underlying permanent tooth is less than the space present.
- 2) When the tooth is near to the crest of the ridge.
- 3) When the underlying permanent tooth is missing
- 4) When the molars are expected to drift forward.

Planning for Space Maintenance

The following considerations are important when space maintenance is considered after the untimely loss of primary teeth:¹¹

1. **Time elapsed since loss-** if space closure occurs, it usually takes place during the first 6 months after the extraction. When a primary tooth is removed & all factors indicate the need for space maintenance, it is best to insert an appliance as soon as possible after the extraction. Often the best approach, if possible, is to fabricate an appliance before the extraction & deliver it at the extraction appointment.
2. **Dental age of the patient-** the chronologic age of the patient is not so important as the developmental age. Grown studied the emergence of permanent teeth based on the amount of root development as viewed on radiographs, at the time of emergence. He found that teeth erupt when three-fourths of the root is developed, regardless of the child's chronologic age.
3. **Amount of bone covering the unerupted tooth** - if there is bone covering the crown, it can be readily predicted that eruption will not occur for many months, a space-maintaining appliance is indicated.
4. **Sequence of eruption of teeth-** the dentist should observe the relationship of developing & erupting teeth adjacent to the space created by the untimely loss of a tooth.
5. **Delayed eruption of the permanent tooth-** in case of impacted permanent tooth, it is necessary to extract the primary tooth, construct a space maintainer & allow the permanent tooth to erupt at its normal position. If the permanent teeth in the same area of the opposing dentition have erupted, it is advisable to incorporate an occlusal

stop in the appliance to prevent supra-eruption in the opposing arch.

6. **Congenital absence of the permanent tooth-** if permanent teeth are congenitally absent, the dentist must decide whether it is wise to hold the space for many years until a fixed replacement can be provided or it is better to allow the space to close. If the decision is made to allow the space to close, there will rarely if ever be bodily movement of the teeth adjacent to the space. Therefore, orthodontic treatment will be needed to guide the teeth into a desirable position.
7. **Presentation of problems to parents** - Explain existing conditions & discuss the possibility of the development of a future malocclusion if steps are not taken to maintain the space or to guide the development of the occlusion. Also explain that the space-maintaining appliance will not correct an existing malocclusion but will only prevent an undesirable condition from becoming worse or more complicated.¹¹

Commonly used space maintainers:

1. **Simple acrylic plate:**¹⁰ non-functional space maintainer
2. **Removable partial denture/ Functional space maintainer (fig. 1).** It helps in mastication in the posterior region, improves esthetics in the anterior region, prevent abnormal speech and tongue habits.¹¹

The removable unilateral space maintainers should not be used, although it is technically feasible to use them. They are too small and present swallowing and choking dangers for children.¹² The biggest problem is that children in the primary dentition age group are very unreliable when it comes to taking care of removable appliances, and the appliances are apt to become lost or damaged.

In the mandibular removable functional bilateral space maintainer, the wire attachments can be designed for the purpose of improved appliance retention (fig.2). A maxillary removable functional, bilateral space maintainer is not commonly used because of problems with the appliance not being worn and the frequent incidence of breakage and loss (fig. 3).




Fig.1

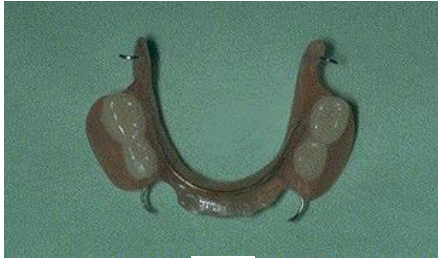

Fig. 2



Fig. 3

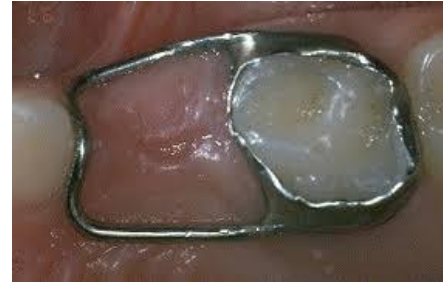

Fig. 4

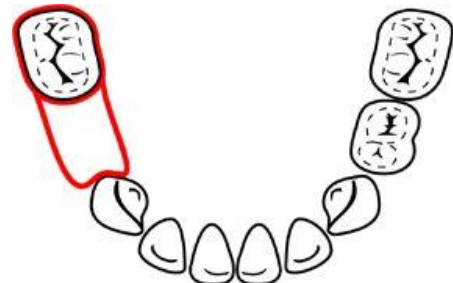


FIG. 5

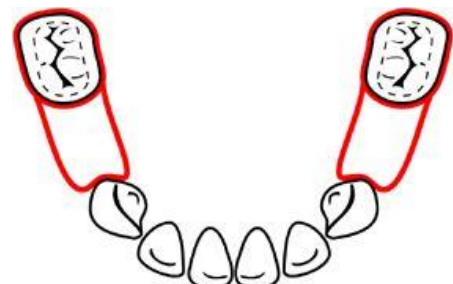


FIG. 6

Advantages of removable space maintainers:

- Functional in true sense as it replaces the missing teeth.
- Permits the teeth to be cleaned
- Maintains or restores vertical dimension
- Esthetically desirable
- Facilitates chewing and speaking
- Helps in keeping the tongue in its boundary.
- Stimulates the eruption of permanent teeth.
- Easy to fabricate and requires less chair side time.

Disadvantages of removable space maintainers:

- Patient compliance is necessary and mandatory
- Appliance may be lost or broken
- It restricts the lateral growth of the jaw if clasps are incorporated.
- It may irritate the soft tissue.

1) **Band and loop space maintainer (Fig. 4):** The band and loop space maintainer is indicated for the premature loss of single, unilateral or bilateral maxillary or mandibular deciduous molars. It adjusts easily to accommodate changing dentition. FIG 5 and 6 shows the indications for band and loop appliance. Space maintenance is necessary to hold the second primary molars in position, especially as the first permanent molars erupt and create forces which otherwise would move the primary molars forward. Bilateral band and loop space maintainers can be used in such a situation.

2) **Band and loop space maintainer with occlusal rest Fig 7:** it is a modified band and loop space maintainer. A small occlusal rest is designed on the loop wire. This is placed to prevent the mandibular right first permanent molar from tipping and causing the wire to imbed apically in the tissue distal to the first primary molar. Thus, the occlusal rest helps prevent the tipping motion of the first permanent molar.

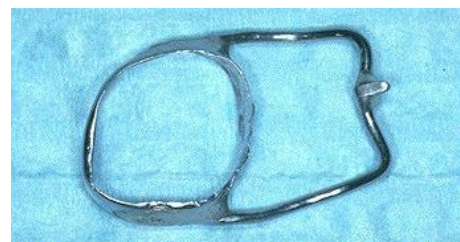


Fig 7

3) **Stainless steel crown space maintainer**

These crowns are used to restore carious primary molars where one or two surface carious lesions are extensive and if restoration is needed to last more than two years. These crowns are also

indicated in restoration of fractured primary molars and in localized or generalized developmental problems e.g., enamel hypoplasia, amelogenesis imperfecta, and dentinogenesis imperfecta. In children, less than six years of age, stainless steel crowns are preferable to restorations. A stainless steel wire can be soldered to the crown and it can be used as a crown and loop space maintainer.

- 4) **Distal shoe space maintainer or Cantilever type (Fig. 8):** Roche advocated the Crown and band appliance with a distal intragingival extension. It is used to maintain space or influence the active eruption of first permanent molar in distal direction. Before final placement of the space maintainer in the mouth, the radiograph of the appliance should be made to determine whether the tissue extension is in the proper relationship with the unerupted first permanent molar. Final adjustment in length and contour of the shoe may be made at that time. The soft tissue has been observed to tolerate the extension of this type of appliance well, although a small metallic tattoo in the gingiva may result. The depth of the intragingival extension should be about 1-1.5 mm below the mesial marginal ridge of the molar, or just sufficient to capture its mesial surface as the tooth erupts and moves forward. After the molar has erupted, the intragingival extension is removed. If the appliance is to be used as a reverse band and loop space maintainer, it may be necessary to add a supra gingival extension to prevent the molar from tipping over the wire.

Contraindications of distal shoe space maintainer are as:

- If several teeth are missing
- Certain medical conditions such as blood dyscrasias, immune-suppression, congenital heart disease, history of rheumatic fever, diabetes, generalized debilitation.

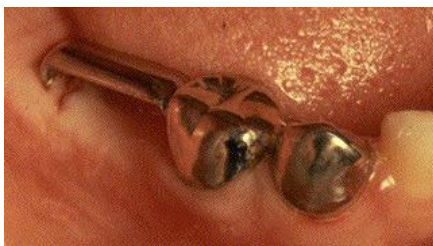

Fig. 8

- 5) **Fixed lingual arch:** It is indicated in bilateral loss of the deciduous posterior teeth, in mandibular arch, especially if the permanent mandibular incisors exhibit crowding.¹¹

- 6) **Semi-fixed removable type of lingual arch (Fig. 9):** In this type of space maintainer, the distal end of the lingual arch is placed in lingual sheath present on the molar band and it is tied with ligature. Advantage of this type of space maintainer is the ease of adjustment of the appliance intra-orally.

7)

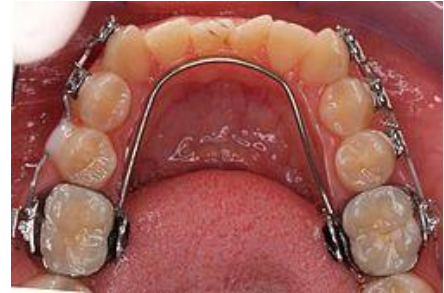

Fig. 9

- 8) **Pin and tube space maintainer:** It is used in cases where there is early loss of primary incisors. Pin is allowed to slide partially out of the tube in response to the lateral growth of the arch.¹⁰
- 9) **Nance arch holding appliance (Fig. 10):** Shows a maxillary fixed bilateral space maintainer. It is similar to fixed lingual arch appliance except that it is used in the upper arch and there is an acrylic button in the rugae region.¹⁰ It is used in situations where premature bilateral loss of maxillary primary teeth is present or when leeway space must be preserved.^{11,12}

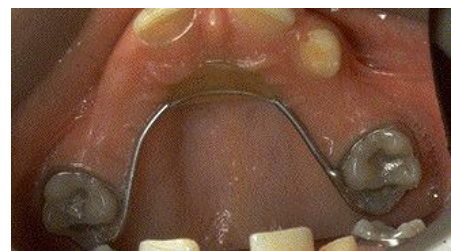

Fig. 10

- 10) **Gerber space maintainer (Fig. 11):** The kit is used for space maintenance or space regaining. In case of space regaining, a compressed coil spring or open coil spring is introduced between the tube and the wire. Once the space is regained, the assembly is left behind as the space maintainer.¹⁰

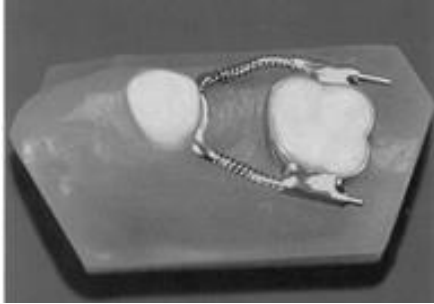


Fig. 11

11) EZ space maintainer (Fig 12): EZ Space Maintainer (Ortho Technology Inc.) is a cost-effective, less time-consuming appliance than traditional space maintainers. It requires no impressions, no laboratory construction, and can be directly bonded during one in-office visit. It is more aesthetic, hygienic, simple and easy to use. It provides easy maintenance of the mesio-distal dimension of any lost, deciduous teeth and can be used as an adjustable appliance by using the NiTi coil included to regain some space.

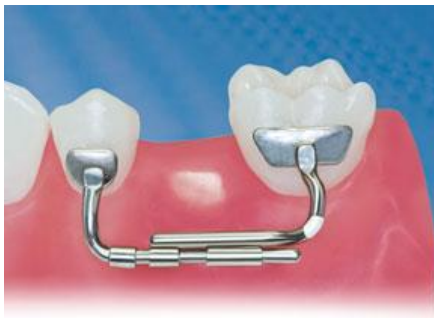

Fig. 12

Benefits and Harms

The potential benefits of using space maintaining appliances include reduced prevalence or severity of: crowding, ectopic eruption, tooth impaction, Angle's class II or III occlusion, crossbite, excessive overbite and overjet or midline shift. Other advantages include the potential for considerable cost savings by reducing the need for future orthodontic treatment¹. The potential disadvantages of using space maintaining appliances include soft tissue impingement, interference with eruption of adjacent teeth, pain, plaque accumulation, caries, and broken, dislodged or lost appliances.¹³ Frequent follow-ups to check for any problems following space maintainer insertion is recommended.⁴

Ongoing Monitoring and Evaluation Of In Place Space Maintainers

The intra-oral radiographs should be taken at appropriate intervals to evaluate the eruption status of the permanent tooth/teeth for which a space

maintainer has been placed. When the tooth is visible or erupting between the wires of loop, it is time to remove the maintainer (Fig 13). Also, if one of the deciduous teeth supporting the appliance sheds, the space maintainer should be removed.

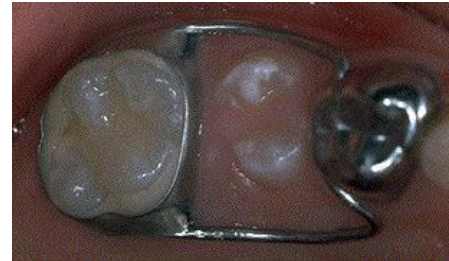

Fig 13

Conclusion:

The best space maintainer is a well maintained primary tooth. But when these important natural space maintainers are lost, it is essential to implement a space management strategy. Appropriate space management therapy can save a child from esthetic and functional disfigurement and save a family from lot of financial expenditure in later orthodontic treatment costs. The dentist must review the variables and re-evaluate his decisions according to the dynamic development of the patient's dentition and plan accordingly.

References:

1. Peter Schopf. Indication for and Frequency of Early Orthodontic Therapy or Interceptive Measures. *Journal of Orofacial Orthopedics*. March 2003, Volume 64, Issue 3, pp 186-200.
2. Bijoor RR, Kohli K: Contemporary space maintenance for the pediatric patient. *The New York State Dental Journal* [2005, 71(2):32-35]
3. Choonara SA. Orthodontic space maintenance--a review of current concepts and methods. *SADJ*. 2005 Apr;60(3):113, 115-7.
4. Durward CS. Space maintenance in the primary and mixed dentition. *Annals of the Royal Australasian College of Dental Surgeons* [2000, 15:203-205]
5. Laing E, Ashley P, Naini FB, Gill DS. Space maintenance. *Int J Paediatr Dent*. 2009 May;19(3):155-62.
6. Simon T, Nwabueze I, Oueis H, Stenger J. Space maintenance in the primary and mixed dentitions. *J Mich Dent Assoc*. 2012 Jan;94(1):38-40.
7. Law CS. Management of premature primary tooth loss in the child patient. *J Calif Dent Assoc*. 2013 Aug;41(8):612-8.
8. Wright GZ, Kennedy DB. Space control in the primary and mixed dentitions. *Dental Clinics of North America* [1978, 22(4):579-601]
9. Sidney B. Finn. *Clinical pedodontics*-4th edition.
10. Rani M.S. *Textbook of orthodontics*. Revised 3rd edition.
11. Mcdonald, Avery & Dean. *Dentistry for the child & adolescent*. 8th edition.
12. Peterson and Davis. *Atlas of Pediatric dentistry*.
13. Brothwell DJ. Guidelines on the use of space maintainers following premature loss of primary teeth. *J Can Dent Assoc*. 1997 Nov;63(10):753, 757-60, 764-6.