

Juvenile ossifying fibroma WHO Type: A diagnostic quandary

Ashwini Nerkar^{1,*}, Rajeev Gadgil², Ajay Bhoosreddy³, Chetan Bhadge⁴, Gaurav Verma⁵

^{1,5}PG Student, ²Professor, ³Professor & HOD, ⁴Reader, MGV's KBH Dental College & Hospital,

***Corresponding Author:**

Email: dr.ashwini.nerkar@gmail.com

Abstract

Juvenile ossifying fibroma is an uncommon clinical entity. It's aggressive local behaviour and high recurrence rate (30-58%) means, that it is important to make an early diagnosis, execute the appropriate treatment and follow up the patient over a long period of time. In the current article, we report a case of juvenile ossifying fibroma-WHO type in a 11yr old girl, which was asymptomatic in nature. It was at an unusual location, involving premolar and molar region of left mandible and as a result was clinically and histo pathologically challenging. An incisional biopsy was performed giving diagnosis as central ossifying fibroma. Surgically, a more conservative procedure of enucleation was performed as the treatment of this tumour and the diagnosis was reconfirmed. Postoperatively, follow up of 6months have shown no evidence of recurrence till now.

Keywords: Juvenile ossifying fibroma; Fibro-osseous lesions; Ossifying fibroma

Introduction

The term Juvenile ossifying fibroma (JOF) is used for a rare actively growing lesion that mainly affects individual's younger than 15 years of the age.⁽¹⁾ This lesion behaves in an aggressive fashion, reaching massive proportions with extensive cortical expansion. Lesions with this morphology have been variously described as juvenile ossifying fibroma,⁽²⁾ active juvenile ossifying fibroma,⁽³⁾ aggressive ossifying fibroma,⁽⁴⁾ reticular desmo-osteoblastoma⁽⁵⁾ or active fibrous dysplasia.⁽⁶⁾ This lesion most commonly involves the paranasal sinuses, periorbital bones, fronto ethmoidal bone and maxilla.⁽⁷⁾ Lesion in the mandible is very rare.- This rare tumor behaves in a more aggressive fashion than does ossifying fibroma, may be mistaken as low grade osteosarcoma, which may alter the treatment.

Juvenile ossifying fibroma is a well-defined clinical and histological entity. It is described in WHO classification as "an actively growing lesion consists of a cell rich fibrous stroma, containing bands of cellular osteoid without osteoblastic rimming together with trabeculae of more typical woven bone. Small foci of giant cells may also be present, and in some parts there may be abundant osteoclasts related to woven bone. Usually no fibrous capsule can be demonstrated. But like the ossifying fibroma (and unlike fibrous dysplasia), the JOF is well demarcated from the surrounding bone".⁽¹⁾

In the jaw, JOF is considered to develop from undifferentiated cells of the periodontal ligament, usually in the premolar and molar region. The differential diagnosis list for JOF can include central ossifying fibroma, cemento- ossifying fibroma, central osteoma, ameloblastic fibroma, ameloblastoma, odontogenic cyst, vascular lesions and giant cell lesions.

Case Report

A 11years old girl reported to our department of Oral Medicine and Radiology with a chief complaint of painless swelling in the lower jaw since 1 year, which was progressive in nature. Extra oral clinical examination revealed, facial asymmetry towards the left side associated with fullness in the lower third of the face(Fig.), measuring approximately size of 10mm x 8mm. Overlying skin was normal and not attached to the underlying tissue. No lymphadenopathy was detected. Intraorally, a diffuse expansile lesion involving the left mandibular posterior region, measuring approximately 15mm x 10mm was extending from the distal aspect of 32 to the distal aspect of 75 with partial obliteration of the buccal vestibule (Fig.) and with normal overlying mucosa. The swelling was non tender and bony hard in consistency. Patient experienced elicited and intermittent paraesthesia in left posterior mandibular region. Teeth present in the area of interest were 32, 73, 74, 75 and 46. Based on the history and clinical examination, a provisional diagnosis of a benign odontogenic or non-odontogenic lesion affecting the left mandible was given. Patient was advised for incisional biopsy followed by complete blood picture. Due to financial inconvenience, Patient couldn't to any of the above.



Fig. 1a: Extra Oral View

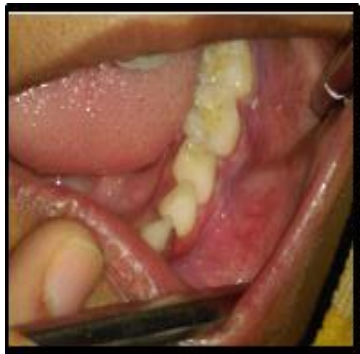

Fig. 1b: Intraoral view

Post three months to the first visit, patient reported to the department with complaint of painless swelling in the same region that was progressed aggressively to an enlarged size. Extra oral clinical examination revealed marked facial asymmetry towards the left side of lower third of the face (Fig.), measuring approximately size of 15mmx 10mm. Overlying skin was normal and not attached to the underlying tissue. No lymphadenopathy was detected. Intraorally, a diffuse expansile lesion involving the left mandibular posterior region, measuring approximately 20mm x 15mm was extending from the distal aspect of 32 to the distal aspect of 75 with complete obliteration of the buccal vestibule (Fig.) and with normal overlying mucosa. The swelling was non tender and bony hard in consistency. Patient experienced spontaneous paraesthesia in left posterior mandibular region. Teeth present in the area of interest were 32, 73, 74, 75 and 46 showed grade 1 mobility. Based on the history and clinical examination, a provisional diagnosis of a benign odontogenic or non-odontogenic lesion affecting the left mandible was given. The radiographic investigations advised included intraoral periapical radiograph, mandibular occlusal view, panoramic radiograph and CBCT followed by complete blood picture. Periapical radiograph revealed a patchy radiopacity with a background of diffused radiolucency in the region of 32, 73, 74 and 75 along with multiple flecks of fine calcifications with loss of lamina dura, displacement and resorption with the root apex of 74 and 75.(Fig.) Expansion of buccal

and lingual cortical plates could be appreciated in the occusal view. Panoramic view revealed mixed radiolucent and radiopaque lesion extending from 32 to 75 with inferior displacement of inferior alveolar canal, thinning of inferior border of mandibular cortex, giving it a bowing down of appearance. CBCT sections showed mixed radiopaque radiolucent (predominately radiopaque) lesion, with well-defined borders ,extending from 32 till distal end of 75 (Fig.) measuring anteroposteriorly 23.01mm, superoinferiorly 17.31 mm in dimension. Teeth buds of 33, 34 and 35 could be seen in close proximity with that of inferior border of mandible. Thinning of both the cortical plates could be appreciated. Expansion of the lesion was massive at buccal aspect as compared to lingual. Laboratory findings ruled out any abnormality related to parathyroid gland and remaining blood picture was within normal limits. With a clearer picture on the extent of the lesion, we took the next step towards the management.



Fig. 2a: Extraoral View

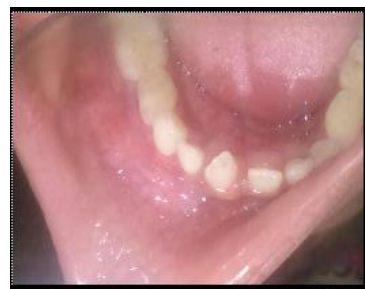

Fig. 2b: Intraoral view

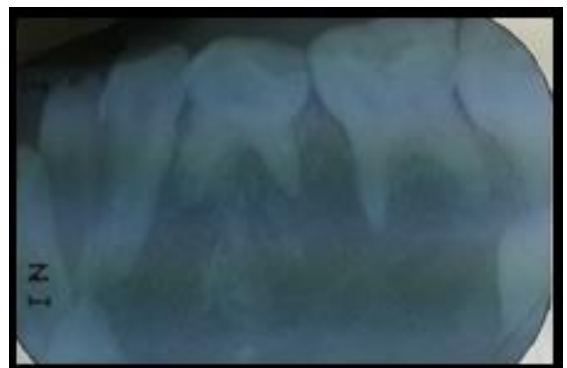


Fig. 3a: Intraoral Periapical Radiograph

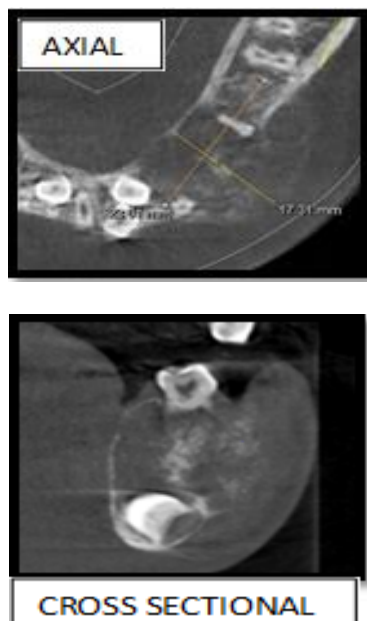


Fig. 3b: CBCT Views

Incisional biopsy was done, through which central ossifying fibroma, as the histopathological diagnosis was arrived. Biopsy followed by surgical enucleation of the left posterior mandible was done under general anaesthesia. Histological examination of hematoxylin and eosin stained slides (Fig. 4a) demonstrated a bony trabeculae of varying size in fibrocellular stroma. Trabeculae consist of lamellar and predominantly woven bone with osteoblastic rimming and few osteoid rims. Acellular to poorly cellular mineralized cementum like spheroids were also seen in plenty. Large areas of irregular calcified strands which in some areas coalesce to form aggregates were seen in hyalinised stromal areas (Fig. 4b). Cellular osteoid strands were also seen in loose fibroblastic stroma. Stromal degeneration and cystic spaces were also seen. The result of which confirmed the diagnosis of ossifying fibroma. Taking into consideration, the age of the patient and histopathological diagnosis, Juvenile ossifying fibroma WHO Type was given as the final diagnosis. Post operatively, 6months later, no recurrence seen. Patient is under regular follow up.

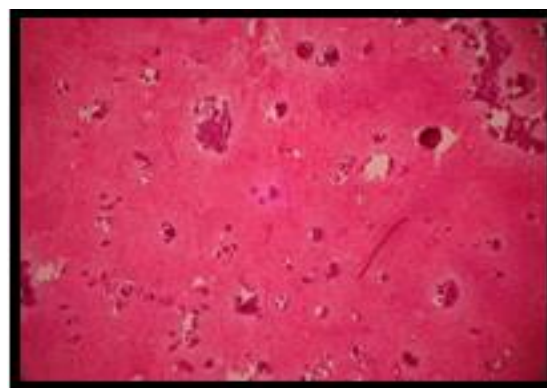


Fig. 4a: Bony trabeculae of varying size in fibrocellular stroma

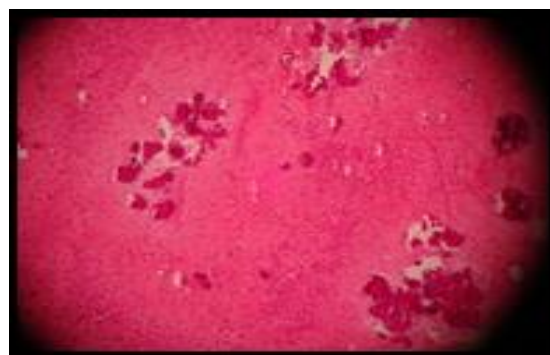


Fig. 4b: Large areas of irregular calcified strands coalesce to form aggregates

Discussion

The JOF, as the name suggests, has its higher incidence in children and young adults.^(2,3) Among the many classification systems for this lesion, the classification by Slootweg et al.⁽⁴⁾ had divided JOF into two distinct groups, the JOF-WHO type and JOF-PO (psammoma-like ossicles) type, based primarily on the difference in the age of occurrence: the mean age of occurrence of JOF WHO is 11.8 years and that of JOF-PO is 22.6 years.⁽⁴⁾ El-Mofty⁽⁵⁾ recent classification identified two categories, trabecular JOF (TJOF) and psammomatoid JOF (PJOF), based on histologic criteria. However, the two categories also have a distinct predilection for specific age-groups: the average age of occurrence of TJOF is 8½–12 years, whereas that of PJOF is 16–33 years.⁽⁵⁾ In the present case, the age of the patient was 11 years and so it was categorized as JOF-WHO type.

Although JOF can occur anywhere in the skeleton, its highest incidence is in the facial bones, most commonly the maxilla^(2,6) and very rarely can be seen in mandible.⁽³⁾ In the present case it was seen in left posterior (premolar and molar region) of mandible.

Gender predilection has been a matter of controversy, with some authors claiming no predilection for either gender, whereas Johnson et al. found a higher incidence in females⁽²⁾ and El-Mofty

reported a male predilection.⁽⁵⁾ In the present case, the lesion was found in a female.

JOF clinically manifests as an asymptomatic bony-hard swelling, the duration and extent of which may vary depending on the site and aggressiveness of the lesion. It can expand the involved bones, causing facial asymmetry due to the swelling. Depending on the site, symptoms such as pain, paresthesia, malocclusion, sinusitis, proptosis, etc., can also occur.^(6,8) Radiographically, it can be radiolucent, mixed, or radiopaque, like any fibro osseous lesion depending on the degree of calcification,⁽⁴⁾ with root displacement commonly and resorption rarely.^(4,6,8) The lesion can cause expansion as well as perforation.⁽⁵⁾ A 'ground-glass' appearance on radiographs has been reported which can be mistaken for fibrous dysplasia.⁽⁵⁾ It usually has a concentric or centrifugal growth pattern, which can lead to a clinical diagnosis of cemento-ossifying fibroma.^(6,9) In the present case, the lesion showed all the characteristic radiographic features of ossifying fibroma except the perforation of buccal or lingual plates.

The microscopic features of the lesion are distinctive and include a cell-rich fibrous stroma containing bands of cellular osteoid without osteoblastic lining, osteoid strands, and trabeculae of woven bone.^(4,5,9) JOF-PO (psammoma-like ossicles) type is slightly more cellular than JOF-WHO type. Due to the resemblance of the psammoma-like ossicles seen in JOF-PO type to the cementicles in cemento-ossifying fibroma, it has been argued that JOF-PO a type of cemento-ossifying fibroma.⁽⁵⁾ However, the marked cellularity of JOF-PO is in sharp contrast to the usually stroma-rich appearance of the latter group of lesions. In the present case, the lesion showed typical microscopic features of cemento ossifying fibroma.

The aggressive nature of this entity, along with the reported high rates of recurrence (30–58%),^(5,6) suggests that JOF should be treated like a locally aggressive neoplasm. Surgical resection, rather than conservative curettage, is therefore the preferred line of treatment.^(3,6) In the present case, as the girl patient was very young and in order to avoid damage to the adjacent vital structure such as inferior alveolar canal, a more conservative approach, that is enucleation was preferred as the choice of treatment.

Conclusion

Juvenile ossifying fibroma is an aggressive lesion which needs to be differentiated clinically and histologically from other fibroosseous lesion so that appropriate treatment can be given in accordance with the age of the patient/ keeping in mind the young age of patient. It is very important to have minimum 5 year follow up.

References

1. Kramer IRH, Pindborg JJ, Shear M (1992) Histological typing of odontogenic tumors. International Histological Classification of Tumours, 2nd edn, World Health Organization. Springer-Verlag, Berlin, Germany.
2. Johnson LC, Yousefi M, Vinh TN, Heffner DK, Hyams VJ, et al. (1991) Juvenile active ossifying fibroma: Its nature, dynamics and origin. *Acta Otolaryngol Suppl* 488:1–40.
3. Zama M, Gallo S, Santecchia L, Bertozzi E, De Stefano C (2004) Juvenile active ossifying fibroma with massive involvement of the mandible. *Plast Reconstr Surg* 113:970–4.
4. Slootweg PJ, Panders AK, Koopmans R, Nikkels PG (1994) Juvenile ossifying fibroma: An analysis of 33 cases with emphasis on histopathological aspects. *J Oral Pathol Med* 23:385–8.
5. El-Mofty S (2002) Psammomatoid and trabecular juvenile ossifying fibroma of the craniofacial skeleton: Two distinct clinicopathologic entities. *Oral Surg Oral Med Oral Pathol Oral Radiol Endod* 93:296–304.
6. Noffke CE (1998) Juvenile ossifying fibroma of the mandible: An 8 year radiological follow-up. *Dentomaxillofac Radiol* 27:363–6.
7. Rinaggio J, Land M, Cleveland DB (2003) Juvenile ossifying fibroma of the mandible. *J Pediatr Surg* 38(4):648–650.
8. Williams HK, Mangham C, Speight PM (2000) Juvenile ossifying fibroma: An analysis of eight cases and a comparison with other fibro-osseous lesions. *J Oral Pathol Med* 29:13–8.
9. Knox GW, Roth M, Saleh H, Stiles W (1996) A unique temporal bone lesion resembling juvenile active ossifying myxoma. *Am J Otol* 17:297–300.