

## Minimally invasive techniques for periodontal therapy

Agraja Patil<sup>1,\*</sup>, Swapna Mahale<sup>2</sup>, Chaitanya Joshi<sup>3</sup>

<sup>1,3</sup>PG Student, <sup>2</sup>Professor & HOD, Dept. of Periodontology, MGV KBH Dental College & Hospital, Nashik, Maharashtra

**\*Corresponding Author:**

Email: agraja@gmail.com

### Abstract

Periodontal diseases are one of the most prevalent oral maladies since ages. It is a disease that causes destruction of the supporting tissues of the teeth and eventual loss of teeth. Different therapies have been searched, explored and applied for the treatment of this disease. Conventional periodontal regenerative procedures involving large periodontal flaps for access are employed to improve short- and long-term clinical outcomes of periodontally compromised teeth. Minimally invasive techniques have evolved from magnification devices to advanced surgical instruments and modified procedures. They are characterized with minimized incisions and trauma to the soft tissue that prove to be advantageous over the conventional therapy. This article reviews various minimally invasive procedures and highlights the advantages of minimally invasive surgical and non-surgical therapy.

**Keywords:** Minimally invasive, Papilla preservation, Periodontal surgery, Robotics, Videoscope

### Introduction

Gone are the days of saying, “no pain, and no gain”. Centuries ago, Sushruta, the father of surgery invented techniques to cure the ailments of the human kind. He fathered extensive surgical techniques in such diseased individuals at the risk of high patient mortality and morbidity. But now we approach the 22<sup>nd</sup> century, it is the time to revolutionize those methods to ensure fewer complications in terms of mortality and morbidity and better therapeutic success rate. Hence a variety of interventional methods are constantly born in the minds of researchers, one of them being the era of minimally invasive surgical techniques (MIST). MIST ensures very less trauma during an intervention but still achieves a satisfactory therapeutic benefit.

Post-operative pain and discomfort is one of the most common complications after any surgical procedure. In addition to that, duration of the surgery and hospital admission plays a crucial role on the psych of the patient. Intraoperative extensive manipulation of the tissues can lead to scarring and edema during wound healing. There is a constant quest going on to eliminate these complications.<sup>(1)</sup> Minimally invasive surgical techniques aim to have an advantage over conventional techniques by proving to be a less invasive technique with maximum benefits. Hence the goals of MIST are:<sup>(2)</sup>

1. Less access trauma
2. To maintain quality of surgical procedures
3. Be less invasive: less pain and fast recovery
4. To subject patient to least physical discomfort during and post surgery
5. No visible scarring post-healing.

### Definitions

A minimally invasive surgical procedure should be defined as one that is safe and is associated with a

lower postoperative patient morbidity compared with a conventional approach for the same operation. According to Medical Subject Headings (MeSH), minimally invasive procedures in medicine can be defined as those procedures that avoid use of open invasive surgery in favor of closed or local surgery.

### Minimally invasive dentistry

The principles of MIST can be applied to dentistry, hence termed as Minimally invasive dentistry (MID). It is aimed at preserving the remaining tooth structure (affected by carious pathology) and the supporting periodontium (affected by periodontal pathology). It requires early detection of the disease, proper analysis and subsequent treatment for the same.<sup>(3)</sup>

Tyas and Colleagues<sup>(4)</sup> (2000) proposed the following concepts:

1. Early caries diagnosis
2. The classification of caries depth and progression using radiographs
3. The assessment of individual caries risk (high, moderate, low)
4. The reduction of cariogenic bacteria, to decrease the risk of further demineralization and cavitation
5. Arresting of active lesions
6. Remineralization and monitoring of non-cavitated arrested lesions
7. Placement of restorations in teeth with cavitated lesions, using minimal cavity design
8. Repair rather than the replacement of defective restorations
9. Assessing disease management outcomes at pre-established intervals.

### Minimally invasive team

Physicians and surgeons who champion minimally invasive surgery are enthusiastic to prove its efficacy

and are approaching the challenge vigorously. At the seat of success of minimally invasive surgery is the constant upgrading of surgical instruments, which have gone from crude, cumbersome gadgets to sophisticated, robotically controlled instruments. Although improved instrumentation makes the procedure easier and more effective, the surgeon must learn to master the new technology. Thus, the procedure involves a learning curve with its risks. We, as surgeons, must be certain that the rate of acceptance does not jeopardize patient safety.

As stated above, MIST requires a world class skill set in the operator coupled with an exemplary operative unit. A coordinated team approach is mandated to ensure patients' safety and excellent outcomes. The team consists of Surgeon, assistants, operating room nurses and circulating staffs. The success of this type of surgery is highly dependent on this infrastructure.<sup>(5)</sup>

### Minimally invasive surgical approach for periodontal regeneration

Periodontal surgery has always aimed to alleviate or eliminate the degeneration associated with progressive periodontal disease.<sup>(6)</sup> In order to accomplish this goal, access to the periodontal defect for debridement has been an integral part of surgical therapy.<sup>(7)</sup> Periodontal regenerative technologies are applied to improve short- and long-term clinical outcomes of periodontally compromised teeth, presenting with deep pockets and reduced periodontal support.<sup>(8)</sup>

Regeneration can be defined as the reproduction or reformation of organs or tissue that have been lost or injured as a result of a wound or infection. Periodontal regeneration results in functionally aligned periodontal ligament fibers between newly formed bone and the root surface.<sup>(9)</sup> Regenerative periodontal procedure involves the creation of new alveolar bone, cementum, and periodontal ligament.

Regenerative therapies have always been accompanied by common complications like flap dehiscence with barrier membrane exposure, contamination of the grafts, foreign-body reactions associated with alloplastic and/or xenogenic graft materials resulting in increased post-operative discomfort etc.<sup>(10)</sup> Thus, to increase the surgical efficacy, the concept of minimally invasive surgical approaches can be practiced.

### Historical background

The first endoscopic procedure was practiced by as far as the era of Hippocrates. In 1870's, Bozinni developed an illuminator to access the meticulous procedures which was introduced to the patients by Desormeaux by 1900's. The term minimally invasive procedure was first coined in an editorial in the *British Journal of Surgery* in 1990. The concept of minimally invasive surgery was further refined by Hunter and

Sackier in 1993 who described the surgical approach as "the ability to miniaturize our eyes and extend our hands to perform microscopic and macroscopic operations in places that could previously be reached only by large incisions".<sup>(11)</sup> Similar concept was applied in periodontology and it helped in handling hard and soft tissues gently during periodontal surgery. Isolated defects not extending beyond the interproximal site were considered ideal for this technique. Tunnel Technique used for regenerative surgeries is an integral part of MIS.<sup>(12)</sup> Periodontal microsurgical techniques have been described by Tibbetts and Shanelec.<sup>(13)</sup>

### Classification of minimally invasive periodontal surgical technique

For the ease of understanding the innovative technique, it can be classified as follows on the basis of the decision to perform regenerative therapy:

1. Non-surgical
2. Surgical

**Non surgical approach:** The etiopathogenic phase or phase I of treatment plan is always aimed at cause related alleviation of the patients and basically comprises of non surgical therapy. Irrespective of any varied pocket depths, the first line of treatment is full mouth supragingival and subgingival scaling and root planing.

Dental endoscope is an imaging device which aids in accurate diagnosis and treatment of periodontal disease. It provides sub-marginal gingival imaging to locate and evaluate the extent and nature of root deposits.<sup>(14)</sup> A preliminary study indicated that up to 95% of all root surfaces may be accessed for visualization with this instrument.<sup>(15)</sup>

Based on the re-evaluation of the patients and radiologic investigations, they can be qualified for a regenerative approach.

Non surgical phase can be majorly sub classified as:

1. Scaling and root planing
2. Adjunctive therapy like Local drug delivery

Scaling and root planning is the most commonly followed and least invasive type of Phase I therapy followed in the treatment plan. There is a huge possibility of resolution of pockets after full mouth supragingival and subgingival scaling and root planning. But if it doesn't happen so, the next least invasive therapy is local drug delivery.<sup>(16)</sup>

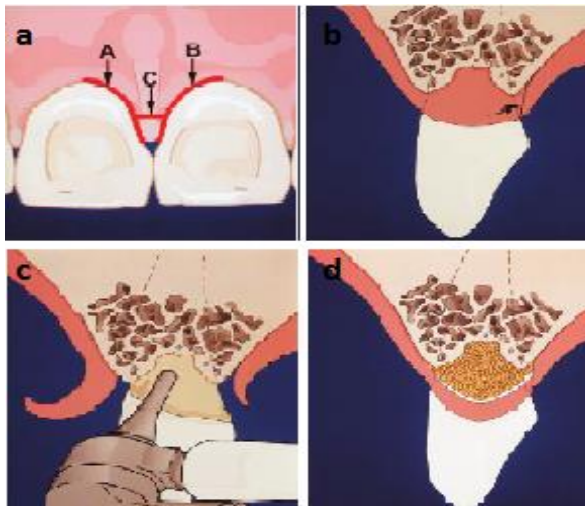
Local drug delivery can be studied under drug delivery systems and the drugs available. Apart from the conventional drugs like tetracycline, minocycline, doxycycline; there are newer options available for injecting in the gingival sulcus. For example,

- a. Botulinum toxin or Botox can be used for micro-esthetic regeneration
- b. i-PRF, an injectable solution for enhancing the gingival biotype, increasing the width of attached gingiva<sup>(18)</sup>

### Surgical techniques:

**For intrabony defects and furcation involvement:** In the 1990s, Cortellini and Tonetti introduced the Modified Papilla Preservation Technique (MPPT) and the Simplified Papilla Preservation Flap (SPPF). Later they proposed a Minimally Invasive Surgical Technique (MIST) on isolated and multiple intrabony defects, and a Modified MIST (M-MIST) on isolated intrabony defect. These surgical techniques along with use of operative microscope led to a drastic limitation of interdental wound failure to less than 30% of the treated cases.

Minimally Invasive Surgical Technique (MIST, Cortellini and Tonetti 2007a, 2007b)<sup>(19)</sup> focuses on the conservative elevation of both buccal and lingual flaps of the defect-associated interdental papilla as described in Fig. 1. Depending upon the width of the interdental space, the papilla may be dissected either diagonally or horizontally. In cases of narrow interdental spaces a diagonal cut is selected, as described in the Simplified Papilla Preservation Flap (SPPF, Cortellini et al. 1999);<sup>(20)</sup> conversely, in cases of wide interdental spaces, horizontal cut is performed as described in Modified Papilla Preservation Technique.<sup>(21)</sup>



**Fig.1 MIST –diagrammatic view**

(a) The intrasulcular incisions used for MIST are shown. Incisions (a and b) should be made as separate incisions. The connecting incision c should be performed as a separate third step (b) A side view of the MIST incisions showing the placement of the connecting incision away from the crest of the papilla (c) The mechanical granulation tissue removing instrument being used to remove granulation tissue from the defect (d) MIS flaps are replaced passively over the graft material. In this drawing the ends of the connecting incision have not been approximated as a butt joint but as a sagittal joint this allows for some coronal positioning of the papilla.

**Modified- MIST:** Cortellini and Tonetti in 2009 suggested a Modified Minimally Invasive Surgical Technique (M-MIST). The primary aim was to provide a minimal access to the defect only from the buccal side. This technique is initiated with minimal elevation of a triangular buccal flap to expose the residual crestal bone. The M-MIST provides a very small interdental access to the defect through a small buccal window and follows the same principles described for the MIST approach. The interdental papilla is not detached from the residual interdental bone crest and supracrestal fibers, and the palatal flap is not elevated. The granulation tissue is carefully dissected and separated from the underlying supra-crestal interdental fibres without causing any trauma to them. After removing the granulation tissue, the roots are scaled and planed. The buccal flap is placed back into its original position and sutured using a modified internal mattress suture, achieving primary closure. This technique has certain limitations and disadvantages. It cannot be employed in cases with complex and wide defects involving 3 or 4 surfaces of a tooth. Larger flaps have to be elevated in cases where the defect extends to the apical third or apex of the root.<sup>(22)</sup>

Various cited randomized clinical trials performed using minimally invasive surgical approaches (with or without papilla elevation) did not report any difference in terms of clinical outcomes between the minimally invasive control flap approach and the test in which a regenerative material/ product was introduced under the flap.<sup>(23,24)</sup>

The M-MIST has been proposed to further reduce invasivity and patient side effects, and to increase the odds for primary closure of the wound and for blood clot stability.<sup>(25)</sup>

The advanced flap design of the M-MIST greatly enhances the potential to provide space and stability for regeneration by leaving the interdental papillary soft tissues attached to the root surface of the crest-associated tooth and by avoiding any palatal flap elevation. The minimal flap extension and elevation also minimizes the damages to the vascular system favoring the healing process of the tiny soft tissues.

When an M-MIST approach is applied, amelogens or growth factors, or no regenerative materials are the possible choices, irrespective of the bone anatomy. In other words, there is no great need for a supportive biomaterial, and most probably, there is little advantage in using regenerative substances. When a MIST approach is applied, amelogens or growth factors can be used in containing defects (narrow two-wall and three-wall) or in combination with filler in non containing defects (one-wall or a wide two-wall).

Wachtel *et al.*<sup>(26)</sup> assessed the clinical effect of the microsurgical access flap and EMD treatment with an emphasis on the evaluation of early wound healing in 11 patients. Both test and control treatment resulted in a statistically significant mean CAL gain of 2.8 and 2.0

mm at 6 months, and 3.6 and 1.7 mm at 12 months, respectively. Two weeks after surgery, primary closure was maintained in 89% of the test sites and in 96% of the control sites. In terms of probing pocket depth reduction and CAL gain, the combination with EMD application appeared to be superior to the microsurgical access flap alone.

**Videoscope assisted minimally invasive surgery:** The term Videoscope assisted minimally invasive surgery (V-MIS) is used to describe MIS performed with the aid of a videoscope. A videoscope comprising of a small digital camera was developed. This camera when placed at the surgical site provides direct visualization and greater magnification (Harrel et al. 2012, 2013). Harrel SK et al in 2014<sup>(27)</sup> studied to evaluate residual defects following non-surgical therapy consisting of root planing with local anaesthetic. V-MIS was performed utilizing the videoscope for surgical visualization. Re-evaluation, 6 months post-surgery, showed statistically significant improvement ( $p < .001$ ) in mean PPD and CAL (PPD  $3.88 \pm 1.02$  mm, CAL  $4.04 \pm 1.38$  mm) in 1, 2, and 3 wall defects. All PPD at re-evaluation were 3 mm or less. There was a mean post-surgical increase in soft tissue height ( $0.13 \pm 0.61$  mm,  $p = 0.168$ ) with a decrease in recession.

**Disadvantages:** Disadvantages of minimally invasive periodontal therapy are probably similar to those related to any MIST in the medical field.

It can be attributed to the following facts:

1. it requires special equipment,
2. specialist training is probably required,
3. some additional equipments could be more expensive, and
4. some procedures may take longer than usual, compared with conventional surgeries.<sup>(23)</sup>

### Future developments

The rapid development of minimally invasive surgery means that there will be fundamental changes in interventional treatment. Technological advances will allow new minimally invasive procedures to be developed. Application of robotics will allow some procedures to be done automatically, and coupling of slave robotic instruments with virtual reality images will allow surgeons to perform operations by remote control.<sup>(28)</sup> Many traditional specialties will be merged, and surgical training will need fundamental revision to ensure that surgeons are competent to carry out the new procedures.

### Conclusion

While many studies did assure the effectiveness of MIPS by the enhancement of clinical parameters and reducing patient morbidity, there is still a need to confirm the effectiveness of such techniques in periodontal surgery when compared with other traditional ones.

### References

1. Christensen GJ. The advantages of minimally invasive dentistry. *J Am Dent Assoc.* 2005;136:1563-5.
2. Wickham JEA. Minimally invasive therapy. *BMJ.* 1991;308:193-6.
3. Rainey JT. Air abrasion: an emerging standard of care in conservative operative dentistry. *Dent Clin North Am.* 2002;46:185-209.
4. Tyas MJ, Anusavice KJ, Frencken JE, Mount GJ. Minimal intervention dentistry: a review. *FDI Commission Project 1-97. Int Dent J.* 2000;50:1-12.
5. Wickham JEA. The new surgery. *BMJ.* 1987;295:1581-2.
6. Zander HA, Polson AM, Heijl LC. Goals of periodontal therapy. *J Periodontol* 1976;47:261-266.
7. Caton JG, Greenstein G. Results of conventional therapeutic techniques for regeneration. Polson AM ed. *Periodontal regeneration.* Chicago. Quintessence Publishing Co. Inc. 1994: 12.
8. Melcher AH. On the repair potential of periodontal tissues. *J Periodontol* 1976;47(5):256-60.
9. Gottlow J. Guided tissue regeneration using bioresorbable and non-resorbable devices: initial healing and long-term results. *J Periodontol* 1993;64(11):1157-65.
10. Murphy KG, Gunsolley JC. Guided tissue regeneration for the treatment of periodontal intrabony and furcation defects. A systematic review. *Ann Periodontol* 2003;8:266-302.
11. Hunter JG, Sackier JM. Minimally invasive high tech surgery; into the 21st century. In: Hunter JG, Sackier JM, eds. *Minimally invasive Surgery.* New York: McGraw-Hill. 1993;3-6.
12. Harrel S K, Rees T D. Granulation tissue removal in routine and minimally invasive surgical procedures. *Compend Contin Educ Dent.* 1995;16:960-967.
13. Tibbetts LS, Shanellec D. Periodontal microsurgery. *Dent Clin North Am.* 1998;42:339-59.
14. Roger V. Stambaugh, Gayle Myers, Wendell Ebling, Bruce Beckman, Kathleen Stambaugh. Endoscopic Visualization of the Submarginal Gingiva Dental Sulcus and Tooth Root Surfaces. *J Periodontol.* 2002;73:374-82.
15. Stambaugh RV, Myers GC, Ebling WV, Beckman B, Stambaugh KA. Endoscopic visualization of submarginal gingival root surfaces. *J Dent Res.* [Abstract] 2000;79:600-605.
16. Gary Greenstein, Alan Polson (1998). The Role of Local Drug Delivery in the Management of Periodontal Diseases: A Comprehensive Review. Position paper: The role of controlled drug delivery for periodontitis. *J Periodontol* 2000;71:125-140.
17. Reynolds MA, Kao RT, Camargo PM, Caton JG, Clem DS, Fiorellini JP et al. Periodontal Regeneration – Intrabony Defects: A Consensus Report From the AAP Regeneration Workshop. *J Periodontol* 2015;86:105-107.
18. Marx RE, Carlson ER, Eichstaedt RM, Schimmele SR, Strauss JE, Georgeff KR. Platelet-rich plasma: growth factor enhancement for bone grafts. *Oral Surg Oral Med Oral Pathol Oral Radiol Endod.* 1998;85:638-646
19. Cortellini P, Tonetti MS. A minimally invasive surgical technique with an enamel matrix derivative in the regenerative treatment of intra-bony defects: A novel approach to limit morbidity. *J Clin Periodontol.* 2007;34:87-93.
20. Cortellini P, Prato GP, Tonetti MS. The simplified papilla preservation flap: A novel surgical approach for the management of soft tissues in regenerative procedures. *Int J Periodontics Restorative Dent.* 1999;19:589-99.
21. Cortellini P, Prato GP, Tonetti MS. The modified papilla preservation technique. A new surgical approach for

- interproximal regenerative procedures. *J Periodontol.* 1995;66:261-6.
22. Cortellini P, Tonetti MS. Improved wound stability with a modified minimally invasive surgical technique in the regenerative treatment of isolated interdental intrabony defects. *J Clin Periodontol.* 2009;36:157–63.
  23. Jaffray B. Minimally invasive surgery. *Arch Dis Child.* 2005;90:537–42.
  24. Rohit Khurana, Praveen B. Kudva, Shukla Aanchal Sanjeev, Hema P. Kudva. Minimally invasive periodontics - need of the hour!!. *International Journal of Contemporary Medical Research* 2016;3(6):1762-1765.
  25. Aous Danna. Minimally Invasive periodontal surgery. *J Indian Soc Periodontol.* 2011;15:338-343.
  26. Wachtel H, Schenk G, Bohm S, Weng D, Zuhr O, Hurzeler MB. Microsurgical access flap and enamel matrix derivative for the treatment of periodontal intrabony defects: A controlled clinical study. *J Clin Periodontol.* 2003;30:496–504.
  27. Harrel SK, Abraham CM, Rivera-Hidalgo F, Shulman JD, Nunn ME. Videoscope assisted minimally invasive periodontal surgery (V-MIS). *J Clin Periodontol.* 2014;41: 900–907.
  28. Satava RM, Bowersox JC, Mack M ET AL. robotic surgery: state of the art and future trends. *Contemp Surg.* 2001;57:489-99.