

## Pyogenic Granuloma- A case report

Hemant Goel<sup>1,\*</sup>, Amita Goel<sup>2</sup>, Ritika Jindal<sup>3</sup>

<sup>1</sup>Reader, Dept. of Prosthodontics, Saraswati Dental College, Lucknow, <sup>2</sup>Professor, Dept. of Pedodontics, ITS Dental College, Muradnagar, <sup>3</sup>Senior Consultant, New Delhi

**\*Corresponding Author:**

Email: goelhemant77@gmail.com

### Abstract

Pyogenic granuloma is the non-neoplastic reactive soft tissue growth. It is inflammatory hyperplasia commonly affects the oral cavity. It predominantly occurs in second decade of life and commonly affects the females. It usually has asymptomatic clinical course with rarely causing resorption of underlying bone. Complete excision of lesion is the treatment of choice with removal of local etiological factors. We present a case report of pyogenic granuloma affecting mandibular gingival in 32year old female patient. Total excision of the lesion was done with no reported recurrence following a month follow up.

**Keywords:** Pyogenic granuloma, Epulis, reactive, Gingiva, Mandible.

#### Access this article online

**Website:**

[www.innovativepublication.com](http://www.innovativepublication.com)

**DOI:**

10.5958/2395-499X.2016.00037.X

### Introduction

Soft tissue enlargements of the oral cavity are very common and often cause a diagnostic challenge to clinicians. There are multiple pathological conditions which can produce similar type of lesions. Pyogenic granuloma is one among the common entities causing soft tissue growth in oral cavity.<sup>1</sup>

Pyogenic granuloma is a soft tissue enlargement; considered to be a reactive non- neoplastic lesion. It is a benign inflammatory reaction commonly seen in females and considered to be related to high levels of steroid hormones in females. Various factors contribute to its etiopathogenesis like local irritation, traumatic injury, hormonal factors or certain kind of drugs. In reponse to these chronic irritants the fibrovascular connective tissue becomes hyperplastic which leads to formation of pyogenic granuloma.<sup>2</sup>

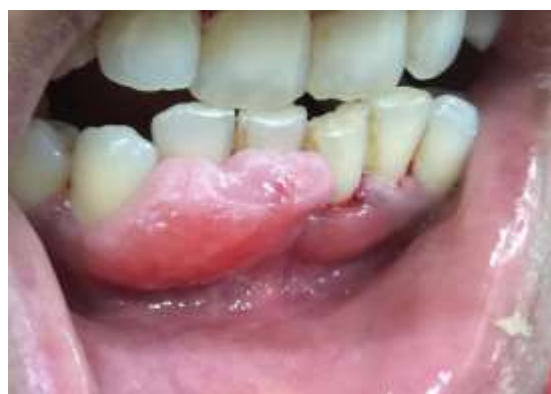### Case

A 32year old female visited our private clinic with complain of swelling in mandibular anterior region since 4months. The lesion started as small painless gingival mass which increased in size gradually. Patient consulted for the problem to some other private dental practitioner, the lesion was excised and but no hisopathology reports were obtained. Later patient reported recurrence of lesion at same location. On examination a pink sessile smooth gingival swelling noticed irt 41, 42, 43 involving marginal and attached gingiva. The lesion was approximately 2\*1cm in size. The color was similar to surrounding gingiva. On

palpation the lesion was painless, firm, non-pulsatile, non-reducible, non-compressible. No mobility noticed in involved teeth. There was presence of calculus on both buccal and lingual aspects of mandibular anterior teeth. Radiograph of the region did not reveal significant changes, certain amount of bone loss noticed in interdental region. Patient's gestational history revealed that she delivered a child 4 years back and presently was not taking any contraceptive medication.

Considering the clinical presentation a provisional diagnosis of pyogenic granuloma was made. Other differentials of inflammatory gingival hyperplasia, peripheral ameloblastoma, peripheral ossifying fibroma were also considered.

Excision of lesion was done with removal of local irritants and on histopathology diagnosis of pyogenic granuloma was confirmed.



**Fig. 1**

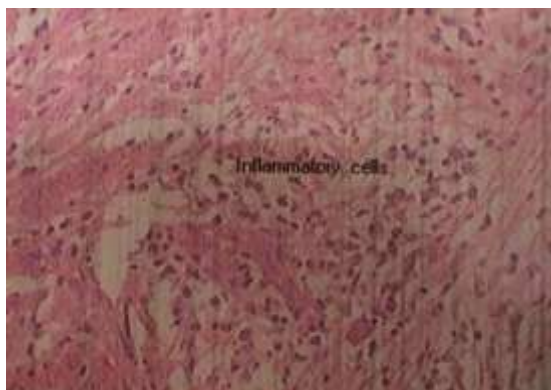

Fig. 2

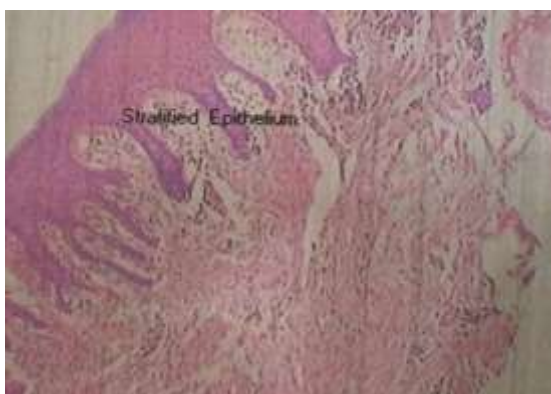


Fig. 3

### Discussion

Pyogenic granuloma is a hyperplastic response secondary to inflammation. It is a soft tissue tumor like growth which is non-neoplastic in nature. The term pyogenic granuloma or granuloma pyogenicum was given by Hartzell in 1904.<sup>3</sup> The term is a misnomer since the term pyogenic implies pus forming but actually the lesion does not contain pus and histological features also does not relate to granuloma.<sup>4</sup>

Benign reactive lesion arises in response to various stimuli such as chronic low-grade local irritation, traumatic injuries, hormonal factors or certain kind of drugs. Poor oral hygiene and tooth brush trauma are predisposing for gingival cases. Infective organisms such as *Bartonella henselae*, *B. Quintana*, HHV-8 have been identified in few cases and considered to be associated with recurrent pyogenic granuloma.<sup>5</sup> Most of the cases of extralingival pyogenic granuloma occur after history of trauma.

Oral pyogenic granuloma mostly involves the gingiva but also affects lips, tongue and buccal mucosa. Lesion are more common on maxillary anterior gingiva than mandibular gingiva, Facial/ buccal gingiva more commonly affected than lingual/ palatal gingiva.<sup>6</sup>

It can affect any age group but predominantly occur in second decade of life in young adult females, this could possibly because of vascular effects of female hormones.<sup>6</sup>

Clinically it appears as smooth or lobulated exophytic lesion manifesting as small, red erythematous papules on pedunculated/ sessile base. The size of the lesion can vary from few mm to few cm. Slow, painless and asymptomatic clinical course.<sup>7</sup> Depending on the chronicity of the lesion the color may vary from pink to purple.

Pyogenic granuloma in early phases bleed easily since the lesion at this stage is hyperemic with prominence of capillaries.<sup>8</sup>

Cases of pyogenic granuloma occurring in pregnancy are known as “pregnancy tumor”/ “granuloma gravidarum”. This can be attributed to 5% of cases of pyogenic granuloma. The hormonal imbalance coincident with pregnancy heightens the organism response to irritation.<sup>4</sup> Generally it appears in 1<sup>st</sup> trimester of pregnancy and regress spontaneously after delivery. Similar lesion have been reported on patients with oral contraceptives.

Histologically the lesion shows highly vascular proliferation that resembles granulation tissue. The vascular channels are engorged with red blood cells and cells of inflammation polymorpho neutrophils and monocytes are seen scattered in the stroma of the lesion. Histologically pyogenic granuloma are of two kinds lobular capillary hemangioma (LCH) and non-LCH type.<sup>9</sup> In LCH types blood vessels are organized in lobular aggregates, however in non LCH types resembles highly vascular proliferation like granuloma.

Differential diagnosis includes peripheral giant cell granuloma, peripheral ossifying fibroma, metastatic cancer, hemangioma, angiosarcoma, Kaposi sarcoma.

PGCG is more bluish purple as compared to red of typical PG. PGCG is more likely to cause bone resorption. Generally clinically this is indistinguishable from PG, histologically it shows multinucleated giant cells with absence of infective source. Peripheral ossifying fibroma exclusively occur on gingiva and has minimal vascular component. Metastatic tumors are uncommon in oral cavity; when involving gingiva mostly affects attached gingiva. In comparison to PG hemangiomas shows positive diascopy test. They are more plump with endothelial proliferation and no acute inflammatory cell infiltrate is seen in these lesions.<sup>5</sup>

Excisional biopsy is usually indicated as treatment with removal of causative irritants (plaque, calculus, foreign materials). Other modalities indicated are Nd: YAG laser (low risk of bleeding), cryosurgery, electrodesiccation, sclerotherapy. In the cases of pregnancy careful oral hygiene, removal of dental plaque, use of soft tooth brushes are important to avoid occurrence of a pregnancy tumor. If lesion occurs surgical and periodontal treatment can be considered during second trimester with continuous follow ups.<sup>2</sup>

After excision recurrence occurs in 16% of cases then reexcision is necessary. Recurrence is believed to result from incomplete excision, failure to remove etiologic factors or re-injury of the area.

**Conclusion**

Pyogenic granuloma is one of the soft tissue growth involving oral cavity. Although it most commonly affects the maxillary anterior gingival we presented a case of pyogenic granuloma affecting mandibular anterior region with history of recurrence of lesion. It usually has asymptomatic clinical course with rarely causing resorption of underlying bone. Complete excision of lesion is the treatment of choice with removal of local etiological factors.

**References**

1. Kamal R, Dahiya P, Puri A. Oral pyogenic granuloma: Various concepts of etiopathogenesis. *Journal of oral and maxillofacial pathology*.2012;16(1).
2. Verma P, Srivastava R, Baranwal H, Chaturvedi T, Gautam A, Singh A. Pyogenic granuloma-Hyperplastic lesion of the gingival: case reports. *The open dentistry journal*. 2012;6:153-156.
3. Hartzell MB. Granuloma pyogenicum. *J Cutan Dis syph*.1904;22:520-525.
4. Eversole L R. *Clinical outline of oral pathology: diagnosis and treatment*. 2002; 3<sup>rd</sup> edn:113-114.
5. Janier M. Infection and angiomatous cutaneous lesions. *J Mal Vasc*.1999;24:135-138.
6. Neville B W, Damm D D, Allen C M, Bouquot J E. *Oral and maxillofacial pathology*. 2002; 2<sup>nd</sup> edn:437-495.
7. Greenberg M S, Glick M. *Burket's oral medicine: diagnosis and treatment*. 2003; 10<sup>th</sup> edn:141-142.
8. Regezi J A, Sciubba JJ, Jordan RCK. *Oral pathology: clinical pathologic considerations*. 2003;4<sup>th</sup> edn:115-116.
9. Mills S E, Cooper PH, Fechner RE. Lobular capillary hemangioma: the underlying lesion of pyogenic granuloma. *Am J Surg Pathol*.1980;4:470-479.