

Innovating the Art of Impression Techniques in Prosthodontic Rehabilitation of Atrophied Mandibular Ridges: A Case Report

Himanshu Aeran^{1,*}, Varun Kumar², Charu Taneja³

¹Director Principal, Professor & HOD, ²Reader, ³PG Student, Dept. of Prosthodontics, Seema Dental College & Hospital, Rishikesh, Uttarakhand

***Corresponding Author:**

Email: drhimanu@yahoo.com

Abstract

The prosthetic rehabilitation of an atrophic mandible is usually unsatisfactory due to the lack of support tissues, mainly bone and keratinized mucosa for treatment with conventional prosthesis. The prosthetic instability leads to social and functional limitations and chronic physical trauma decreasing the patient's quality of life. Severe resorption contributes to the instability and discomfort with the conventional acrylic resin denture. The objective is to develop an impression technique that provides maximum support of hard tissues and soft tissues. The article in the form of a clinical case report describes the process of fabrication of complete denture by using McCord and Tyson and neutral zone to overcome the problem associated with asymmetric atrophic ridge.

Keywords: Atrophic ridge, McCord's Tyson technique, Neutral zone

Access this article online

Website:

www.innovativepublication.com

DOI:

10.5958/2395-499X.2016.00035.6

Introduction

Gross mandibular atrophy has been described as multifactorial, biophysical process associated with a lot of procedures with a aim to reconstruct and replace mandible and maxilla for the patients having diminished mandibular alveolar ridge.¹ Treating the highly resorbed mandibular ridge along with average response of the patient to all clinical procedures requires clinical skills and knowledge.²

The art and science of complete denture fabrication or oral rehabilitation has been debated for over a century.³ Making a definitive impression in long term edentulism and use of ill-fitting dentures in patients had led the medical and dental specialist look forward to a prosthodontist to innovate different techniques.² Prosthetic management chiefly involves amalgamation of different impression techniques with the intent of maximum retention and stability, tissue support, facial appearance so as to function efficiently and comfortably in harmony with the stomatognathic system and temporomandibular joint.⁵ The change in the impression techniques can be attributed to the increasing complex denture cases due to increase in life expectancy of the population which leads to the evolution of new impression materials and better understanding of underlying tissues.³

The present technique emphasizes on the concept of tissue placement and determination of the extent of

mucobuccal denture extension which is achieved by the uniform application of pressure over stress bearing areas and, McCord and Tyson technique that advocated the use of admixed impression compound for definitive impression and neutral zone technique, as an alternative approach in constructing stable complete denture in case of high atrophic mandible.²

This article presents a novel, cost effective technique for increased stability for mandibular arch and improving prognosis of the prosthesis.²

Case Report

A 55 years old edentulous female patient reported to the department of prosthodontics with a chief complaint of difficulty in eating and deglutition. On intra oral examination upper and lower arches were completely edentulous in which mandibular ridge was atrophied (atwood class iv) with a shallow sulcus depth (Fig. 1). The patient was old denture wearer since 6 years but was not satisfied with it due to the looseness of the denture and difficulty in mastication. The interocclusal space was 7mm.

Various materials are available for the fabrication of complete denture which were discussed with the patient and considering the socio-economic status in mind the following treatment objectives were planned.

- To rehabilitate the patient with complete denture therapy.
- To achieve maximum prosthesis stability, comfort, and function.
- To locate the neutral zone and accordingly arrange the denture teeth and contour the complete denture polished surfaces.
- To minimize the ongoing diminution of the residual alveolar ridges.

- Restoration of the lost vertical dimension to about 5 mm.

Treatment procedure

At the first visit, preliminary impression of the maxillary and mandibular edentulous arches were made using McCord's technique[3 parts impression compound (DPI pinnacle impression compound)+ 7 parts green stick compound(DPI pinnacle tracing sticks)] in a metal stock tray²(Fig. 2).

1. Preliminary mandibular impression was refined using the irreversible hydrocolloid(Alginate DPI) over existing primary impression and then removed, disinfected and poured in plaster of paris (type II) within 12 mins.
2. Primarycasts were prepared.(Fig. 3). Full coverage spacers were fabricated on primary cast(Fig. 4) and the custom tray were fabricated using self-cure resin (DPI) over the primary cast keeping the border 2mm short of the sulcus(Fig. 5).
3. The borders of trays were molded using (DPI) low fusing compound(Fig. 6)and secondary impression were made with zinc oxide eugenol impression paste (Fig. 7). The master casts were poured in dental stone (type III)(Fig. 8).
4. Waxocclusal rims were fabricated on master cast and used to record tentative vertical dimension and centric relation. Vertical dimension was quite raised from the previous denture during this visit. Facebow transfer was made and centric jaw relation was recorded.onsemiadjustable (hanau H₂) articulator. Incorporation of struts in mandibular acrylic denture base helped with the retention of the low fusing compound.(Fig. 9) Maxillary occlusal rim with mandibular impression compound rim were used as per patient vertical dimension.
5. Maxillary record base with occlusal rim and mandibular record base with impression compound rim were adjusted and evaluated intraorally for their fit (Fig. 10). The maxillaryocclusal rim was left in mouth in order to provide enough support to the facial musculature during making impression with neutral zone technique and impression compound occlusal rim was adjusted in patient mouth and patient was asked to perform the usual mandibular movements which include swallowing, movements of lips, pronouncing vowels, which helped in recording neutral zone space(Fig. 11). This completes the procedure of jaw relation(Fig.12).
6. Neutral zone space was evident within plaster indices. Next, molten wax flowed in the empty neutral zone space in order to create rim for arranging mandibular teeth in neutral zone.
7. According to the neutral zone concept maxillary and mandibular teeth were arranged. The wax

contour were preserved in case of mandibular denture as derived from neutral zone and no additional wax was added on denture flanges.⁶

8. The putty index was then made for the mandibular compound rims to recover the occlusal rims in wax. The base and the catalyst paste(addition silicone in putty consistency) were hand-mixed in an equal ratio and adapted to the facial and lingual surfaces of lower compound rims without covering the occlusal surface. After 10 min, the set impression material was carefully removed from the compound rims. The buccal and lingual portions were removed as two separate pieces. The shape of the dentures was now permanently registered in these putty indices. The modelling wax melted and poured into the index through the space between the labial and lingual indices on the occlusal surface. Thus, mandibular lower wax occlusal rims were formed. The index would have preserved the space of the neutral zone. Teeth arrangement was done exactly following the index. The position of the teeth was checked by placing the index together around the wax try-in.(Fig. 13)
9. Try-in was done in order to evaluate stability, esthetics and occlusion intraorally and Then the dentures were proceed with heat cure acrylic resin.(Fig. 14).

Later on, wax was removed from the labial and the lingual surfaces of the trial dentures leaving only minimal wax which could support the teeth that were placed. Patient was trained for making physiological movements such as tongue, cheek and lip movements. Once the patient was trained regarding the functional movements zinc oxide eugenol impression paste(DPI) was placed on the labial as well as lingual surfaces of the trial dentures and patient was asked to perform movements(Fig. 15 c). This procedure was carried out for the mandibular arches. This recorded the polished surfaces of the denture according to the neutral zone. Once the try-in was satisfactory it was processed and finished. Care was taken during finishing and polishing of the dentures so that the contours recorded previously were unaltered³(Fig.16a)

10. Denture insertion was done and again it was evaluated for stability, esthetics and occlusion. Results was found satisfactorily and patient was also satisfied with the denture(Fig. 16b). Patient was recalled at regular intervals of time for post insertion adjustment procedure.

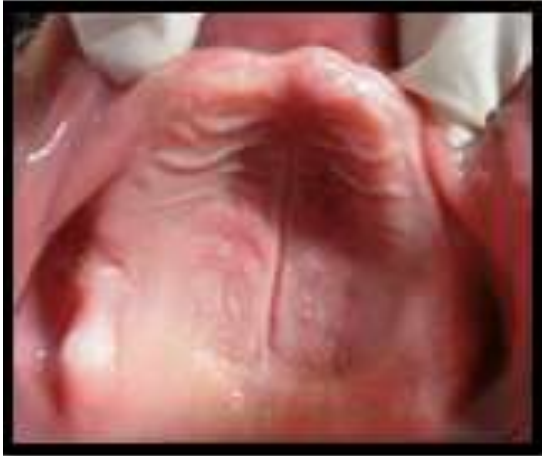

Fig. 1 a: Edentulous maxillary ridge

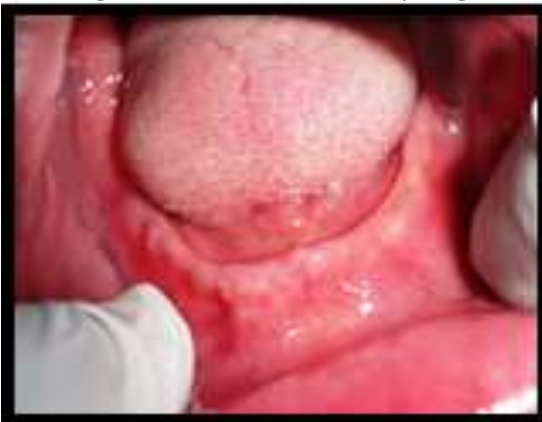

Fig. 1 b: Edentulous Mandibular Ridge

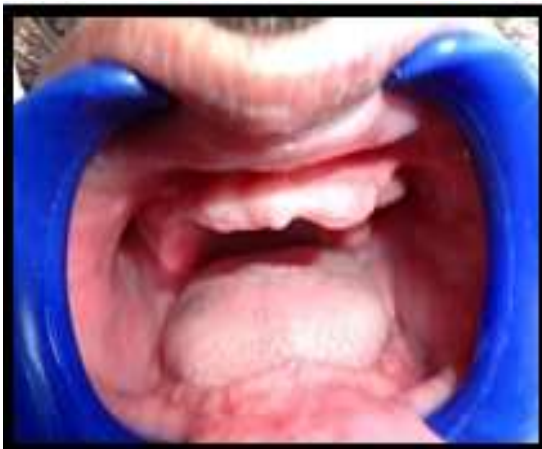

Fig. 1c: Shows maxillary and mandibular edentulous ridges

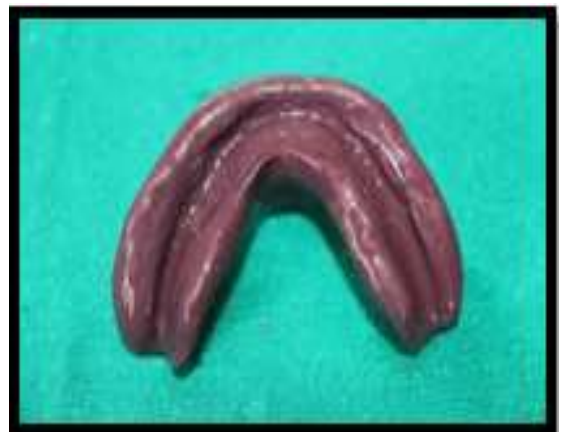
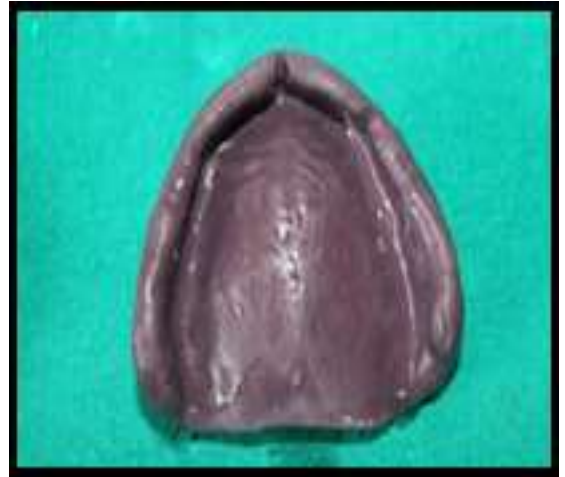
Fig. 2: Primary impressions using McCord and tayson technique



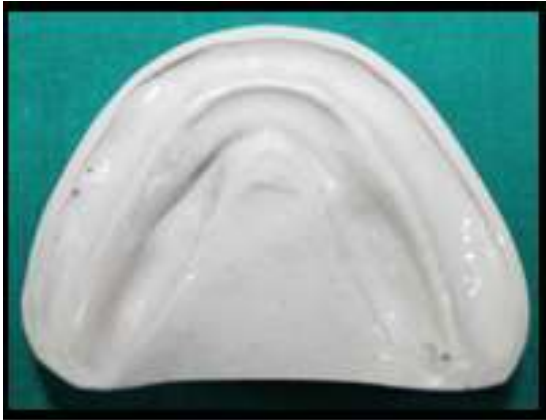

Fig. 3: Primary maxillary and mandibular casts

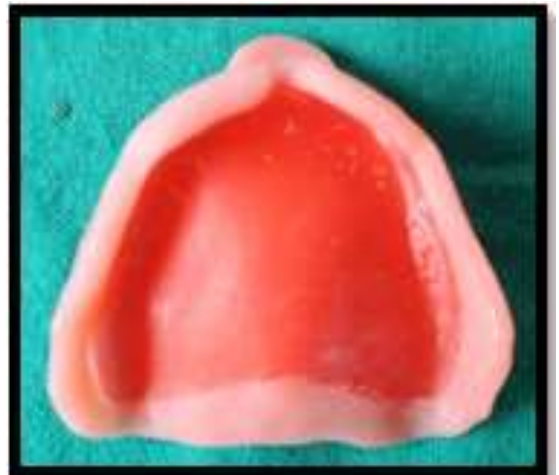

Fig. 5 Removal of Maxillary and mandibular custom tray

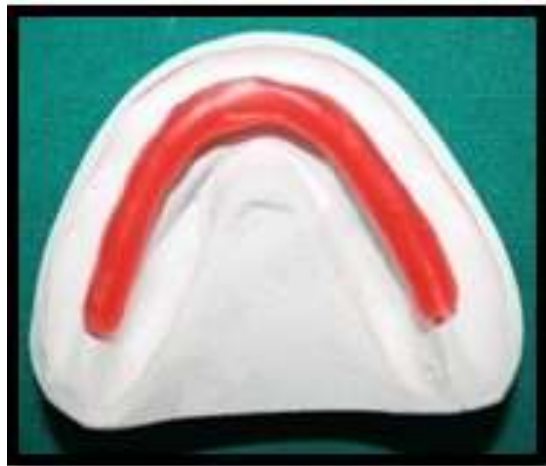

Fig. 4: Maxillary spacer Mandibular double spacer

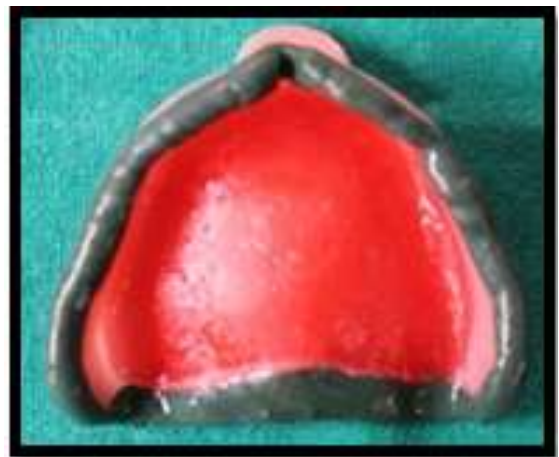



Fig. 6: Border moulding

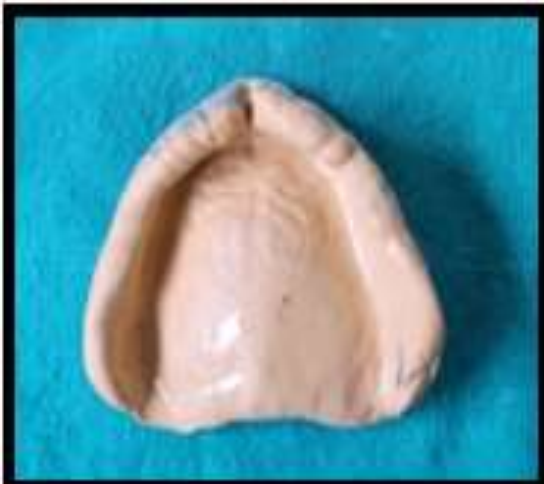

Fig. 8: Master casts

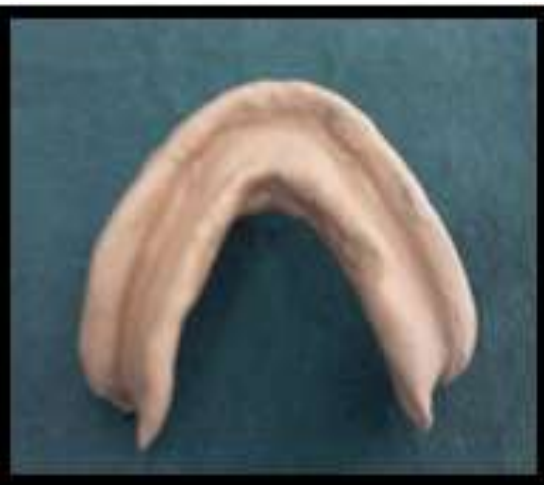

Fig. 7: Secondary impression

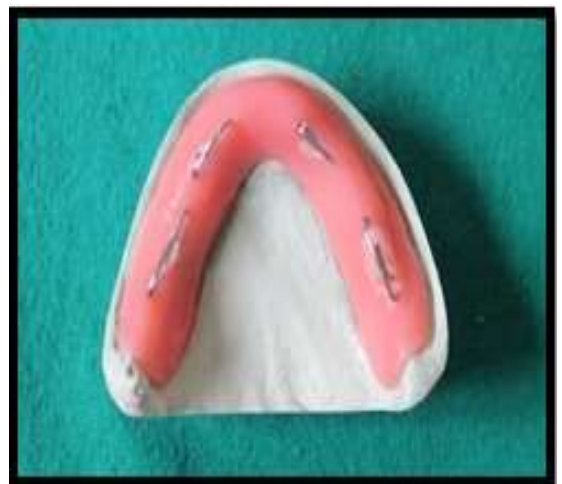

Fig. 9: Incorporation of retention loops in mandibular denture base

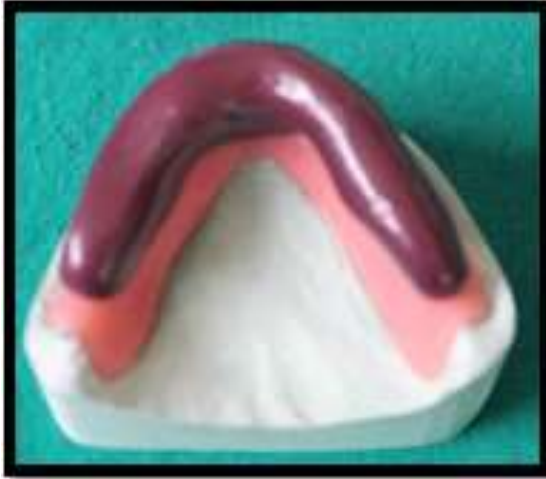

Fig. 10 a

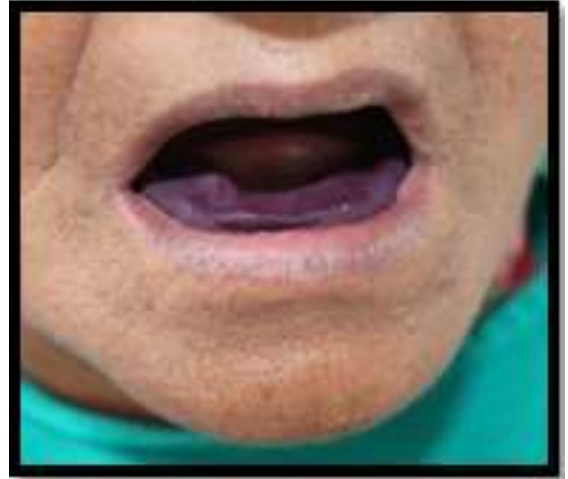

Fig. 10 d

Neutral zone recording using impression compound

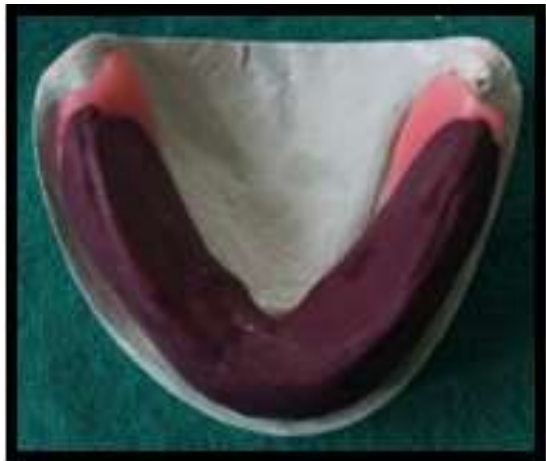

Fig. 10 b

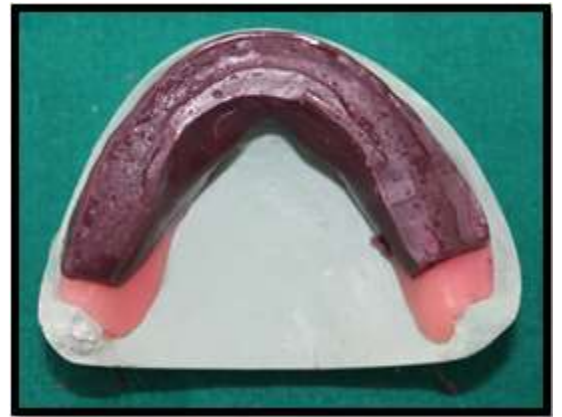

Fig. 11: Mandibular rim adjusted according to the vertical

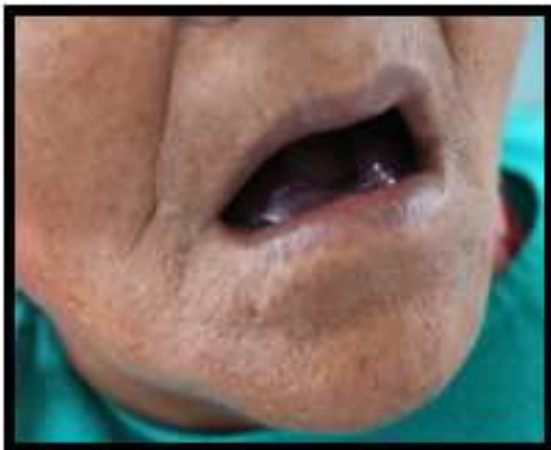
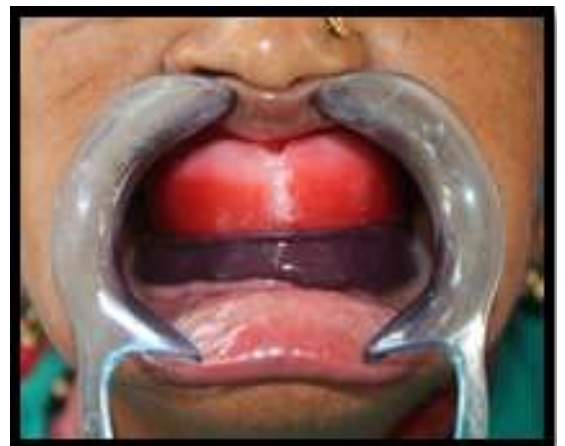
Fig. 10 c



Occlusal rim in patient's mouth



Fig. 12: Jaw relations

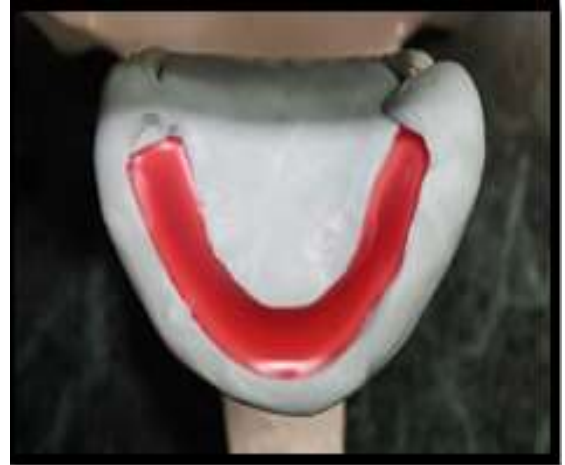

Fig. 13 c

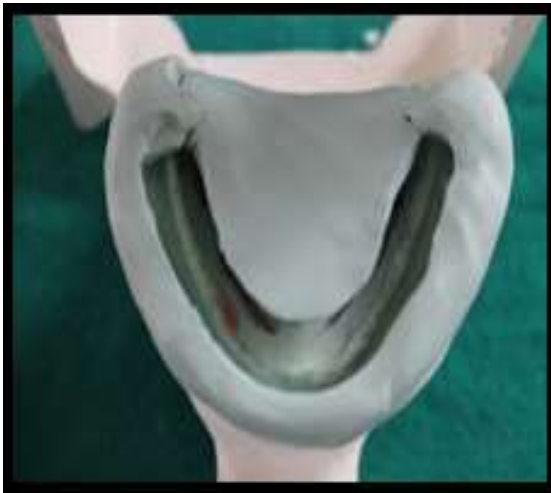

Fig. 13 a

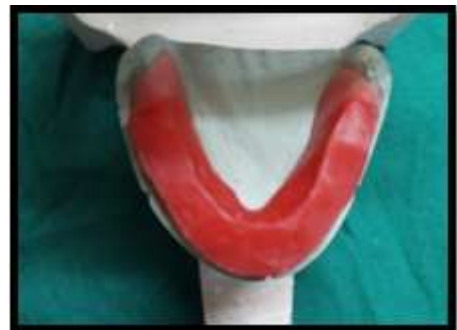

Fig. 13 d: Molten wax poured to fabricate rim in neutral zone recorded in occlusal rim

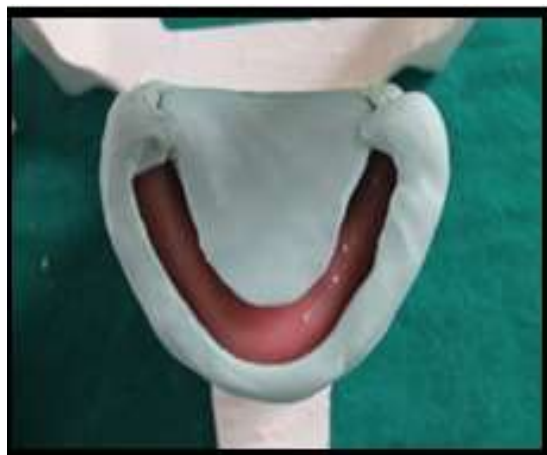

Fig. 13 b: Molten wax poured to fabricate rim in neutral zone

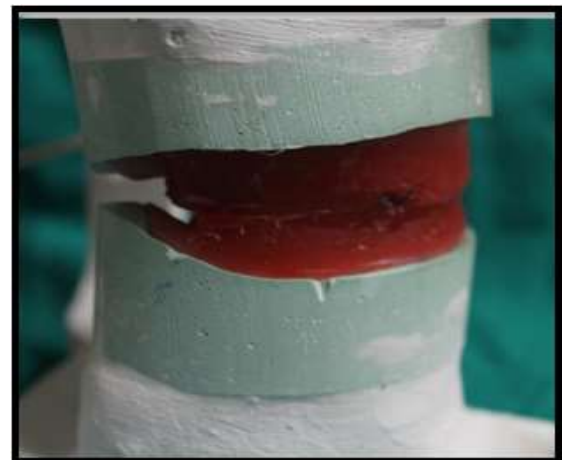


Fig. 13 e: Articulated casts

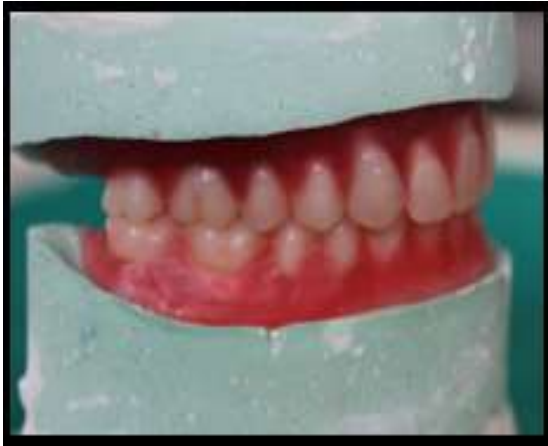

Fig. 14 a

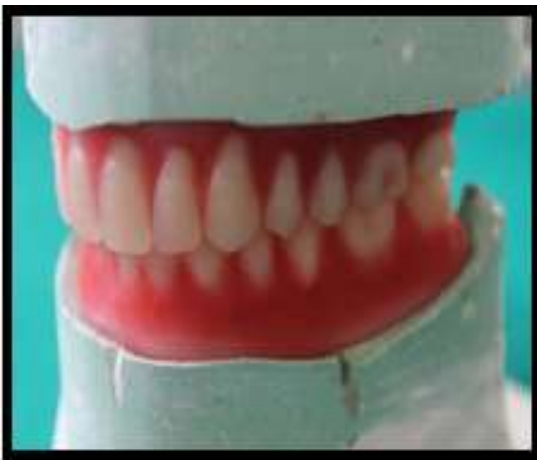
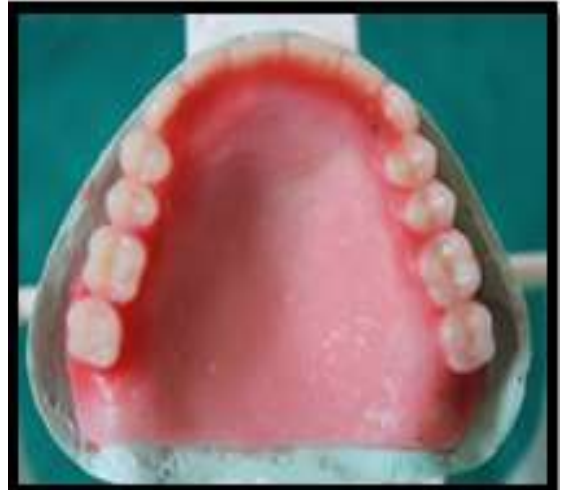
Fig. 14 b

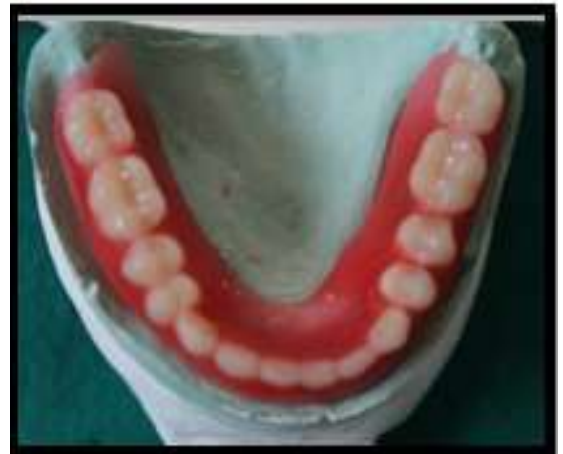

Fig. 14 d: Teeth arrangement in neutral zone

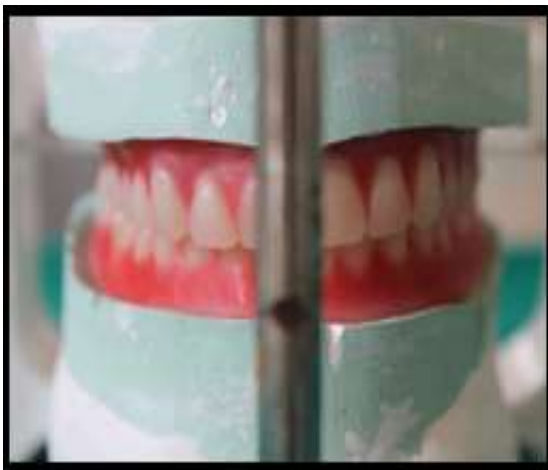

Fig. 14 c

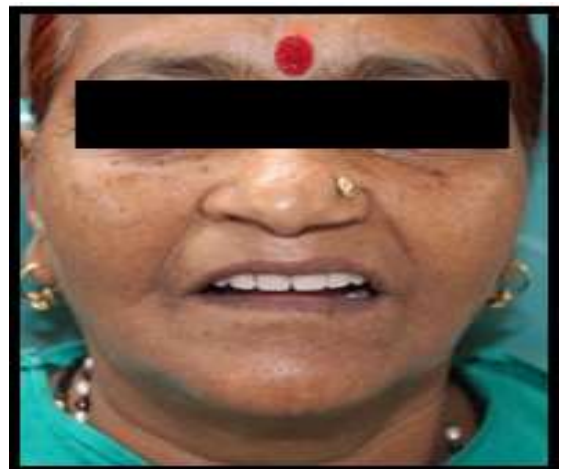

Fig. 15 a

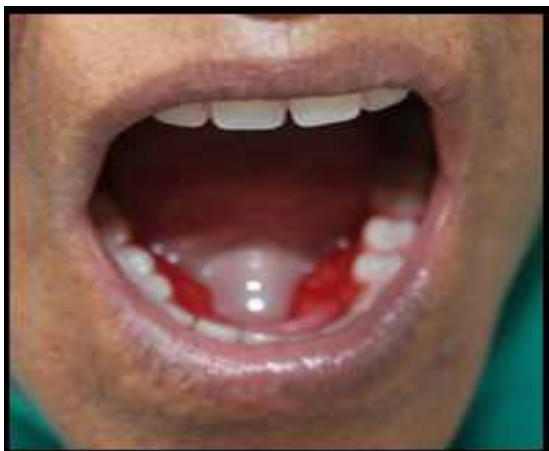

Fig. 15 b: Try-in in patient mouth

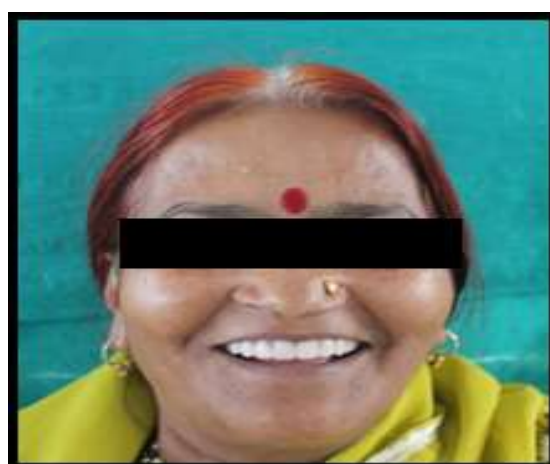
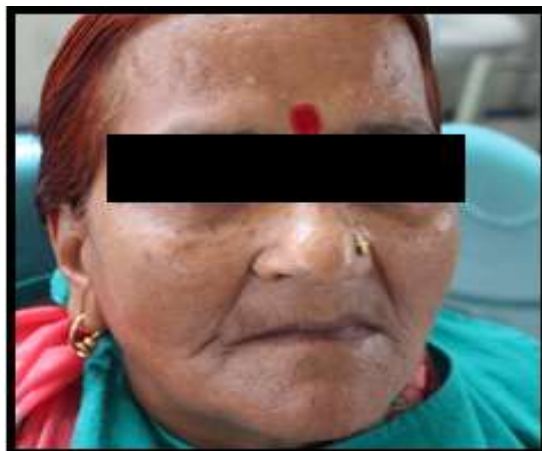
Fig. 16 b: Post-operative photograph

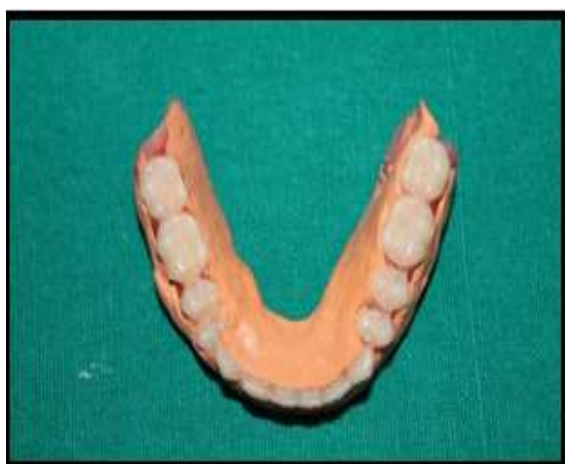

Fig. 15 c: External functional impression recorded

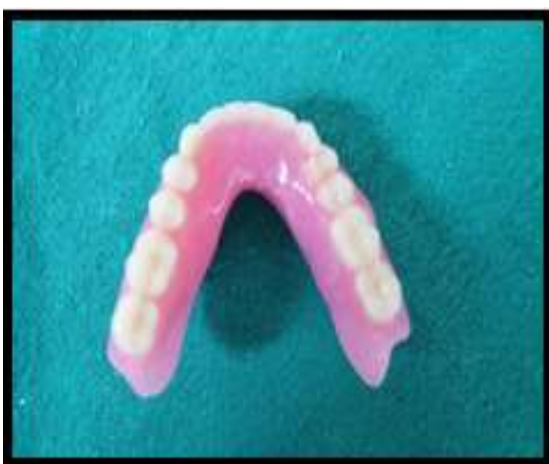

Fig. 16 a: Final mandibular prosthesis

Discussion

Severe ridge atrophy leads to increased interarch space that leads to non-retentive mandibular denture with inability to withstand masticatory forces. Management of problems associated with class IV atrophied mandibular ridges is always a difficult task especially in mandible because of the anatomical limitations. So there was a dire need to modify the conventional procedure of complete denture. Retaining a prosthesis in case of severely resorbed ridges often requires the selection and incorporation of various additional and appropriate methods for the fabrication of satisfactory complete denture prosthesis.

In this case, Admixed impression technique described by McCord and Tyson was used to record the mandibular secondary impression taking a viscous admix of impression compound and low fusion compound which remove any soft tissue fold and smoothest them over the mandibular bone. The advantage using this technique was that homogenous material allows to mould an impression of sufficient viscosity to obtain the definitive impression in single step as well at the same time also provide better consistency, requires less time and economical as compared to other impression materials⁵. This is

followed by the neutral zone mandibular impression in order to determine space within which denture could be seated without being subjected to excessive displacing forces from surrounding musculature and thus aid in denture stability. Maxillary neutral zone impression was not recorded as the effect of tongue size and position do not appear to have as profound an impact on the stability of a maxillary denture as compared to the mandibular denture

So modification in treatment procedure should always be considered as an innovative approach by prosthodontist to fulfill the patient functional and esthetic desires. Basically the success of any complete denture relied on the principle of retention, support and stability. Prosthodontics skill lies in all this principles efficiently in all critical situations.

Neutral zone mandibular impression was recorded in order to determine the space within which the denture could be seated without being subjected to excessive displacing forces from the surrounding musculature and thus aid in denture base stability. Admix impression technique described by McCord and Tyson was used to record the mandibular secondary impression^[9,13]. The philosophy was that a viscous admix of impression compound and tracing compound removes any soft tissue folds and smoothes them over the mandibular bone. This reduces the potential discomfort arising from the atrophic sandwich i.e. the creased mucosa lying between the denture base and mandibular bone.

Conclusion

Admix impression technique described by McCord and Tyson was used to record the mandibular secondary impression^[9,13]. The philosophy was that a viscous admix of impression compound and tracing compound removes any soft tissue folds and smoothes them over the mandibular bone. This reduces the potential discomfort arising from the atrophic sandwich i.e. the creased mucosa lying between the denture base and mandibular bone. The functional problems associated with patients having atrophic mandible other than instability, arises from the inability of the residual ridge and its underlying tissues to withstand masticatory forces. To record the functional position of the muscles, impression technique advocated by McCord and Tyson for atrophic mandibular ridges was used. Combination of impression compound with green stick is used in this technique for definitive impression, because this has better consistency, require less chair side time, and economical.

Admix impression technique described by McCord and Tyson was used to record the mandibular secondary impression^[9,13]. The philosophy was that a viscous admix of impression compound and tracing compound removes any soft tissue folds and smoothes them over the mandibular bone. This reduces the potential discomfort arising from the atrophic sandwich i.e. the

creased mucosa lying between the denture base and mandibular bone.

Complete denture fabrication using the techniques presented in the article is a simple effective, non-invasive and economic procedure which involves only one extra clinical step and improves the denture stability tremendously. So, being as a prosthodontist we should performed this procedure for all the complete denture resorbed ridge patients either solely or in conjunction with other procedures to improve the denture stability. The modified impression procedures was used to achieve effective retention, stability and support in atrophied ridges.

With advent in dental material science and innovation of newer techniques in prosthodontics, it has been made possible to successfully satisfy the esthetic and functional demands of the patients with severe residual ridge resorption. So, efforts has been taken to prevent further damage to patient's already vulnerable residual ridge condition.

References

1. Prasad K et al. Prosthodontic management of compromised ridges and situations. *Int J Health Allied Sci*20144(1),ISSN:2249-7110.
2. Rao. L et al. Prosthodontic rehabilitation of mandibular resorbed ridgea different approach. *J Am Dent Assoc* 2010;2(3);July – Sept.
3. Herekar M et al. A Physiologic Impression Technique for Resorbed Mandibular Ridges. *J Prosthodont* 2013;2(2):80-82.
4. Sivach A et al. Innovating the art of final impression making in restricted oral opening through the use of a sectional impression technique *Br Dent J*;2003;4(2):55-59.
5. Surya R et al. Dual wash impression technique of recording impression for resorbed mandibular edentulous ridges. *Br Dent J*;20152(2):1-52.
6. Gupta S et al. Salvation of a severely resorbed mandibular ridge with a neutral zone technique *J Prosthet Dent*;2011;2(6):883-889.
7. Manoj S et al. Management of Compromised Ridges: A Case Report. *J Indian Prosthodont Soc*;2011 Jun;11(2):125–129.
8. Praveen G et al. Cocktail Impression Technique: A New Approach to Atwood's Order VI Mandibular Ridge Deformity. *J Indian Prosthodont Soc*; 2011 Mar;11(1):32–35.
9. Malachia SA et al. Modified Functional Impression Technique for Complete Denture *Braz Dent J*;2005;16(2):135-139.