

Content available at: <https://www.ipinnovative.com/open-access-journals>

International Journal of Oral Health Dentistry

Journal homepage: [www.ijohd.org](http://www.ijohd.org)

## Original Research Article

## Determination of sexual dimorphism using lateral cephalogram: A forensic study

Pritesh Ruparelia<sup>1</sup>, Oshin Verma<sup>1\*</sup>, Navneet Gill<sup>1</sup>, Kosha Ruparelia<sup>2</sup>,  
Prerna Chandra<sup>3</sup>, Setu P Shah<sup>4</sup><sup>1</sup>Dept. of Oral Medicine and Radiology, College of Dental Sciences and Research Centre, Gujarat University, Gujarat, India<sup>2</sup>Dept. of Oral Medicine and Radiology, AMC Dental College and Hospital, Gujarat University, Gujarat, India<sup>3</sup>Dept. of Anatomy, All India Institute of Medical Sciences, Gorakhpur, Uttar Pradesh, India<sup>4</sup>Dept of Oral and Maxillofacial Surgery, College of Dental Sciences and Research Centre, Gujarat University, Gujarat, India

## ARTICLE INFO

## Article history:

Received 29-06-2024

Accepted 31-08-2024

Available online 10-10-2024

## Keywords:

Gender identification

Maxillary sinus area

Maxillary sinus perimeter

## ABSTRACT

**Introduction:** Physical anthropologists and anatomists developed the branch of anthropometry known as craniometry or cephalometry. The lateral cephalogram are simple and reliable tools which can be routinely used for the forensic and anthropological purposes and it is ideal for the skull examination as it gives details of various anatomical points in a single radiograph. Accurate determination of sex and stature from human skull is of great importance in forensic investigations.

**Aim and Objective:** The purpose of this study is to check the accuracy and reliability of maxillary sinus morphometric parameters in gender determination by using lateral cephalogram. The objectives of the present study are to (i) assess the area and perimeter of maxillary sinus on lateral cephalogram of male and female patients, (ii) determine gender based on the area and perimeter of maxillary sinus on lateral cephalogram.

**Materials and Methods:** Lateral cephalograms of 510 participants with equal gender distribution i.e. 255 males and 255 females were obtained from the archives of data library. Then, the area and perimeter of maxillary sinus was measured using Auto CAD. The means of both area and perimeter of maxillary sinus were compared and statistically evaluated for gender determination by applying discriminant functional analysis and calculating technical error of measurement and coefficient of reliability.

**Results:** The mean area for male maxillary sinuses in the present study was 531.6276mm<sup>2</sup> whereas the mean area for female maxillary sinuses was 422.7012mm<sup>2</sup>. The mean perimeter of maxillary sinuses in males was 91.0837mm whereas in females it was 82.2952mm.

**Conclusion:** The dimensions of maxillary sinus in males were found to significantly greater compared to females which shows that parameters such as area and perimeter of maxillary sinuses are reliable to be used in forensic dentistry for identification purposes.

This is an Open Access (OA) journal, and articles are distributed under the terms of the [Creative Commons Attribution-NonCommercial-ShareAlike 4.0 License](https://creativecommons.org/licenses/by-nc-sa/4.0/), which allows others to remix, tweak, and build upon the work non-commercially, as long as appropriate credit is given and the new creations are licensed under the identical terms.

For reprints contact: [reprint@ipinnovative.com](mailto:reprint@ipinnovative.com)

## 1. Introduction

In forensic and physical anthropological discipline, skeletal elements play an important role in sex determination.<sup>1</sup> The bodies of victims of violent crimes, fires, motor vehicle accidents and work place accidents, can be disfigured to

such an extent that identification by a family member is neither reliable nor desirable.<sup>2</sup> Identification of corpses is an arduous process, mandated by social rules and for various legal reasons.<sup>3</sup> The distinctiveness of anatomical structures and their normal anatomic variations provides the basis for forensic identification, when the corpses are unidentifiable.<sup>4</sup> Sexual dimorphism is one of its integral

\* Corresponding author.

E-mail address: [oshinaqua31@gmail.com](mailto:oshinaqua31@gmail.com) (O. Verma).

aspects as it is one of the initial steps in personal identification of an unknown cadaver thus narrowing down the diagnosis toward a correct possibility.<sup>5</sup> There are various other methods available, such as visual inspection, anatomic morphometric analysis, matching post-natal and ante-natal data, fingerprint analysis, DNA matching, precise measurement of bone dimensions and other techniques, which often exceed radiologic contributions, however, in situations where the soft tissue components are decomposed or burnt, finger-print analysis and DNA identification are rendered unavailing. In such cases, radiography plays a vital role in identification.<sup>3,4</sup>

Maxillary sinuses are damage resistant, even when the skull is desecrated in victims who are incinerated, in which situation only denser bones like maxilla are recovered, which encompass maxillary sinuses, which can be used for identification.<sup>6</sup> Maxillary sinuses usually stabilize after the second decade of life, when all the maxillary permanent teeth have erupted and the radiographic images could provide reliable measurements of maxillary sinuses to be applied in forensic sciences for gender determination that cannot be approached by other means.<sup>5</sup>

Today, lateral cephalograms are being routinely performed for varied reasons in dentistry, thereby ensuring their increasing availability in cases requiring personal identification. In addition, the cheaper cost involved, makes it more practical for use, in a developing country like India, which consecutively has led to increased use of lateral cephalograms for forensic identification.

However, literature shows a few discrepancies in dimensions of maxillary sinus in males and females. Therefore, the present study was conducted to determine the reliability and accuracy of maxillary sinus area and perimeter for gender identification using morphometric analysis.

## 2. Materials and Methods

A sample size of 510 was calculated using the equation  $N = [(Z^2) \cdot (P) \cdot (1-P)] / (C^2)$ , of which 255 were males and 255 were females, of age 20 years and above, who were selected randomly within a period of one year. The lateral cephalometric radiographs were collected from the data library in the department of oral medicine and radiology. Anamnestic and clinical information for each subject was obtained from the patient's files. All patients of age 20 years and above, were included in the study. Any patient with a history of any systemic illness, developmental disturbances, history of facial trauma, orthodontic/orthognathic treatments or surgeries were excluded from the study.

Lateral Cephalograms were acquired by using standard techniques with Carestream Digital Panoramic and Cephalometric device (CS8000C). Tracing was done by importing each lateral cephalograms in AutoCAD software

(Autodesk, Inc.). The imported image was enlarged sufficiently for ease of tracing without affecting the outcome. Unit of measurement used was mm. The borders of maxillary sinus that appeared as the thin radiopaque line were traced by using tools for area and perimeter in software to get readings. (Figure 1) Readings obtained for the area were in "mm<sup>2</sup>" and for perimeter were in "mm" and were recorded in the proforma. The radiographs were traced by two observers, twice, at an interval of 6 months, to rule out inter- and intra-observer variation in readings.

The readings were analyzed and the statistical procedure was carried out in two steps, data compilation and statistical analysis. The data obtained was entered into an Excel spread sheet and the master chart was prepared. The total data was presented pertinently as tables and charts. If the p-value was less than 0.05, the difference between the Means was considered statistically significant. Moreover, to find out whether area and perimeter of maxillary sinus can discriminate the gender of the skull, the widely used statistical test Discriminant Functional Analysis was applied, which displays the proportion of patients correctly and wrongly classified as males and females.

For assessing the reliability of data measurement two independent observers measured the data at two different points of time, 6 months apart. Again Mean and S.D were calculated for all readings to compare for Intra and Inter- observer variability. But Mean and absolute mean does not give a valid variability since if the difference of the individual patient values are both in negative and positive difference these will nullify each other and the Mean difference shall be nearer to zero, but actual variability may be high. Thus calculation of Mean difference can be misleading and not valid. Therefore, the Technical error of measurement and coefficient of reliability has been calculated to assess the intra and inter- observer variability.

A statistical test of significance can be applied to see whether intra and inter- observer variability is high or low only when there are existing clinical expected limits of error or an expert who measures the data with the assumption that what he has measured is accurate data. This may not be possible in this study and hence Limits of agreement (LA) have been calculated for Intra-observer variability between the readings of two observers and Inter- observer variability between the first readings of the two observers. The LA has been plotted using Bland-Altman (XY) plots for intra and inter-observer variability in measurement. The Limits of agreement are Mean + 1.96 S.D of the difference of two readings.

## 3. Results

Table 1 depicts the distribution of total number of participants according to age and gender.

From Table 2, it is evident that males have higher mean values for area and perimeter of the maxillary sinus than

females. Higher t-values and low p-values suggest that our sample provides enough evidence that we can reject the null hypothesis. P value < 0.001 suggests comparison of descriptive statistics of gender wise area and perimeter of the maxillary sinus on lateral cephalogram is highly significant and supports our research hypothesis.

Table 3 depicts that the discriminant function analysis resulted in 79.8% of original group cases classified correctly based on the area of maxillary sinus and 74.1% of original group cases classified correctly based on the perimeter of maxillary sinus.

Table 4 shows the mean and absolute mean difference in area and perimeter for intra- and inter-observer reliability.

Table 5 shows intra- and inter-observer technical error of measurement and coefficient of reliability for area and perimeter of maxillary sinus.

Graph 1 is a scatter plot XY where X-axis represent average of two readings for area (mm<sup>2</sup>) by observer 1 and 2 and Y-axis shows intra-observer variability in area. Only 30 (5.8%) values are beyond LA and other values are within 94.2% of LA. Thus there is no major inter-observer error.

Graph 2 is a scatter plot XY where, X-axis represent average of two readings for perimeter (mm) by observer 1 & observer 2 and Y-axis inter-observer variability in perimeter. Only 25 (4.9%) values are beyond LA and other values are within 94.2% of LA. Thus there is no major inter-observer error.

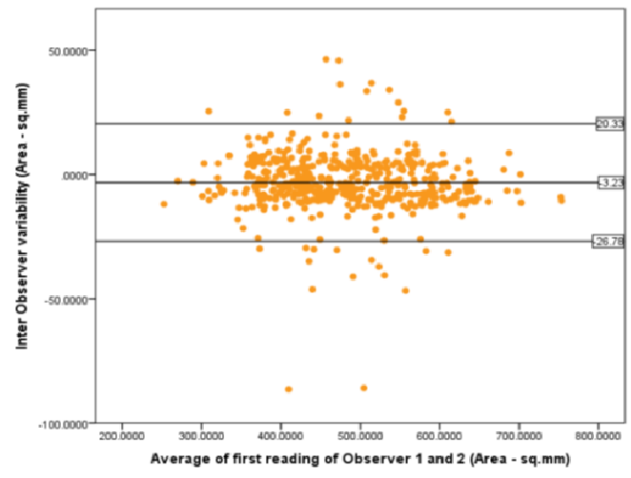
**Table 1:** Distribution of total number of participants according to age and gender

Age (years)	Male	Female	Total
18-25	233 (45.68%)	236 (46.27%)	469 (91.96%)
26-35	16 (3.13%)	14 (2.74%)	30 (5.88%)
36-45	6 (1.17%)	5 (0.98%)	11 (2.15%)
Total	255 (50%)	255 (50%)	510 (100%)

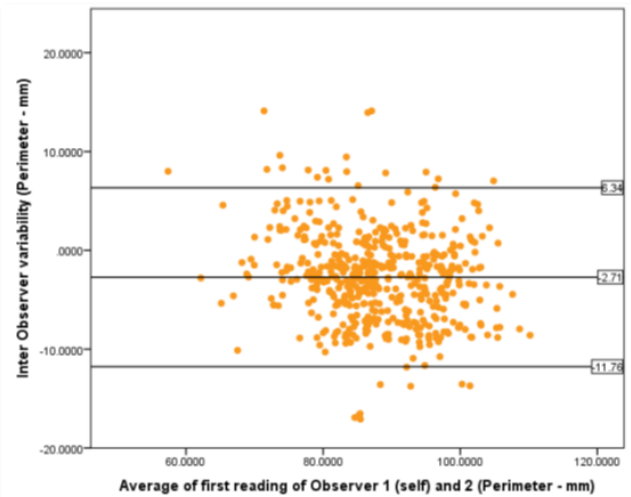
**4. Discussion**

In a recent study conducted by Deshpande AA et al.,(2022)<sup>7</sup>, statistically significant differences were found between the height and length of the maxillary sinus amongst male and female gender, with an accuracy rate of 71.3%, which shows that maxillary sinus height is a reliable radiographic parameter in forensic odontology for gender determination.<sup>7</sup>

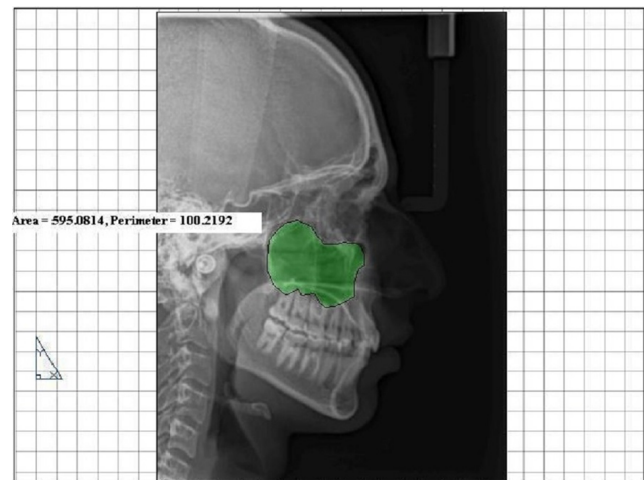
Moreover, in the study conducted by Netharaa A et al.,(2020),<sup>8</sup> they assessed the dimensions of maxillary and frontal air sinuses and correlated with age and gender. Their results showed that the average area of frontal sinus was greater in males than in females, whereas, the distance across the maxillary sinus was greater in females compared to males.<sup>8</sup> Furthermore, in a study conducted by Mathew A



Graph 1: Bland-Altman plot for inter-observer limit of agreement (LA) for area of maxillary sinus



Graph 2: Bland-Altman plot for inter-observer limit of agreement (LA) for perimeter of maxillary sinus



**Figure 1:** Tracing of maxillary sinus in Auto CAD software

**Table 2:** Gender-wise comparison of descriptive statistics for area and perimeter of maxillary sinus on lateral cephalograms

Maxillary sinus parameter	N	Mean	Standard deviation	Standard error of mean	t-value	df	p-value
Area (mm <sup>2</sup> ) in males	255	531.628	75.178	4.708	17.932	508	0.000*
Area (mm <sup>2</sup> ) in females	255	422.701	61.298	3.389			
Perimeter (mm) in males	255	91.084	7.212	0.452	13.699	508	0.000*
Perimeter (mm) in females	255	82.295	7.276	0.456			

N = Number of Participants; SD = Standard Deviation; df = Discriminant Function

**Table 3:** Discriminant functional analysis on the basis of area and perimeter of maxillary sinus

Classification results <sup>a</sup>					
Maxillary sinus parameter		Gender	Predicted group membership		Total
			1 Male	2 Females	
Area	Original count	Male	198	57	255
		Female	46	209	255
	Percentage	Male	77.6	22.4	100
		Female	18.0	82.0	100
a. 79.8% of original grouped cases were correctly classified					
Perimeter	Original count	Male	185	70	255
		Female	62	193	255
	Percentage	Male	72.5	27.5	100
		Female	24.3	75.7	100
a. 74.1% of original grouped cases were correctly classified					

**Table 4:** Mean and absolute mean difference in area and perimeter for intra- and inter-observer reliability

Maxillary sinus parameter	Summary statistics	Observer 1		Observer 2		Absolute mean difference		
		Time 1 (A)	Time 2 (B)	Time 1 (C)	Time 2 (D)	Intra-observer 1 (A & B)	Intra-observer 2 (C & D)	Inter-observer (A & C)
Area	N	510	510	510	510			
	Mean ± S.D	477.16	478.64	480.39	480.58	-1.48	-0.19	-3.23
Perimeter	N	510	510	510	510			
	Mean ± S.D	86.69	88.69	89.40	90.03	-2.00	-0.63	-2.71

N = Number of participants; SD = Standard deviation

**Table 5:** Intra- and inter-observer technical error of measurement and coefficient of reliability for area and perimeter of maxillary sinus

Maxillary sinus parameter	Measurement	TEM (mm)	Coefficient of reliability (%)
Area (mm <sup>2</sup> )	Intra-observer 1	4.583	74.4
	Intra-observer 2	5.640	75.0
	Inter-observer	6.216	73.2
Perimeter (mm)	Intra-observer 1	2.208	68.6
	Intra-observer 2	1.826	74.3
	Inter-observer	2.675	66.4

TEM = Technical error of measurement, mm<sup>2</sup> = square millimeters, mm = millimeter

et al.,(2020)<sup>9</sup> they used Cone Beam Computed Tomography to assess morphometric measurements of maxillary sinus and reported that all the values of the maxillary sinus dimensions were significantly greater in males as compared to females except the inter-maxillary distance, which was more in females compared to males.<sup>9</sup>

In contrast to the abovementioned studies, a study conducted out by Kumar P et al.,(2018)<sup>10</sup> and Khaitan T et al.(2017)<sup>11</sup> reported that all the parameters of maxillary sinus for males were greater than females.<sup>10,11</sup>

Evidence based on forensic science is required in a judicial environment and plays an important role in identifying individuals whose bodies are mutilated and cannot be recognized visually. The primary methods of identification recognized by the International Criminal Police Organization (INTERPOL) are fingerprint analysis, DNA and forensic odontology.<sup>12</sup> Gender determination is the most crucial and the most challenging step in mass disasters where the information relating to the deceased is unavailable. Gender determination is pivotal for further analysis in mishaps such as chemical and nuclear bomb explosions, natural disasters, crime investigations and ethnic studies.<sup>13</sup> Determination of sex using fragments of skeletal remains presents a great problem to forensic experts, due to major mass disaster.<sup>14</sup> However, the maxillary sinuses have been recorded to survive complete burns, even while the skull and surrounding bones are badly damaged. Sinuses in the maxilla can be used as a biometric for human identity.<sup>15</sup>

Forensic science is dependent significantly on imaging methodology and lateral cephalograms play a cardinal role in gender determination by providing architectural and morphological details of the skull, thereby divulging multiple points for comparison amongst gender. Various researchers have reported this conventional radiograph to be a cost effective, easily available and reliable in providing accuracy of 80–100%.<sup>11</sup>

The present study demonstrates that the maximum numbers of participants were in the age group of 18-25 years, both males and females. This could be explained by the fact that the subjects with missing teeth were excluded from the study and hence relatively younger age group subjects who were completely dentate were greater in number (Table 1).

In our study, we found that the mean area and perimeter were more in males (area = 531.628 mm<sup>2</sup>, perimeter = 91.084 mm), when compared to females (area = 422.701 mm<sup>2</sup>, perimeter = 82.295 mm) (Table 2). These findings are in accordance with the study conducted by Kim GR, who assessed the sizes of paranasal sinuses on postero-anterior and lateral cephalometric views and concluded that the size of paranasal sinuses is greater in men, compared to women.<sup>16</sup> Similarly, Fernandes et al. conducted a study on dried skulls on 53 subjects for estimation of sinus volume on helical, multislice CT and found gender variations in the

different groups. They found that males had larger volumes than females.<sup>17</sup> However, our results are not compatible with those of Endo et al., who reported that the maxillary sinus size showed no significant differences between sexes. This could be explained by the fact that they conducted their lateral cephalometric study in young patients (aged 12 to 16 years) with Angle's malocclusion, while such subjects were excluded from our study.<sup>18</sup>

In our study, we used the discriminant functional analysis to classify 510 subjects into two sexual groups, created from two variables, area and perimeter of the maxillary sinus (Table 4). The accuracy of discriminant analysis for gender prediction using area was 79.8% and using perimeter was 74.1%. Thus, based on the results of our study, using area of the sinus as a gender predictor, yields more accurate results. Our results were in accordance with those of Sidhu et al., whose discriminant functional analysis showed that, 76% of the original grouped cases were classified correctly.<sup>3</sup> However, they did not explain the scores for area and perimeter, separately, failing to elaborate which out of the two parameters (area and perimeter) was a better discriminant function for gender identification. Moreover, similar to our results, Uthman et al. also found that the maxillary sinus height was the most reliable discriminant parameter that could reflect sexual dimorphism with an overall accuracy of 71.6%, where 74.4% of male sinuses and 73.3% of female sinuses were sexed correctly.<sup>19</sup> In accordance to our results, Fernandes et al. found that the discriminant analysis allowed for 79% gender prediction by estimating sinus volume, on dried skulls of 53 subjects using helical, multi-slice CT.<sup>17</sup> Interestingly, in their study, even using the volume as a discriminant function, yielded an accuracy of 79%, which was similar to the accuracy obtained by using the area (79.8%) as a DF in our study.

hows intra- and inter-observer technical error of measurement and coefficient of reliability for area and perimeter of maxillary sinus, where it shows good agreement for both area and perimeter of maxillary sinus. This is similar to the intra-rater reliability assessed by Kumar P et al., for assessment of maxillary sinus in gender determination – A CBCT study.<sup>10</sup> Similarly, a study conducted by Maspero C et al. also concluded that the intraobserver and interobserver reliability showed high agreement for all the variables.<sup>20</sup>

Graph 1 and Graph 2 depict the Bland-Altman analysis which shows that there is no major inter-observer error between readings of observer 1 and 2, for area and perimeter of maxillary sinus respectively. Similar to our findings, a study conducted by Kirmeier R et al., to assess the reproducibility of volumetric measurements on maxillary sinuses, also concluded that the Bland-Altman analysis demonstrated good intra- as well as inter-examiner agreement.<sup>21</sup> Moreover, Kumar P et al. assessed inter-rater reliability between 2 observers for morphometric

measurements of maxillary sinus and concluded that they have excellent reliability.<sup>10</sup>

While the results of this study, clearly establish that both area and perimeter of the maxillary sinus can be used for gender determination, there are however, some limitations. Using lateral cephalograms may have a drawback of the images being different from the actual size and the image boundaries of the maxillary sinus may be superimposed over adjacent structures in the deep regions of naso-maxillary complex and may not be determined precisely. It may be argued, that the difference in size between maxillary sinuses on the left and right sides has not been taken into account. Despite these limitations, the results of our study show that morphometric assessment of area and perimeter of the maxillary sinus on lateral cephalograms can prove useful for sex determination in forensic investigations. Further research on different populations may provide additional accurate standards with numerical values that may help in identifying the sex better and in solving many forensic cases.

## 5. Conclusion

Gender determination plays a key role in forensic evaluation. Maxillary sinus continues to pneumatize the maxillary alveolar process until all the permanent teeth erupt. Thus its dimensions stabilize after second decade of life, after which, the radiographic images could provide reliable measurements for maxillary sinuses that cannot be approached by other means. The present study shows that the maxillary sinus parameters like area and perimeter are reliable discriminant parameters that could be used for the purpose of gender discrimination, since area and perimeter were more in males when compared to females. Hence, the morphometric analysis of maxillary sinus parameters may be used for sex determination in forensic odontology, with good reliability.

## 6. Ethical Approval

The present study was conducted, after the approval from the institutional ethical committee (Ref. No.: CDS/IEC/52).

## 7. Conflict of Interest

None.

## 8. Source of Funding


None.

## References

1. Devang DD, John J, Kheraif A, Mavinapalla AA, Ramakrishnaiah S, Vellappally R, et al. Sex determination using discriminant function analysis in Indigenous (Kurubas) children and adolescents of Coorg, Karnataka, India: A lateral cephalometric study. *Saudi J Biol Sci.* 2016;23(6):782–8.
2. Pretty IA, Sweet D. A look at forensic dentistry-Part 1: The role of teeth in the determination of human identity. *Br Dent J.* 2001;190(7):359–66.
3. Sidhu R, Chandra S, Devi P, Taneja N, Sah K, Kaur N. Forensic importance of maxillary sinus in gender determination: A morphometric analysis from Western Uttar Pradesh, India. *Eur J Gen Dent.* 2014;3(1):53–6.
4. Patil N, Karjodkar FR, Sontakke S, Sansare K, Salvi R. Uniqueness of radiographic patterns of the frontal sinus for personal identification. *Imaging Sci Dent.* 2012;42(4):213–7.
5. Tambawala SS, Karjodkar FR, Sansare K, Prakash N. Sexual dimorphism of maxillary sinus using cone beam computed tomography. *Egyptian J Forensic Sci.* 2016;6(2):120–5.
6. Teke HY, Duran S, Canturk N, Canturk G. Determination of gender by measuring the size of the maxillary sinuses in computerised tomography scans. *Surg Radiol Anat.* 2007;29(1):9–13.
7. Deshpande AA, Munde AD, Mishra SS, Kawsankar KD, Sawade RV, Mandar B. Determination of sexual dimorphism of maxillary sinus using cone-beam computed tomography in a rural population of western Maharashtra - A retrospective, cross-sectional study. *J Family Med Prim Care.* 2022;11(4):1257–61.
8. Netharaa A, Ramani P, Sherlin HJ, Gheena S, Ramasubramanian A, Jayaraj G, et al. Frontal and Maxillary Air Sinus in Age Determination and Gender Identification. *J Res Med Dent Sci.* 2020;8(3):104–9.
9. Mathew A, Jacob LE, 32(4):384. 3D evaluation of maxillary sinus in gender determination: A cone beam computed tomography study. *J Indian Acad Oral Med Radiol.* 2020;32(4):384–9.
10. Kumar P, Pachipulusu B, Govindraju P. Assessment of maxillary sinus in gender determination - A CBCT study. *IP Int J Maxillofac Imaging.* 2018;4(2):42–7.
11. Khaitan T, Kabiraj A, Ginjupally U, Jain R. Cephalometric Analysis for Gender Determination Using Maxillary Sinus Index: A Novel Dimension in Personal Identification. *Int J Dent.* 2017;2017:7026796.
12. Rocha MFN, Pereira JGD, Silva RD. Sex estimation by maxillary sinus using computed tomography: a systematic review. *J Forensic Odontostomatol.* 2021;39(1):35–44.
13. Dar MS, Abbas R, Latoo H, Gupta S, S. Interzygomatic and Intercanthal width - Gender determination methods in forensic dentistry. *Int Arch Integr Med.* 2022;9(9):1–7.
14. Nagare SP, Chaudhari RS, Birangane RS, Parkarwar PC. Sex determination in forensic identification: A review. *J Forensic Dent Sci.* 2018;10(2):61–6.
15. Kukade J, Tivaskar S, Luharia A, Dhande R, Umate R. Role Of Conventional Radiology In Gender Determination: A Review Article. *J Pharm Negat Results.* 2022;13(8):59–64.
16. Kim GR. A morphological study of the paranasal sinuses in Koreans. *Yonsei Med J.* 1962;3(1):11.
17. Fernandes CL. Forensic ethnic identification of crania: The role of the maxillary sinus: A new approach. *Am J Forensic Med Pathol.* 2004;25(4):302–13.
18. Endo T, Abe R, Kuroki H, Kojima K, Oka K, Shimooka S. Cephalometric evaluation of maxillary sinus sizes in different malocclusion classes. *Odontology.* 2010;98(1):65–72.
19. Uthman AT, Al-Rawi NH, Al-Naaimi AS, Al-Timimi JF. Evaluation of maxillary sinus dimensions in gender determination using helical CT scanning. *J Forensic Sci.* 2011;56(2):403–8.
20. Maspero C, Farronato M, Bellincioni F, Annibale A, Machetti J, Abate A, et al. Three-Dimensional Evaluation of Maxillary Sinus Changes in Growing Subjects: A Retrospective Cross-Sectional Study. *Materials (Basel).* 2020;13(4):1007.
21. Kirmeier R, Arnetzl C, Robl T, Payer M, Lorenzoni M, Jakse N. Reproducibility of volumetric measurements on maxillary sinuses. *Int J Oral Maxillofac Surg.* 2011;40(2):195–9.

## Author biography

Pritesh Ruparelia, Professor and HOD

**Oshin Verma**, Reader and PhD Scholar  <https://orcid.org/0000-0003-1210-5208>

**Setu P Shah**, Professor

**Navneet Gill**, Professor and PG Guide

**Kosha Ruparelia**, Reader

**Prerna Chandra**, Assistant Professor

**Cite this article:** Ruparelia P, Verma O, Gill N, Ruparelia K, Chandra P, Shah SP. Determination of sexual dimorphism using lateral cephalogram: A forensic study. *Int J Oral Health Dent* 2024;10(3):209-215.