

Content available at: <https://www.ipinnovative.com/open-access-journals>

International Journal of Oral Health Dentistry

Journal homepage: [www.ijohd.org](http://www.ijohd.org)

## Original Research Article

## Root resorption of maxillary lateral incisors associated with maxillary impacted canines: Cone-beam computed tomography and panoramic radiography study

Zubeida Maalim<sup>1\*</sup>, Millicent Motsepe<sup>1</sup>, Shoayeb Shaik<sup>2</sup>,  
Ntombizodwa R Nkambule<sup>3</sup>

<sup>1</sup>Dept. of Orthodontics, School of Dentistry, Faculty of Health Sciences, University of Pretoria, Pretoria, South Africa

<sup>2</sup>Dept. of Maxillofacial Radiology, School of Dentistry, Faculty of Health Sciences, University of Pretoria, Pretoria, South Africa

<sup>3</sup>Dept. of Community Dentistry, School of Dentistry, Faculty of Health Sciences, University of Pretoria, Pretoria, South Africa



## ARTICLE INFO

## Article history:

Received 13-04-2024

Accepted 29-05-2024

Available online 11-06-2024

## Keywords:

CBCT

Impacted canine

Lateral incisor

Root resorption

## ABSTRACT

**Background:** The position of maxillary impacted canine (MIC) and the presence of lateral incisor root resorption (RR) remains a challenge for interceptive orthodontics and surgical treatment planning. The use of panoramic radiographs will be compared with CBCT in the diagnosis of RR and emphasize the importance of accurate diagnostic imaging.

**Purpose:** To compare the diagnostic accuracy of Cone Beam Computed Tomography and Panoramic Radiography in detecting lateral incisor RR associated with MIC. To evaluate, with respect to sector position of impacted canines, the agreement between panoramic radiographs and CBCT in detecting lateral incisor RR.

**Materials and Methods:** A cross-sectional retrospective descriptive study on panoramic and CBCT radiographic records between January 2014 and December 2020. The study setting was Section of Diagnostic Imaging at a University Oral Health Centre. All patients requiring radiographs are referred to this section by all dental departments of the dental hospital. The study sample consisted of CBCT and panoramic images of impacted maxillary canines of patients older than 9yrs. Patients with odontogenic and non-odontogenic pathology in the canine and incisor area, those with previous diagnosis of external root resorption verified from the patient's treatment records, and patients who have had any form of orthodontic treatment; removable or fixed appliances were excluded. Data was analysed using Statistical Package for the Social Sciences (SPSS) version 27. Pearson's chi-squared test was used to analyse the agreement between panoramic radiographs and CBCT in locating canine sector position. All tests were conducted at 5% significance level.

**Results:** Fifty patients records were analysed in our study. The median age of the sample was 15 years and the IQR was 12.5-19. Our sample consisted predominantly of females (n=40) compared to males(n=10). A total of 65 MIC were assessed with 16 bilateral impactions (n=32) and the unilateral impactions (n=33). Of the 65 MICs, 46% were located on the right side and 54% were located on the left side. The CBCT examination showed that 58% (n = 38) of MIC were located palatally, 34% (n=22) labially and 8% (n=5) in the mid-alveolus (between the teeth). The majority of MIC occurred in sector 4 in 2-D pan (26%, n=17) and 3-D pan at (32%, n=21). Pearson's chi-squared test results showed a statistically significant difference in the agreement between 2-D pan and 3-D pan in locating canine sector position (p=0.001).

**Conclusions and Clinical Significance:** The detection of root resorption in our study underscores the importance for clinicians to examine panoramic radiographs thoroughly beyond the counting of teeth. Although panoramic radiographs are the routine diagnostic tool in contemporary dental practice, their limitation in definitive diagnosis of root resorption should be augmented with the use of CBCT.

This is an Open Access (OA) journal, and articles are distributed under the terms of the [Creative Commons Attribution-NonCommercial-ShareAlike 4.0 License](https://creativecommons.org/licenses/by-nc-sa/4.0/), which allows others to remix, tweak, and build upon the work non-commercially, as long as appropriate credit is given and the new creations are licensed under the identical terms.

For reprints contact: [reprint@ipinnovative.com](mailto:reprint@ipinnovative.com)

## 1. Introduction

Canines play a pivotal role in dentition; in the maxilla, they are referred to as the ‘cornerstone’ of the maxillary arch. In addition to their role in arch development and functional occlusion, they play a vital role in facial appearance by supporting both the alar base and upper lip.<sup>1</sup> However, during their eruption, maxillary canines may fail to descend to their respective positions within the dental arch and become impacted either facial or palatal of the dental arch.<sup>2</sup> Canines are the second most impacted teeth after the third molars with a prevalence that ranges from 0.9% to 3.0%, depending on the population examined.<sup>2–4</sup> Impaction of maxillary canines (85.2%) is more prevalent than mandibular canine impaction (8.8%); the least common is two arches involvement (6%).<sup>5</sup>

The most frequent adverse effect of canine impaction is root resorption (RR) of the maxillary lateral incisor.<sup>2</sup> RR is defined as non-infectious, irreversible damage related to the loss of cementum and dentine of the teeth in the vicinity of an impacted canine.<sup>6</sup> In many cases, lateral incisor root resorption may be radiographically diagnosed at an early stage but it is often not associated with pain, and may rapidly progress to devitalize a tooth and reduce its longevity. The most commonly affected tooth by RR is the maxillary lateral incisor.<sup>2</sup> Furthermore, the central incisor may be affected, and occasionally, resorption of premolars has been reported.<sup>4,7</sup>

When RR is clinically diagnosed at an advanced stage, it makes treatment difficult and may lead to extraction of the affected tooth. A study done by Alqerban et al.<sup>8</sup> reviewing lateral incisor RR induced by maxillary impacted canine (MIC) stated that timely diagnosis may reduce the severity and complications associated with RR. Early detection and prevention are considered to decrease the need for canine exposure and simplify orthodontic treatment.<sup>9</sup>

In general, the diagnosis of MIC is based on the analysis of periapical and/or panoramic radiographs, despite the limitation of representing a three-dimensional object in a two-dimensional image.<sup>10</sup> Drawbacks, such as image distortion, magnification, artifacts, blurred images, or structural superimposition have been associated with 2-D pan.<sup>11</sup> Cone beam computed tomography (CBCT) has become the modality of choice for detecting RR associated with MIC.<sup>12</sup> CBCT improves the localization of impacted teeth, identifies relevant pathology and has a high reliability in detecting RR by eliminating overlap of dental structures.<sup>13,14</sup>

Numerous studies in the literature regarding MIC looked at location, angulation, follicle size, association with root resorption, and treatment predictors.<sup>15–18</sup> Ericson and Kuroi<sup>18</sup> reported a higher success rate when the tip of the unerupted canine did not pass more than half the root of

the lateral incisor. Fifty percent increase in RR has been associated with an increased canine angulation to the mid-sagittal plane of greater than 25 degrees on a 2-D pan.<sup>18,19</sup> However, other studies reported that canine angulation added little predictive value.<sup>20,21</sup>

## 2. Materials and Methods

A retrospective cross-sectional study of 65 impacted canines records was conducted of patients that were consulted at a South African Dental Hospital, Department of Orthodontics, from 1 January 2014 to 31 December 2020.

Inclusion criteria for the study were records of patients older than 9 years, a diagnostically acceptable 2-D pan and CBCT with adequate diagnostic quality (free of motion blurring and minimal artifact), and patients with a full complement of maxillary central and lateral incisors. The exclusion criteria: patients with odontogenic and non-odontogenic pathology in the canine and incisor area, previous diagnosis of external root resorption verified from the patient’s treatment records, previous orthodontic treatment with removable or fixed appliances.

The digital 2-D pan images were obtained from Sirona Orthophos XG<sup>®</sup> and were analysed on the Sidexis<sup>®</sup> software. The CBCT images were taken with a Planmeca<sup>®</sup> ProMax3DMax (Helsinki, Finland) and were analysed on the Planmeca<sup>®</sup> Romexis<sup>®</sup> software. The images were evaluated in a room with low ambient light. The contrast and brightness of the images were enhanced using the tools available in the Sidexis<sup>®</sup> and Romexis<sup>®</sup> software. The computer monitor used was a 24-inch LG<sup>®</sup> high definition with a resolution of 1920\*1080. Eight consecutive images were assessed per day.

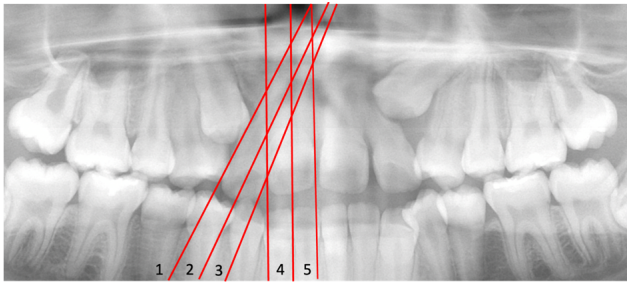
The data was collected by the principal investigator (PI) for each 2-D pan, reconstructed 3-D pan and CBCT images which included: the side of impaction (left or right), type of impaction (unilateral or bilateral), position of impaction (buccal / palatal / mid-alveolus), sector location evaluated on 2-D pan and 3-D pan, teeth affected by RR (central incisor/ lateral incisor/ premolar) and the severity of root resorption.

Figure 1 shows sector lines drawn to determine canine cusp location on a 2-D pan and 3-D pan as described by Ericson and Kuroi.<sup>18</sup> In cases where the sector line fell on the border of two sectors, the sector closer to the midline was chosen. Undetermined sector location was noted in instances where the sector could not be identified because the canines were positioned horizontally or parallel to the occlusal plane.

The 3D module software (Romexis<sup>®</sup>) was used to assess the static cross-sectional reformatted CBCT. The impacted canine and the adjacent teeth were evaluated in the three orthogonal planes using a slice thickness of 0.4mm. Where necessary, the slice thickness was adjusted to 5, 10, or 15 mm to assess any teeth that were not visible in 0.4

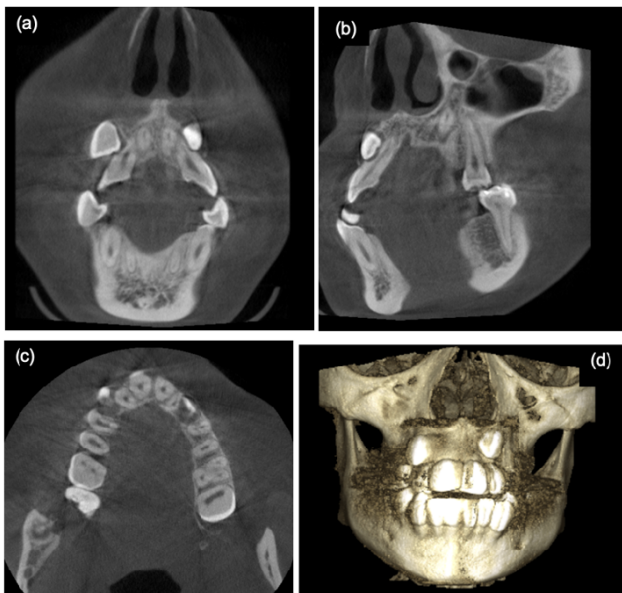
\* Corresponding author.

E-mail address: drzmaalim@gmail.com (Z. Maalim).

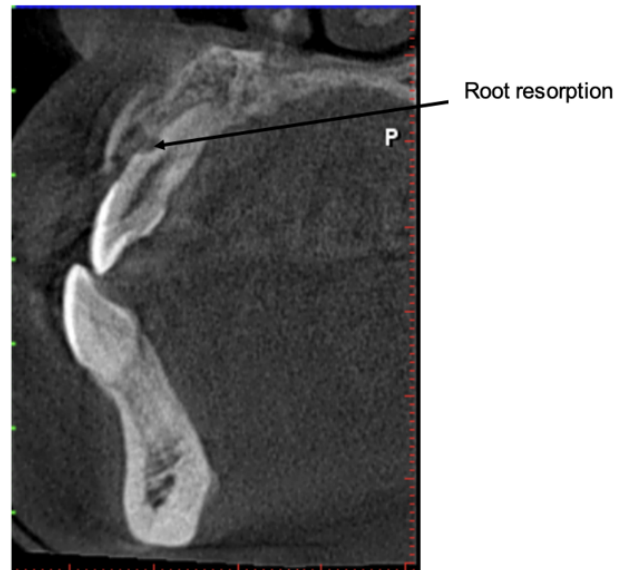

**Figure 1:** 2-D Panoramic radiograph showing sector lines Sector 1- area distal to a line tangent to the distal surface of the lateral incisors, Sector 2- area mesial to sector 1 but distal to a line passing through the long axis of the lateral incisor, Sector 3- area mesial to sector 2 but distal to a line tangent to the distal surface of the central incisor, Sector 4- area mesial to sector 3 but distal to a line passing through the long axis of the central incisor, Sector 5- area mesial to sector 4 but distal to a line passing through the midline between the two central incisors

mm thickness. Both the coronal and axial coordinates were aligned to pass through the middle of the face with the anterior nasal spine as a guide. The crosshair was maneuvered to locate the impacted canine which was determined to either being buccal, mid-alveolus, or palatal (Figure 2).



**Figure 2:** CBCT views of the impacted right and left maxillary canines; (a) Coronal view- showing position of impacted maxillary right and left canines and their association with upper right and left lateral incisor roots respectively, (b) Sagittal view- showing impacted maxillary right canine causing root resorption of the lateral incisor root, (c) Axial view- showing bilateral maxillary canine impaction and (d) Volume rendering showing 3- dimensional frontal representation of the patient illustrating labially impacted maxillary canines



**Figure 3:** CBCT Sagittal view illustrating slight root resorption of maxillary left lateral incisor

The CBCT images were adjusted to be parallel to the long axis of the lateral incisor tooth (oblique slice) to identify the presence or absence of RR (Figure 3). Loss of continuity of the root surface was recorded as RR. The degree of RR was graded according to Ericson and Kuroi<sup>21</sup> : 1- No resorption (intact root surface), 2- Slight resorption (up to half the dentine thickness to the pulp), 3- Moderate resorption (resorption of the dentine midway to the pulp or more), 4- Severe resorption that exposes the pulp. For every lateral incisor RR on CBCT, sector location of corresponding MIC was determined on 2-D pan.

**2.1. Reliability**

To calculate the intra-examiner and inter-examiner reliability of the measurements, the Kappa test was used. The reliability was assessed for sector location and RR using the Kappa test on ten cases chosen randomly from the sample. The assessment was done two weeks after the initial data collection. Analysis of the results were expressed as: <50% = poor; 50% - 59% = moderate; 60% - 69% = good and 70% - 100% = excellent. Interrater reliability for sector evaluation on panoramic radiographs was ‘good’ at both intervals. Interrater 2-D pan evaluation for RR was ‘excellent’ and intra-rater reliability for both sector and RR on 2-D pan and CBCT was ‘excellent’ (81%).

**2.2. Statistical analysis**

The data was analysed using Statistical Package for Social Sciences (SPSS) version 28. The correlation between sector location in the 2-D pan and 3-D pan was done using

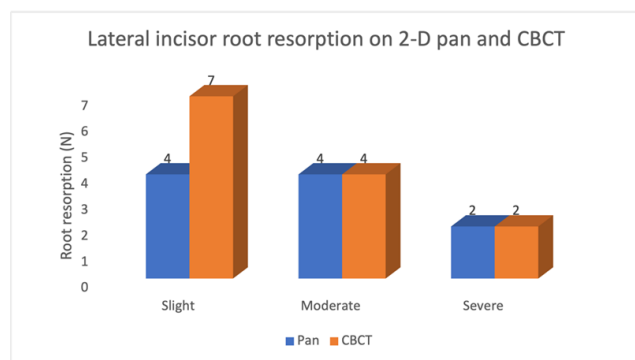
Pearson's test. The correlation between sector location in the 2-D pan and RR on CBCT images was performed using the chi-squared test. All tests were conducted at 5% significance level.

### 3. Results

Fifty patients records were analysed in our study. The median age of the sample was 15 years and the IQR was 12.5-19. Our sample consisted predominantly of females (n=40) compared to males (n=10). There were 16 bilateral impactions (n=32) and the unilateral impactions (n=33), a total of 65 MIC were assessed. Of the 65 MICs, 46% were located on the right side and 54% were located on the left side. The CBCT examination showed that 58% (n = 38) of MIC were located palatally, 34% (n=22) labially and 8% (n=5) in the mid-alveolus (between the teeth).

Table 1 shows the agreement of sector location between 2-D and 3-D pan in detecting lateral incisor root resorption. The majority of MIC occurred in sector 4 in 2-D pan (26%, n=17) and 3-D pan at (32%, n=21). Pearson's chi-squared test results showed a statistically significant difference in the agreement between 2-D pan and 3-D pan in locating canine sector position ( $p=0.001$ ).

Of the 65 MIC assessed, CBCT detected RR in 13 lateral incisors and 2 central incisors as compared to 10 lateral incisors, 2 central incisors and 1 premolar detected on 2-D pan (Figure 4). Seven lateral incisors out of the 13 detected by CBCT presented with slight RR in contrast to 2-D pan which detected four lateral incisors with slight RR. Severe RR was however equally detected by both 2-D pan and CBCT II compares sector position of MIC, identified on a 2-D pan and the presence of lateral incisor RR identified on CBCT. RR identified on CBCT was in sectors 5 and 4 (3/13) of the 2-D pan. The results showed that there was no statistical significant association between sector position on 2-D pan and the presence of RR on CBCT.



**Figure 4:** Degree of root resorption on 2-D pan and CBCT

### 4. Discussion

The prevalence of maxillary impacted canines has been reported to vary within a range of 0.9% to 3.0% and a higher prevalence in females.<sup>11,22</sup> Similarly, our study sample predominantly consisted of female subjects but since we used a convenient sample the gender difference should be interpreted with caution. Walker and Enciso<sup>4</sup> speculated that the female predominance could be attributed to gender differences in craniofacial growth and development. Another possible reason reported was that females seek orthodontic treatment more frequently than males.<sup>4,23</sup>

The results of our study show that the palatally MIC (58%) were more common than the labial (34%) and the mid-alveolus (8%) impactions. Similarly, Walker and Enciso<sup>4</sup> reported a high frequency (92.6%) of the palatal impactions and lower frequency (8%) of the labial impactions in their study sample. In contrast to our findings, Almuhtaseb et al.<sup>24</sup> in their study sample of 46 subjects reported a higher frequency (40%) of facially impacted maxillary canines followed by palatal impactions (37.6%). However, they found mid-alveolus impaction to be the least common (22.2%) similar to our findings. Proper localization of MIC plays an important role in its management. It can help to identify the tooth displacement to prevent further impaction. It also aids in determining the adverse effect of MIC on adjacent teeth such as the presence of root resorption. Moreover, during orthodontic treatment, accurate diagnosis improves the feasibility as well as the proper access to the surgical approach and the proper direction for the application of orthodontic force.

Ericson and Kuroi<sup>18</sup> observed that, the prediction of canine impaction was determined by the sector location of the cusp tip of the erupting canine for example, the more mesial the cusp tip location, the greater the likelihood of impaction. Warford et al.<sup>20</sup> reported that 48.6% of impacted canines were found in sectors 3, 4, and 5 in contrast with Ngo et al.<sup>9</sup> who showed a higher percentage of 63.6% of impacted canine positioning in sectors 3, 4, and 5. Our study found the majority of MIC located in sectors 4 and 3 (25%) and sector 2 (20%). A statistically significant difference was found between 2-D pan and 3-D pan in sector location of impacted canines.

Root resorption of the adjacent dentition is a common sequela of MIC and most challenging to treat. It may rapidly progress to devitalize a tooth and reduce its longevity; a reason why its diagnosis remains a challenge. Immediate therapeutic measures often are needed to avoid worsening of the situation and subsequent prolonged and expensive orthodontic treatment.<sup>22</sup> Conventional radiography as 2-D imaging shows false negative results in 51.9% of cases and false positive results in 15.3% of cases.<sup>23</sup> As a result, previous studies revealed that lesions less than 0.3 mm in depth and 0.6 mm in diameter were not detectable by 2-D radiography as they detect the lesions after occurrence

**Table 1:** Sector location of maxillary impacted canine in 2-D and 3-D pan

3-D Pan Sector Number	2-D Pan Sector Number							P-value
	Sector 1	Sector 2	Sector 3	Sector 4	Sector 5	Undetermined	Total	
Sector 1	1(1.5%)	1(1.5%)	1(1.5%)	0(0.0%)	0(0.0%)	0 (0%)	3 (5%)	0.001
Sector 2	1(1.5%)	5(8%)	4(6%)	0(0%)	1(1.5%)	1(1.5%)	12(19%)	
Sector 3	2(3.1%)	4(6%)	6(9%)	5(7%)	3(5%)	0(0%)	20(31%)	
Sector 4	0(0.0%)	2(3%)	5(8%)	12(19)	2(3%)	0(0%)	21(32%)	
Sector 5	0(0.0%)	0(0.0%)	0(0%)	0(0%)	5(7.7%)	0(0%)	5(8%)	
Undetermined	1(1.5%)	1(1.5%)	0(0%)	0(0%)	0(0.0%)	2(3%)	4(6%)	
Total	5(8%)	13(20%)	16(25%)	17(26%)	11(17%)	3(5%)	65(100%)	

**Table 2:** Comparison of root resorption on CBCT and sector position on 2-D pan

2-D Pan Sector Number	Root Resorption (CBCT) P-value				
	Mild	Moderate	Severe	Total	
Sector 1	2/13	0	0	2/13	0.291
Sector 2	0	1/13	1/13	2/13	
Sector 3	0	1/13	1/13	2/13	
Sector 4	2/13	1/13	0	3/13	
Sector 5	2/13	1/13	0	3/13	
Undetermined	1/13	0	0	1/13	
Total	7/13	4/13	2/13	13/13	

of 60-70% of demineralization.<sup>25</sup> According to Ericson and Kuroi<sup>22</sup> three factors must be considered when establishing whether a neighbouring tooth was resorbed by the erupting canine:- 1- the degree of over-lapping, 2- the appearance of the lamina dura structure, and 3- the appearance of the root contour. Their study concluded that conventional radiographs are not reliable in detecting root resorption of the maxillary incisors, especially when the defect is located either buccal or palatal. Meanwhile, a study by Cernochova et al.<sup>26</sup> found that CBCT detects root resorption more accurately at 67% of cases.

Root resorption caused by MIC often involves the lateral incisors, but studies have also found the involvement of the central incisors.<sup>8,27</sup> Incidence of lateral root resorption has been found to be at 18.5%.<sup>28</sup> Previous studies found a greater likelihood of root resorption to be associated with a more mesially located canine.<sup>9,21</sup> Similarly, in our study findings, the majority of lateral incisor RR identified on CBCT were located more mesially in sectors 5 and 4. Our findings show 10 lateral incisors, 2 central incisors and 1 premolar with RR on 2-D pan as compared to 13 lateral incisors and 2 central incisors on CBCT. These findings are in accordance with the results of previous studies that have reported lateral incisors as the most affected tooth with root resorption associated with MIC.<sup>4,21</sup> Ericson and Kuroi's<sup>21</sup> computed tomography study of 156 sides with ectopically positioned maxillary canines, showed 72 incisors were resorbed, which included 58 lateral incisors (38%) and 14 central incisors (9%). Walker and Enciso<sup>4</sup> did a CBCT study of a sample of 19 patients with 27 impacted maxillary canines and showed resorption of 18 lateral incisors (66.7% of 27 cases) and 3 central incisors.<sup>4</sup> The difference in the

reported incidence of resorption has been attributed to the difference in the imaging techniques used.<sup>6</sup> In younger patients, the impacted canines appear more often in the middle of the maxillary bone, whereas in older patients, the canines are located more often in the palatal or buccal side of the maxilla.

CBCT has been proven to be the most effective modality that can reveal the degree of root resorption on teeth adjacent to ectopically erupting maxillary canines.<sup>4,13,29</sup> In our study, we used the criteria suggested by Ericson and Kuroi<sup>21</sup> to grade the severity of root resorption in which they reported 9% moderate and 60% severe root resorption, whereas Oberoi<sup>30</sup> reported 35% slight and 4% severe root resorption. Severe root resorption has also been reported in the literature at 8.1% by Alqerban et al.,<sup>29</sup> 11.9% by Walker et al.,<sup>4</sup> and 19.6% by Liu et al.<sup>31</sup> Our study findings show 53% slight, 31% moderate and 15% severe root resorption. The difference in the results amongst the studies compared to our study findings could be due to the high variability in the classification and categorization of root resorption severity as well as differences in sampling. Nonetheless, root resorption will affect the treatment plan and early intervention of RR caused by impacted canines may save time, expense and prevent more complicated treatment.

In practice, clinicians depend on 2-D pan to provide a baseline view and a tool to locate MIC and subsequently suspect incisor root resorption. However 2-D pan has shortcomings that include image distortion, anatomical superimposition, and image obscurity.<sup>4,9,13,26,29</sup> Studies have recommended the use of CBCT as an imaging modality of choice for detecting root resorption associated with MIC.<sup>13,26-29</sup> The root resorption of adjacent

permanent teeth cannot be accurately judged from a 2-D radiograph alone. Our study findings have supported that CBCT imaging was significantly better than the panoramic radiograph in determining root resorption. Clinical management of impacted canines and associated root resorption can be complex and frustrating for the orthodontist. Informed consent has to be exercised prior to orthodontic treatment and the patient should be made aware of the risks and benefits associated with it. If the patient declines the orthodontic treatment, advice should be given for regular review to evaluate the effect of root resorption. If the orthodontic treatment is already in progress and the resorption is diagnosed halfway, the patient should be informed of the condition, and changes to the treatment plan becomes necessary. If asymptomatic and immobile, a resorbed tooth can be kept for an aesthetic and functional purpose for subsequent prosthodontic rehabilitation.<sup>16,32</sup>

## 5. Study Limitations

The study had to cross the hurdle of missing records because of the nature of the retrospective studies. This limitation of missing data was overcome by omitting those records with missing data and adding records until the convenient sample size was achieved. This approach is known as available case analysis.<sup>33</sup> The sample size gender was not equally distributed; therefore, the results cannot be generalized that some RR are more frequent in one of these groups. The study was undertaken using pre-treatment orthodontic radiographs, no examination was made of the post-treatment radiographs to evaluate the management of the findings.

## 6. Recommendations

1. The ability to detect RR before and during orthodontic treatment should be a skill that each clinician has in practice. Continued education and training of clinicians is recommended in examining and reporting panoramic radiographs thoroughly as they are commonly used in clinical dentistry.
2. A modification to the current Ericson and Kuroi classification (1988) of sector location to include sector -1 (the canine tip is located in the opposing quadrant and crosses the midline). This modification should be studied further.
3. Further studies should be conducted using a study sample that is more representative for further audit and quality assurance on the treatment outcome of MIC and RR.

## 7. Conclusion

Panoramic radiograph remains the routine diagnostic tool for evaluation of the dentition in contemporary dental practice. Their limitation in definitive diagnosis of RR

should be augmented with the use of CBCT. The detection of RR in our study shows the importance for clinicians to examine panoramic radiographs thoroughly beyond the orthodontic counting of teeth. The presence of RR can have an impact on diagnosis and treatment planning, especially in orthodontics. Our study findings showed that:

1. Maxillary impacted canines that are present in Sector 4 and Sector 5 on a panoramic radiograph should raise concerns for RR.
2. These should be followed up by a limited Field of View CBCT of the affected side for further evaluation.
3. Root resorption is most likely to occur on the lateral incisor.

## 8. Data Availability Statement

The data supporting this study's findings are available on request from the corresponding author. The data are not publicly available due to privacy or ethical restrictions.

## 9. Ethics Approval Statement

Ethical approval was obtained from the University of the Research Ethics Committee (Reference: 677/2021) to conduct the study.

## 10. Source of Funding

None.

## 11. Conflict of Interest

None.

## References

1. Cruz RM. Orthodontic traction of impacted canines: Concepts and clinical application. *Dental Press J Orthod.* 2019;24(1):74–87.
2. Becker A, Chaushu S. Etiology of maxillary canine impaction: A review. *Am J Orthod Dentofacial Orthop.* 2015;148(4):557–67.
3. Chaushu S, Chaushu G. The use of panoramic radiographs to localize displaced maxillary canines. *Oral Surg Oral Med Oral Pathol Oral Radiol Endod.* 1999;88(4):511–6.
4. Walker L, Enciso R. Three-dimensional localization of maxillary canines with cone-beam computed tomography. *Am J Orthod Dentofacial Orthop.* 2005;128(4):418–23.
5. Shumar A. Prevalence of impacted canine and its association with other dental anomalies among population in sana'a city. *Int Arab J Dent.* 2021;12(1):32–9.
6. Aidos H, Diogo P. Root resorption classifications: A narrative review and a clinical aid proposal for routine assessment. *Eur Endod J.* 2018;3(3):134–45.
7. Cooke ME, Nute SJ. Maxillary premolar resorption by canines: Three case reports. *Int J Paediatr Dent.* 2005;15(3):210–2.
8. Alqerban A, Jacobs R. Root resorption of the maxillary lateral incisor caused by impacted canine: A literature review. *Clin Oral Investig.* 2009;13(3):247–55.
9. Ngo CTT, Fishman LS, Rossouw PE, Wang H, Said O. Correlation between panoramic radiography and cone-beam computed tomography in assessing maxillary impacted canines. *Angle Orthod.* 2018;88(4):384–9.

10. Jiménez-Silva A, Carnevali-Arellano R. Prediction methods of maxillary canine impaction: A systematic review. *Acta Odontol Scand.* 2022;80(1):51-64.
11. Elefteriadis JN, Athanasiou AE. Evaluation of impacted canines by means of computerized tomography. *Int J Adult Orthodon Orthognath Surg.* 1996;11(3):257-64.
12. Alassiry AM, Hakami Z. Root resorption of adjacent teeth associated with maxillary canine impaction in the saudi arabian population: A cross-sectional cone-beam computed tomography study. *Appl Sci.* 2021;12(1):334.
13. Deepak C, Saravanan B, Kumar SK. Cbct-a paradigm shift in the management of dental impactions. *Indian J Multidiscip Dent.* 2011;1(2):67-73.
14. Jung YH, Liang H, Benson BW, Flint DJ, Cho BH. The assessment of impacted maxillary canine position with panoramic radiography and cone beam ct. *Dentomaxillofac Radiol.* 2012;41(5):356-60.
15. Becker A, Chaushu S. Etiology of maxillary canine impaction: A review. *Am J Orthod Dentofacial Orthop.* 2015;148(4):557-67.
16. Ericson S, Bjerklín K. Does the canine dental follicle cause resorption of permanent incisor roots? A computed tomographic study of erupting maxillary canines. *Angle Orthod.* 2002;72(2):95-104.
17. Ericson S, Kuroi J. Resorption of maxillary lateral incisors caused by ectopic eruption of the canines: A clinical and radiographic analysis of predisposing factors. *Am J Orthod Dentofacial Orthop.* 1988;94(6):503-13.
18. Ericson S, Kuroi J. Early treatment of palatally erupting maxillary canines by extraction of the primary canines. *Eur J Orthod.* 1988;10(4):283-95.
19. Power SM, Short MB. An investigation into the response of palatally displaced canines to the removal of deciduous canines and an assessment of factors contributing to favourable eruption. *Br J Orthod.* 1993;20(3):215-23.
20. Warford JH, Grandhi RK, Tira DE. Prediction of maxillary canine impaction using sectors and angular measurement. *Am J Orthod Dentofacial Orthop.* 2003;124(6):651-5.
21. Ericson S, Kuroi PJ. Resorption of incisors after ectopic eruption of maxillary canines: a CT study. *Angle Orthod.* 2000;70(6):415-23.
22. Ericson S, Kuroi J. Radiographic examination of ectopically erupting maxillary canines. *Am J Orthod Dentofacial Orthop.* 1987;91(6):483-92.
23. Shokri A, Mortazavi H, Salemi F, Javadian A, Bakhtiari H, Matlabi H. Diagnosis of simulated external root resorption using conventional intraoral film radiography, ccd, psp, and cbct: A comparison study. *Biomed J.* 2013;36(1):18-22.
24. Almuhtaseb E, Mao J, Mahony D, Bader R, Zhang ZX. Three-dimensional localization of impacted canines and root resorption assessment using cone beam computed tomography. *J Huazhong Univ Sci Technolog Med Sci.* 2014;34(3):425-30.
25. Goldberg F, Sllvlo AD, Dreyer C. Radiographic assessment of simulated external root resorption cavities in maxillary incisors. *Endod Dent Traumatol.* 1998;14(3):133-6.
26. Cernochova P, Krupa P, Izakovicova-Holla L. Root resorption associated with ectopically erupting maxillary permanent canines: A computed tomography study. *Eur J Orthod.* 2011;33(5):483-91.
27. Arens DE. An alternative treatment for the severely resorped maxillary lateral incisor: A sequela of ectopic eruption. *J Endod.* 1995;21(2):95-100.
28. Kalavritinos M, Benetou V, Bitsanis E, Sanoudos M, Alexiou K, Tsiklakis K, et al. Incidence of incisor root resorption associated with the position of the impacted maxillary canines: A cone-beam computed tomographic study. *Am J Orthod Dentofacial Orthop.* 2020;157(1):73-9.
29. Algerban A, Jacobs R. Comparison of two cone beam computed tomographic systems versus panoramic imaging for localization of impacted maxillary canines and detection of root resorption. *Eur J Orthod.* 2011;33(1):93-102.
30. Oberoi S, Knueppel S. Three-dimensional assessment of impacted canines and root resorption using cone beam computed tomography. *Oral Surg. Oral Surg Oral Med Oral Pathol Oral Radiol.* 2012;113(2):260-7.
31. Liu DG, Zhang W, Zhang ZY, Wu YT, Ma XC. Localization of impacted maxillary canines and observation of adjacent incisor resorption with cone-beam computed tomography. *Oral Surg Oral Med Oral Pathol Oral Radiol Endod.* 2008;105(11):91-8.
32. Levander E, Malmgren O. Evaluation of the risk of root resorption during orthodontic treatment: A study of upper incisors. *Eur J Orthod.* 1988;10(1):30-8.
33. Kang H. The prevention and handling of the missing data. *Korean J Anesthesiol.* 2013;64(5):402-6.

## Author biography

Zubeida Maalim, -

Millicent Motsepe, - <https://orcid.org/0000-0002-1346-6681>

Shoayeb Shaik, - <https://orcid.org/0000-0002-4898-3005>

Ntombizodwa R Nkambule, - <https://orcid.org/0000-0003-2524-6413>

**Cite this article:** Maalim Z, Motsepe M, Shaik S, Nkambule NR. Root resorption of maxillary lateral incisors associated with maxillary impacted canines: Cone-beam computed tomography and panoramic radiography study. *Int J Oral Health Dent* 2024;10(2):107-113.