

Management of Oral Leukoplakia with Photodynamic Therapy

Sujata K. Satoskar^{1,*}, Aarathi S Shenoy², Sapna Raut Dessai³

¹Assistant Professor, ^{2,3}Lecturer, Dept. of Oral Medicine & Radiology, Goa Dental College & Hospital, Goa

*Corresponding Author:

Email: dr.sujataks2005@yahoo.in

Abstract

Premalignant lesions like Oral Lichen Planus (OLP), Oral Leukoplakia (OL) has a fair probability of transforming into malignancy and they are perverse toward conventional therapies. Photodynamic therapy (PDT) has been considered as an alternative/ complimentary therapeutic modality for the management of premalignant lesions. Photodynamic therapy (PDT) is a noninvasive method for the treatment of premalignant lesions and head and neck. The principle of PDT is a nonthermal photochemical reaction, which requires the simultaneous presence of a photosensitising drug (photosensitiser), oxygen, and visible light. After a period to allow the photosensitiser to collect in the target tissue, the photosensitiser is activated by exposure to low-power visible light of a drug-specific wavelength. PDT is a cold photochemical reaction, and the photosensitising agents are of inherently low systemic toxicity. This article describes the role of non-surgical management of Oral Leukoplakia with use of Photodynamic Therapy.

Keywords: Oral Leukoplakia, PDT, ALA, Monochromatic red light, Mucosa

Access this article online	
Quick Response Code:	Website: www.innovativepublication.com
	DOI: 10.5958/2395-499X.2016.00017.4

Introduction

Photodynamic therapy (PDT) is a non-invasive method for topical and selective treatment of premalignant lesions of oral cavity.⁷ 5-aminolevulinic acid (ALA) mediated photodynamic therapy (PDT) is a new therapy for the treatment of oral leukoplakia.⁵

Principle

The selective uptake and retention of a local or systemically administered photosensitizer in tumor tissue is the main principle behind PDT. Intracellular activation of the photosensitizer, using light of the proper wavelength, results either in the production of radicals (type I mechanism) or the formation of intracellular singlet oxygen (type II mechanism), which causes cell death by vascular shutdown mechanisms and intracellular oxygenation.⁴

Method

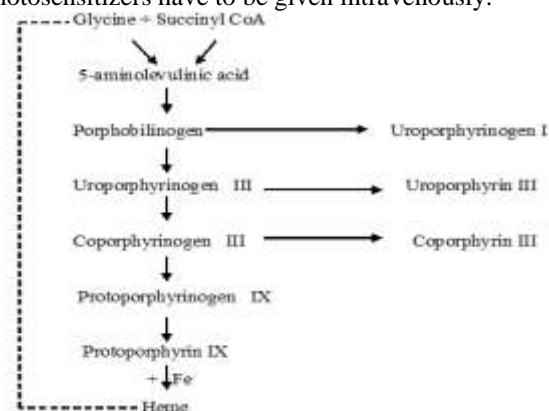
In PDT the photosensitizer is mainly administered intravenously several hours prior to the light treatment (48-96 hours).⁵ After i.v. injection, the photosensitizer is retained in the dysplastic and tumor cells and then activated intracellularly by light of a specific wavelength, which leads to cell death.

The major side effect of this kind of therapy is systemic photosensitization of the patients, which lasts

for several weeks. This is caused by minor concentrations of photosensitizer in the skin leading severe edema, sunburn, or even superficial skin necrosis. The patients have to stay out of bright light and sunlight for several weeks.²

Topical application of a photosensitizer on superficial tumors offers an alternative to i.v. injection.⁶

5 - Aminolevulinic Acid (ALA): ALA, a precursor in the biosynthesis of heme, induces the production of the endogenous photosensitizer protoporphyrin IX which can be used for PDT. It is the only photosensitizer which can be given orally or applied topically. All other photosensitizers have to be given intravenously.



Biosynthesis pathway of Heme. Negative feedback control is indicated⁵: ALA is the first step in heme synthesis. In the presence of an excess of ALA the regulatory feedback system is disrupted, after which protoporphyrin IX (PPIX) accumulates. PPIX is the last intermediate product in heme synthesis and an effective photosensitizer.⁶ PPIX can be activated intracellularly by red light at 630 nm. After light activation, singlet

oxygen is produced, followed by intracellular oxidation and cell death. The photosensitization of the patient is limited to the PPIX synthesis and, therefore, to the area of ALA application and only lasts for a few hours.⁵

In the field of PDT, ALA is unique as being the only photosensitizer for PDT so far which can produce reliable photosensitization when administered orally or topically. By either route of administration, maximum-tissue concentrations of PPIX- are obtained within four hours, followed by an almost equally rapid decline. Within 48 hours, tissue levels of PPIX are back to background levels.⁸

Thus, ALA-induced PPIX photosensitization is cleared from the skin within 48 hours after oral, intravenous or topical use. The lack of long-lasting photosensitization is the great advantage of ALA over all other photosensitizers. Thus patients do not have to take any precautions concerning light and sun exposure after the first 48 hours.⁵

Review

A Study conducted to investigate whether ALA-PDT can be used in the treatment of leukoplakia; twelve patients, who had been suffering from leukoplakia of the oral mucosa for several years, were treated by ALA-mediated PDT.

ALA was used as a topical photosensitizer and 20% ALA cream was applied to the leukoplakia lesion of the oral mucosa for two hours and then light activated at 630 nm, 100 mW/cm² and 100 J/cm².

ALA (Medac, Hamburg Germany) was dissolved in eucerin anhydric at a concentration of 20%. The pH-value was set at 5 by natrium bicarbonate. In order to improve the adhesive capacity of the cream to the oral mucosa and to increase the consistency, 5% gum arabic and paraffin were added. The cream was always mixed immediately prior to each treatment (max. 1 hour) in order to obtain a maximum of active ALA.⁵

After detailed instructions to the patient, 3-5 g of the ALA cream was applied to the leukoplakia. In order to prevent spilling of the cream by tongue movement or salivation, the cream was covered by gauze pads. Every 30 minutes another 3-5 g of ALA cream was applied to the lesion over a period of two hours. During the incubation, patients were allowed to swallow. Depending on the size of the lesion a total amount of 5-10 g of 20% ALA cream was applied per lesion. After two hours, the cream was removed and the leukoplakia lesion and the adjacent normal tissue were illuminated for one hour by monochromatic red light delivered by an argon-dye laser at 630 nm (100 mW/cm², 100 J/cm², 1000 sec). Light at 630 nm corresponds to the absorption peak of PPIX, when a maximum of activated PPIX can be obtained. At 630 nm, a light penetration depth of 5 mm into human tissue can be expected.

Results

During incubation, patients did not feel any pain or discomfort. In the course of light irradiation, five patients described a mild burning sensation which did not require analgesic medication and which vanished immediately after laser treatment.

During the first few days after PDT, a local inflammatory reaction was seen. Within one week inflammation increased and desquamation of the top cell layers occurred, but this was limited to the area of leukoplakia. The surrounding normal mucosa within the treatment field was not altered or showed only a mild reaction with redness but without desquamation.

During the healing period, none of the patients felt any pain. Within two weeks the wound healing was complete without any signs of scarring.

Three months after ALA-PDT

Five patients showed complete response to the treatment i.e. healed oral mucosa without any sign of remaining leukoplakia.

Four patients showed a partial response i.e. the size of the lesion had decreased or the clinical appearance had improved (e.g. verrucous leukoplakia to flat leukoplakia) and in three patients treatment was unsuccessful.

One patient who showed only a partial response after the first course of treatment was treated again in the same way after two months. After the second series of ALA-PDT, a complete response without any sign of remaining leukoplakia was obtained at the three-month follow-up examination.⁵

During follow up, no changes in the clinical appearance of the treated lesions were observed. The mean follow up was 9 months ranging from 6 to 16 months.⁵

The effect of therapy, after topical application of ALA is limited by the penetration depth of light at 630 nm as well as by the infiltration depth of ALA into the tissue. Light penetration at 630 nm. the absorption peak of PPIX aggregates about 5 mm depending on the optical properties of the illuminated tissue. By a maximum ALA penetration depth of 2 mm at the oral mucosa, ALA-PDT is limited by the infiltration depth of ALA. A high uptake and metabolic effect for topically applied ALA in the oral mucosa is demonstrated.

The treatment of oral leukoplakia seems to be ideal for topical application of ALA, because of the superficial lesion and the lack of a keratin layer. Topical ALA-PDT seems to be a promising means of treating oral leukoplakia, since it is a noninvasive therapy that can be repeated without causing harm.⁵

Fan et al reported on the successful treatment of 12 patients with oral dysplasias by systemic administration of ALA. Even by systemic administration, the depth of necrosis was limited to 1-2 mm.¹

The oral mucosa has a different histological structure in that the absence of the keratin layer facilitates the penetration of ALA into the mucosa, an average penetration depth of 2 mm might be expected.³

A study was done to determine therapeutic response to PDT in patients with oral leukoplakia. Twelve patients were selected with lesions at a variety of intraoral sites. The most common location was buccal, gingival and mandibular mucosa. Patients were treated with topically applied 10% delta-aminolevulinic acid (ALA) and light from an argon-pumped dye laser. Irradiation was performed in several (6-8) sessions using light at 635 nm wavelength, delivering a total dose of 100 J/cm² per session. A complete response was obtained in 10 out of 12 treated patients. One recurrence was observed during 6 months. It was concluded that Photodynamic therapy appears to be a feasible alternative to conventional therapy of pre-malignant lesions of oral cavity.⁷

References

1. Fan KF et al. Photodynamic therapy using 5-aminolevulinic acid for premalignant and malignant lesions of the oral cavity. *Cancer* 1996;78:1374-83.
2. Gongloff RK, Gage AA. Cryosurgical treatment of oral lesions: report of cases. *J Am Dent Assoc* 1983;106:47-51.
3. Grant W, Hopper C, Macroert AJ, Speight PM, Mown SG. Photodynamic therapy of oral cancer: photosensitization with systemic aminolevulinic acid. *Lancet* 1993;342:147-8.
4. Henderson B, Dougherty T, How does Photodynamic Therapy Work? *Photochem Photobiol B* 1992;55:145-57.
5. Kabler A, Haase T, Rheinwald M, Barth TJ. Mahling: Treatment of oral leukoplakia by topical application of 5-aminolevulinic acid. *Int J Oral Maxillofac. Surg* 1998;27:466-469.
6. Kennedy JC, Potter RH, Endogenous protoporphyrin IX, a clinically effective photosensitizer for Photodynamic therapy. *J Photochem Photobiol B* 1992;14:275-92.
7. Sieron A, Adamek M, Kawazyk-Krupka A, Mazur S, Ilewicz L; Photodynamic therapy (PDT) using topically applied delta-aminolevulinic acid (ALA) for the treatment of oral leukoplakia. *J Oral Pathol Med* 2003 Jul;32(6):330-6.
8. Webber J, Kessel D, Fromm D. Plasma levels of protoporphyrin IX in humans after oral administration of 5-aminolevulinic acid. *J Photochem Photobiol B* 1997;37:151-3.