

## Pigmentation of the Fungiform Papillae of the Tongue in a Child Secondary to Iron Deficiency Anaemia: An Uncommon Occurrence and Association

Sarika Sharma<sup>1,\*</sup>, Sudhanshu Sharma<sup>2</sup>

<sup>1</sup>Consultant, Dept. of Dentistry, RK Hospital and Research Centre, Pandav Nagar, New Delhi

<sup>2</sup>Assistant Professor, Department of Dermatology & Venereology,  
Shaheed Hassan Khan Mewati Government medical college, Mewati, Nalhar, Haryana – 122107

**\*Corresponding Author**

E-mail: drsudhanshusharma11@gmail.com

### Abstract

Diagnosis of pigmented lesions of the mouth and oral mucosal tissues is challenging. Even though epidemiology may be of some help in orientating the clinician and even though some lesions can be diagnosed on clinical grounds alone, the definitive diagnosis requires histopathological examination. We report a case of pigmented fungiform papillae on the tongue secondary to iron deficiency anaemia. After extensive literature search we found very few cases of pigmented fungiform papillae on the tongue due to iron deficiency anaemia in paediatric population. Hence here we report a 12-year-old male presented with patchy pigmented areas on his tongue of 4 years duration. We gave iron plus folic acid tablets for 6 months with complete disappearance of the lesions.

**Keywords:** Iron deficiency anaemia, pigmented fungiform papillae of the tongue

Access this article online	
<b>Quick Response Code:</b> 	<b>Website:</b> <a href="http://www.innovativepublication.com">www.innovativepublication.com</a>  <b>DOI:</b> 10.5958/2395-499X.2016.00005.8

tongue containing taste buds[3]. Pigmented fungiform papillae of the tongue (PFPT) were first mentioned by Leonard as a benign condition of oral pigmentation characterized by localized hyperpigmentation related to fungiform papillae[4]. Common age group of PFPT occurrence is 2<sup>nd</sup> to 3<sup>rd</sup> decade and more common in the African Americans, but few cases have been described in Indian populations[5]. Although the condition is not rare and might be easily diagnosed, it is seldom mentioned in the dental or medical literature. We therefore report a case of PFPT in a paediatric patient.

### Introduction

The colour of oral mucosal pigmentation depends on the quantity and depth or location of the pigment. Generally, the superficial lesions shows brown pigmentation and those located deeper are black or blue. Melanin is produced by melanocytes in the basal layer of the epidermis and is transferred to nearby keratinocytes via membrane-bound organelles called melanosomes. Melanin is also formed by nevus cells, which are derived from the neural crest tissue and are found in the skin and mucosa[1]. The melanocytes are present in any part of the oral mucosal cavity and can be present in reactive, benign or malignant lesions.

In addition, pigmentation developed from foreign bodies, heavy metal poisoning or drugs may also increases pigmented lesions, which can vary in intensity and extension, and can occur in any part of the oral cavity[2]. The clinical history, symmetry and uniformity of the lesion are most important points in determining the clinical differential diagnosis.

Tongue is very important structure in the oral cavity and lingual papillae play pivotal role in sensation of taste. There are four type of papilla on the tongue. Fungiform papillae are mushroom-shaped projections distributed on the tip, lateral or dorsal aspect of the

### Case Report

A 12 year old male came to the outpatient department of paediatric dentistry with chief complaint of pain in upper left tooth region since 15 days and asymptomatic black pigmented lesions on the dorsum and lateral border of tongue since 4 years. He was healthy and was not taking any medications. The treatment regarding the dental issue was done first. On clinical examination caries reaching to dentin was found. A radiograph was taken and lesion reaching to dentin was confirmed. The patient gave the history of pain on eating food which subsides on its own. Hence, reversible pulpitis was confirmed as the final diagnosis. After that the caries was excavated with respect to the same tooth and it was restored with glass ionomer cement. After solving the dental issue the case was discussed extensively with the dermatologist regarding the black pigmented lesions on the tongue.

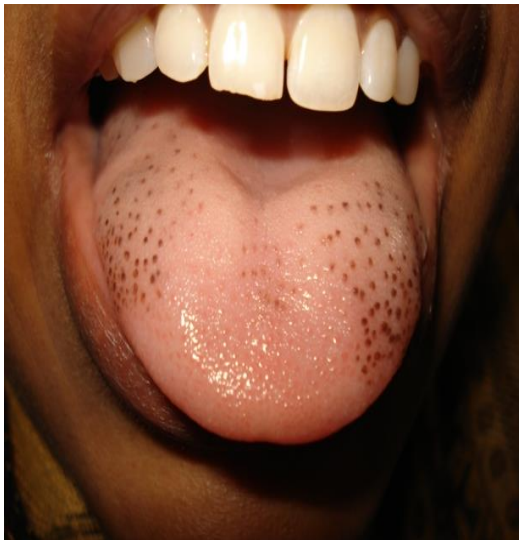The parents did not present similar pigmentation of the oral mucosa. On routine haematological study his haemoglobin was 9gm% and total leukocytes count was 13500. Beside this all haematological parameters were

within normal limit. On general physical examination his sclera and conjunctival mucosa showed yellowish discoloration.

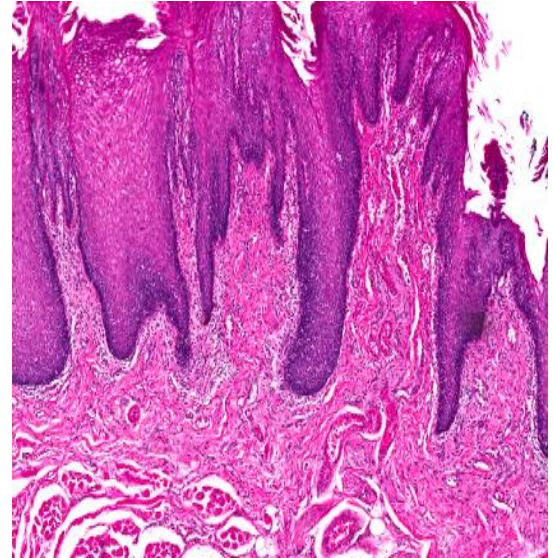
Examination of the oral mucosa showed pigmentation limited to the fungiform papillae of the dorsum and lateral border of the tongue. Some of the fungiform papillae were pigmented and were present in a symmetrical pattern, predominantly on the tip and lateral aspects of the dorsum of the tongue (Fig. 1). The fungiform papillae in the central area were not pigmented. The filiform papillae, which are numerous, are distributed on the anterior two thirds of the dorsum of the tongue, and the circumvallate papillae, which are the largest and less numerous, are found towards the posterior side of the tongue.

Punch biopsy was taken with 3 mm punch from the lateral border of the tongue. Histopathological examination of the lesion on the tongue showed, many melanophages in the subepidermal area within the fungiform papillae. Hence was consistent with the diagnosis of pigmented fungiform papillae of the tongue [Fig. 2].

The patient was reassured of the benign nature of the condition and tablet iron and folic acid once a day was given for 6-months.



**Fig. 1: Black pigmented lesions on the dorsum and lateral border of tongue: Pigmented Fungiform Papilla of the tongue (PFPT)**



**Fig. 2: Melanophages in the subepidermal area of the fungiform papilla.**

### Discussion

It is the tongues that are responsible for all taste sensations, help in swallowing and communication through speech. Papillae are small structures that help us to recognize whether we taste something as sweet, salty, sour or bitter. They also help us to recognize the often bland tastes of food[2]. Anything we are putting in our oral cavity, it is the papillae that help us to recognize its taste. Papillae are surrounded by taste buds, and these tiny structures in our mouth are an important part of the entire system[3,5].

There are four varieties of papillae that can be found on the tongue. Knowing the difference between them is important, but is interesting to know that what determines different tastes. Fungiform papillae are mushroom shaped papillae recognize sweet and sour tastes. They are distributed in a scattered way along the top of the tongue, but most are found on the sides of the tongue and the apex of the tongue. Filiform papillae are V-shaped and are long and thin they help to recognize sour taste. Circumvallate papillae are distributed in a V-shape form on the back end of the tongue that heads toward the throat. These papillae are very less and most people have in between 10 to 14. The taste buds surrounding these papillae pick up mainly bitter taste in food. Foliate papillae are distributed on the sides of the tongue and contain elongated fold. Clustered into two groups, they help to recognize salty taste[1,2,3].

We generally not think about papillae until something goes wrong. When our papillae become enlarged it's pretty hard to ignore them. Papillae that become infected or irritated and enlarged can be painful and make eating and drinking very difficult. While enlarged papillae are often normal, there are certain disorders that cause the enlargement of the papillae on the tongue[5].

Many time, enlarged papillae is a normal part of growing. However, there are also certain harmful diseases that causes enlargement of the papillae. There are many factors that can cause enlargement of papillae. Excessive smoking can cause irritation to the tongue this can result in enlargement of the papillae on the tongue. Canker sores can be present in the oral cavity with no known cause and when the person is under stress, this problem may be more intense. There are few medical diseases that have featured that include the enlargement of the papillae. Gastrointestinal conditions like gastrointestinal reflux disease (GERD) and ulcerative colitis are known to be related with enlarged papillae on the tongue. An oral cancer may be present if the sore does not disappear after two weeks. Infection may result from trauma of the tongue caused by biting, eating something hot or foods that are too acidic[4,5].

Tongue papillae are very tiny structures and on the same way most of the time there abnormality also considered as tiny. In the oral pathology literature these are the least reported part of oral cavity.

This was a case of PFPT with diffuse pigmentation predominantly at the tip and the lateral aspects of the tongue. The fungiform papillae in the central area were not pigmented. The surface of the tongue is covered by three types of papillae: filiform, fungiform and circumvallate[4]. The clinical features of PFPT include well-circumscribed hyperpigmentation confined to the fungiform papillae and lesions are generally asymptomatic. The disorder usually starts during late infancy and is not progressive. Clinically this condition occurs in the second and third decades with a predilection for females[1]. There are no alterations in the nail or other cutaneous structures[1]. The present case had similar features.

Holzwaner et al.[1] have classified PFPT into three clinical types. The first type is a well-circumscribed hyperpigmented area involving all the fungiform papillae on the anterolateral side or towards the tip of the tongue. The second type shows hyperpigmentation involving 3-7 fungiform papillae scattered on the dorsal surface of the tongue, and in the third type hyperpigmentation is seen on every fungiform papilla on the dorsum of the tongue. In our patient, the pattern of distribution was of the first type.

PFPT is generally considered as a common finding in African American patients [4]. In 1973, Holzwaner et al.[1] examined 300 random individuals and came to the conclusion that among blacks, 30% of men and 25% of women exhibited some hyperpigmentation of fungiform papillae, whereas among Asians and Caucasians the prevalence is very low[3,5]. The histopathological features of PFPT show numerous macrophages in the lamina propria which stain positive for melanin with Fontana-Masson and negative for iron with Prussian blue with no evidence of an inflammatory infiltrate[6].

The pathogenesis of pigmented fungiform papillae is still unclear. Oh et al.[7] have reported associations with dermatological disorders such as linear circumflex ichthyosis and lichen planus, and an association with systemic diseases such as hemochromatosis, scleroderma, pernicious anemia, and iron deficiency anemia has also been described, although most patients are healthy[7]. Besides ethnicity, Werchniak et al.[6] reported pigmented fungiform papilla in a mother and her daughter, which lends support to the idea that a genetic predisposition may be a contributing factor.

There is no effective treatment reported however, in one case associated with iron deficiency anemia, a moderate reduction in pigmentation was reported after treatment of the anemia similar to our case[6]. Treatment for painful and enlarge papillae on the tongue includes smoking cessation, promote good oral hygiene by brushing teeth and tongue, flossing, and eating healthy foods, avoid eating hot, spicy, and acidic foods, gargle with salt water or a mouth rinse to ease the pain. Yogurt can help improve the balance of bacteria in the body, increase the intake of diary food products like low fat milk, avoid biting the tongue, increase the intake of vitamin B12 supplements which are helpful in the management of mouth ulcers and cold sores and intake of iron supplements or natural sources of iron like prunes, dates, etc are also required for the management of enlarged papillae on the tongue[6].

## Conclusion

Many pigmented lesions can be clinically diagnosed based on size, shape, or colour, along with the clinical information. Developing a differential diagnosis is imperative for a clinician faced with these lesions in order to appropriately treat the patient. Therefore, the establishment of effective clinical maneuvers in front of pigmented lesions of oral mucosa is crucial in the exclusion of possible malignancies.

Although enlarge papillae are benign condition and generally not associated with any specific morbidity to the patient, still Clinicians should be aware of this condition of lingual pigmentation to avoid incorrect diagnosis and unnecessary investigative procedures.

**Conflict of Interest: None**

**Source of Support: Nil**

## References

1. Kauzman A, Pavone M, Blanas N, Bradley G. Pigmented lesions of the oral cavity: review, differential diagnosis, and case presentation. *J Can Dent Assoc.* 2004;70:682-3.
2. Meleti M, Vescovi P, Mooi WJ, van der Waal I. Pigmented lesions of the oral mucosa and perioral tissues: a flow-chart for the diagnosis and some recommendations for the management. *Oral Surg Oral Med Oral Pathol Oral Radiol Endod.* 2008;105:606-16.
3. Eisen D. Disorders of pigmentation in the oral cavity. *Clin Dermatol.* 2000;18:579-87.

4. Holzwanger JM, Rudolph RI, Heaton CL: Pigmented fungiform papillae of the tongue: a common variant of oral pigmentation. *Int J Dermatol* 1974;13:403-408.
5. Leonard TMR: Ankylostomiasis or uncinariasis. *JAMA* 1905;45:588-594.
6. Scarf CE, Marks R: Pigmented fungiform papillae of the tongue in an Asian man. *Australas J Dermatol* 2003;44:149-151.
7. Boshell JL, Wilborn WH, Singh BB: A correlative light microscopic, transmission and scanning electron microscopic study of the dorsum of human tongue. *Scan Electron Microsc* 1980;3:505-510.
8. Tan C, Liu Y, Min Z-S, et al: A clinical analysis of 58 Chinese cases of pigmented fungiform papillae of the tongue. *J Eur Acad Dermatol Venereol* 2012, E-pub ahead of print.
9. Werchniak AE, Storm CA, Dinulos JG: Hyper pigmented patches on the tongue of a young girl. Pigmented fungiform papillae of the tongue. *Arch Dermatol* 2004;140:1275-1280.
10. Oh CK, Kim MB, Jang HS, et al: A case of pigmented fungiform papillae of the tongue in an Asian male. *J Dermatol* 2000;27:350-351.
11. Jang YH, Lee JY, Kang HY, et al: Oestrogen and progesterone receptor expression in melasma: an immunohistochemical analysis. *J Eur Acad Dermatol Venereol* 2010;24:1312-1316.
12. Urbina F, Sudy E: Pigmented fungiform papillae of the tongue in Laugier disease or Laugier-Hunziker syndrome. *Actas Dermosifiliogr* 2013;104:173-174.
13. Marcoval J, Notario J, Martín-Sala S, et al: Pigmentation of the fungiform papillae of the tongue: a report of 2 cases. *Actas Dermosifiliogr* 2011;102:739-740.