

## Forensic Odontology: The Investigative Branch of Dentistry - A Review

Shiva Kumar B<sup>1</sup>, Rahul Tonse Ganesh<sup>2,\*</sup>

<sup>1</sup>Senior Lecturer, Dept. of Conservative Dentistry and Endodontics  
D.A.P.M.R.V Dental College, CA-37, 24<sup>th</sup> Main, 1 Phase J.P. Nagar, Bangalore, Karnataka - 560078

<sup>2</sup>MDS-Oral Pathology, Thonse Rahul's Dental Clinic  
C-15, Al-Rahaba Plaza, Nellikai Road, Near SBI, Mangalore – 575001

**\*Corresponding Author**

E-mail: rahuldentalclinic@yahoo.in

### Abstract

The past 100 years has seen the transformation of a previously small and irrelevant area of the human body into a vast science of investigation and research called as forensic odontology. This article is a review of the history, mass disaster identification, assault victim identification and the various processes involved in Forensic Odontology.

**Keywords:** ABFO, Ante-mortem, Bite mark, DNA, Post-mortem.

Access this article online	
Quick Response Code:	Website: www.innovativepublication.com
	DOI: 10.5958/2395-499X.2016.00007.1

### Introduction

Teeth are harder than any other tissue in the body and can withstand very high levels of thermal, chemical and physical insults. Therefore teeth and the dentition as a whole, is considered as an important source of identification in the living and the dead. Dental identification techniques are quite reliable and economic and vary from simple viewing of the involved area, to photography, to the more microscopic DNA levels. When the body has decomposed so badly that soft tissue and bone can no longer be used for identification and comparison, teeth provide an excellent source of DNA.(3)

Sometimes living people need to be positively identified, like in victims of amnesia, and when deliberate false information is given to escape from debts, an unhappy marriage or get the benefits of life insurance prematurely.(22)

Professor Keith Simpson, professor of forensic medicine, said in 1951 “Dental data provide detail of a kind, comparable with the detail that was previously thought to be provided only by fingerprints; A reason for coming to regard teeth as of very great importance in the identification of an individual”.(20)

Interpol has designated forensic odontology as one of the primary identifiers in victims of mass casualty events. This branch is involved in the following phases-scene, post-mortem, antemortem, reconciliation and debrief. Interpol has recognized dental identification as one of the primary methods in Disaster victim

identification (DVI) and has been utilized in cases like the Lockerbie air disaster (1988), Asian tsunami (2004), London bombings (2005) etc.(25)

Forensic science is vast and dentists are privileged to play a prominent part of the investigating team, since the oral cavity area is small but highly resistant to destruction. Dentists should accept the challenge to play the part in investigation when called on by studying, doing research and keeping equipment ready.(20)

Forensic odontology is practiced by dental surgeons with additional postgraduate training and experience in dental identification and comparison of antemortem with post-mortem dental features.

### History

In our society, identification of the deceased is very important, and identification by dental means has been regarded as accurate and reliable.

The first recorded medico-legal identification of a body using dental means is that of Dr. Joseph Warren, who was killed during a battle of the American Revolution in 1775, by a musket ball through the skull. He was initially buried in a mass grave and then 10 months later, exhumed and identified by the dental work of Paul Revere (silversmith, amateur dentist and revolutionary), and given a hero's re-burial in 1776.(2)

Mass forensic identification by dentition was first used at Paris, in the “fire of the Bazaar de la Charité tragedy” in May, 1897. 126 people were killed and relatives tried to identify the badly burned bodies. 30 bodies were eventually identified because of meticulous dental record keeping of amalgam fillings, gold repairs, crowns and evidence of extraction spaces noted in the mandibles and maxillae of the victims.(2)

Dr Oscar Amoedo wrote an article on the identification procedures used in the Paris disaster and prepared a framework to be used as a basis in future. His work “L'Art dentaire en médecine légale”, was published in 1898.(2)

The first case in Britain when a murderer was identified by his teeth marks was in 1948, in the "New Year's Eve dance murder". Dr. Keith Simpson matched tooth marks on Phyllis Lucy Gorrings's right breast with the dentition of her husband, Robert Gorrings.(2)

In May 1945, Russians troops discovered the badly burned bodies of Adolf Hitler and Eva Braun. Dr. Hugo Johannes Blaschke was Hitler's dentist and it was from his records that and the evidence of frontal sinus X-rays, and the surviving crown and bridge work made by Fritz Eichtmann, that the bodies of Hitler and his wife were identified and confirmed.(2)

### Definition

Forensic odontology is an interdisciplinary field between forensic medicine and dentistry.18 It is that branch of dentistry which is concerned with the practice of the law and the administration of justice.(22)

It involves the correct collection, management, interpretation, evaluation, and presentation of dental evidence for criminal or civil legal proceedings: a combination of various aspects of the dental, scientific, and legal professions.(23)

### Age estimation

Knowing our age is a basic human right and having it documented gives an identity to the individual. Date of birth is required to enter school, work, get married and get a pension. It is also required in events related to justice and dealing with offenders rightfully according to their age.(12)

Age is determined by the date of birth and the number of years after that to any point of time, and is called the **chronological age**. It is documented in birth certificates, hospital records, and governmental databases. In absence of these documents chronological age can be estimated by determining physiological age, which is the age at which a developing system or organ reaches a specific stage.

A set of criteria exist for a system or organ to be an ideal age indicator. It has to develop over a long period of time, be stable and not be affected by environmental or racial factors and have recognisable and measurable stages that can be assessed in the living as well as the dead. The human dentition develops over nearly a third of the average human life, with easily detected and predictable stages. Teeth are very stable and minimally affected by environmental factors, socioeconomic status, nutrition, dietary habits and even by endocrine factors. These qualities make the developing dentition the best age indicator compared with other systems.(12)

### Lip prints

Lip prints are unique and do not change during the life of a person. The external surface of the lip has numerous elevations and depressions that form a characteristic pattern, referred to as lip prints. These can

be obtained at crime scenes from clothing, cups, glasses, cigarettes, windows, and doors.(11)

Visible and invisible lip prints are significant. The vermilion border of the lips has minor salivary and sebaceous glands, which, together with the moisturizing done by the tongue, direct to the possibility of the existence of latent lip prints. The identification of latent print evidence is frequently considered the important tool in solving a crime. Latent prints can be easily seen using fluorescent dye. When dealing with persistent lipstick prints, since they have minimal oil content, their development using conventional powders might not be effective, and therefore lysochromes can be used. Surveillance should be the first step when processing lip prints by using white and ultraviolet light sources.

Photographs should be made prior to any processing to protect the evidence. Latent prints are photographed individually with an identification label and a scale; each step in the processing series must be photographed. Even invisible lip prints can be used and can be lifted using aluminium and magnetic powder. Lip prints can also be covered with substances allowing direct observation and photography.(11)

### Bite marks

Bite marks occur in a variety of crimes such as assault, rape, murder and child abuse. Mac Donald (1974) defined bite mark as 'a mark caused by the teeth either alone or in combination with other mouth parts'.(9)

Human bite mark in skin is a representation of certain features of the dental anatomy of the biter. Relevant anatomical features are dental arches, teeth, interproximal embrasures, tongue, lips, gingivae and palatal rugae. Bite marks are normally caused by the biting edges/cusps of teeth. In female victims, bite marks are most common on the breasts, arms and legs; in male victims, arms and shoulders are the most common sites.

Bite mark identification is based on the individuality of a dentition, which is used to match a bite mark to a suspected perpetrator. Matching is by tooth-by-tooth and arch-to-arch comparison using parameters of size, shape and alignment.(1)

Forensic analysis of bite mark depends upon accuracy in which the dentition transfers the shape in the skin as a bruise, and image capture (photograph) of both the injury and the dental cast of the suspect's teeth. Sometimes the initial indentation caused by teeth is lost due to dermal swelling but if the bite is inflicted post mortem then the indentation will remain.(1) Pattern, size and form of the human bite is extremely important in distinctive patterns such as a missing tooth or wide gap between teeth which can then be positively matched to the assailant.(2)

Bite mark analysis is the interpretation and comparison of two pieces of evidence: the photographic record of the bite mark and the dental casts of the

suspect biter. Cusps of first premolars are rarely recorded. Fracture of incisors or canines may result in deficiency in the incisal/cuspal level that may be represented as either a false absence or faint element in the bite mark.

The action of sucking produces a reduced intra-oral pressure that can traumatise the capillaries in the embouched tissue. Sucking during biting can produce a dimensional change in the dental arch components due to 'tenting' of the bitten tissue. Presence of a diffuse ovoid zone of bruising within the centre of a bite mark is indicative of sucking activity (Sopher, 1976).

Bite marks in children are often faint and difficult to see. The initial lesion may fade away only to become visible a few months after injury. This may be due to the melanocytes which tend to migrate slowly to the edges of wounds and indicate their presence by absorbing ultraviolet light. The wounds are demonstrated only by ultraviolet photography when a sufficient quantity of melanocytes has collected at the wound edges.

Important changes take place in the skin with ageing. In old age, the epidermis is very thin. The dermis has less elastic fibre content and is relatively avascular. The aged person bruises easily owing to poor collagen support of blood vessels, so slight pressure can produce an extensive bruise. In contrast to infants and old people, teenagers and adults bruise less easily.

Sometimes victims have self-inflicted bite marks, for example, when own hand is forced into mouth to stop screaming, during myocardial ischaemia, and in self-destructive behaviour in individuals who are mentally retarded.

### **Semen, saliva and oral sex**

Oral sex is usually penile, vaginal or with the breast. In male rape victims, the assault is usually anal and occasionally oral-penile.

Sperm persists in the mouth up to 21 hours, which is less than in the anus (46 hours) and the vagina (5 days), although it can be traced after gargling and may be present on the teeth. Sperm are more in liquid saliva samples than on mouth swabs. If the victim has spat or rubbed semen on to his/her clothes, these should also be examined using acid phosphatase screening test. Saliva on the suspect's underpants, pubic hairs between the victim's teeth, lipstick and bite marks on the suspect's penis, and transmission of sexual diseases may all be evidence of contact. In oral-vaginal and oral-anal cases, both internal and external swabs should be taken, and the clothing examined.(22)

### **DNA**

Forensic odontology investigators are now more familiar with advanced molecular biology technologies as they need to perform identification in fires, explosions, decomposing bodies and skeletonized bodies.16 Today swabs of the bite marks for DNA can

be matched either from a suspect at the time or by a later speculative search.(2)

The tooth is the most important source to extract DNA. It is a preserved package of DNA protecting it from adverse environmental conditions.(16)

If antemortem data are unavailable, then the precise identification becomes complicated, and only DNA profiling systems can expose the exact identity of a person. DNA extracted from the teeth of an unidentified individual will be compared with DNA isolated from known antemortem samples, such as stored blood, toothbrush, hairbrush, clothing, cervical smear, biopsy, or DNA of a parent or sibling.(16)

In the tooth, dentin and pulp are rich sources of DNA. Sectioning the tooth provides greater access to pulp. Once the tooth is opened, walls of the pulp chamber can be curetted or instrumented with a slow rotary burr. Then pulp tissue can be collected in a wide open sterile tube. In case of dried specimens, the pulp may be mummified parchment-like. After instrumentation, the chamber is best irrigated with buffer. Ultrafiltration of the liquid at the lab will remove the cellular material needed for analysis. (Smith et al. 1993).

DNA can be extracted from the crown body, root tip, and root body. The root body yields the highest quantities of DNA (Gaytmenn and Sweet 2003).

### **Mass disaster**

A disaster may be due to natural causes (meteorological or geological events) or man-made causes (structural failures, transportation failures, crowd surges, fire, explosions, war and terrorism). Disasters may be open or closed, or a combination of both. An open disaster is a situation where there is no immediate tentative identification of the deceased, and there is delay in obtaining ante-mortem data. A closed disaster is where there is a readily available list of possible victims (e.g. a plane crash where there is a passenger list), and ante-mortem comparative data is quickly available. Combined open/closed disasters occur when the disaster is complicated, for example, a plane crash into a residential area.(15)

Identification will rely on comparison between post-mortem dental examination and antemortem dental records. When records are not initially available, then characteristics of the oro-dental structures may be used to indicate age, sex, medical, dental history, etc.(3)

**Antemortem** dental records includes all recorded information including hand written and/or digital clinical information, dental and/or facial radiographs, clinical photographs and dental models, smiling photographs, and also specific information from relatives and friends. Antemortem smiling photographs are very helpful in comparing post-mortem dental findings, such as discoloration, missing, and malformed or misaligned anterior teeth.(3)

**Post-mortem Dental Examination:** Dental examination of the deceased is carried out before comparison with antemortem dental records. The standard procedure is using two dental examiners working together—one clean and one dirty whose aim is to get all relevant information in one examination and avoid re-examination.

#### Role of Dirty Odontologist

1. Photograph facial structures. Retract lips for comparison with antemortem smiling photos.
2. Examine facial skeleton for gross abnormality prior to examining the teeth.
3. Clean teeth with tooth brush and alcohol to remove debris.
4. If avulsed teeth with body, place in correct anatomical position.
5. Photograph jaws and teeth. Photograph dentures/ orthodontic appliances, in and out of mouth.
6. X-ray jaws and teeth.
7. Full dental examination noting teeth present, missing, restorations, occlusion, orthodontic appliances, arch shape, anomalies of tooth position, congenital abnormalities, trauma, and pathology.
8. If orthodontic appliance is worn, take dental impressions in a non-distortable dental impression material.
9. Extract tooth for DNA. Preferably sound, fully developed (closed apices) 2<sup>nd</sup> or 1<sup>st</sup> molar tooth. If not available, then another posterior tooth can be used. Avoid extracting anterior teeth and teeth avulsed post-mortem.(3)

#### Clean Odontologist

1. Process radiographs.
2. Mount radiographs in correct orientation and label with identification number, time and date.
3. Compile dental chart with information from clinical examination and radiographs with accurate representation of the position, size, and shape of any restorations present, in consultation with dirty odontologist.
4. Place tooth extracted for DNA into appropriate, secure container, and label.(3)

#### Dental Reconciliation

The process undertaken by the odontologist of comparing the information obtained in post-mortem clinical dental examination with that contained in the antemortem dental records.

Where antemortem dental records are not available, facial mapping techniques can be employed. These compare facial anatomical points and teeth, utilizing anthropometric measurements and relative proportions or photographic superimposition of an antemortem

smiling photograph with an equivalently positioned post-mortem facial photograph.(3)

Some dental restorations undergo change when exposed to heat. High temperatures cause silver-amalgam fillings to evaporate mercury which could amalgamate superficially with neighbouring gold fillings. Gold shows through the surface upon scratching, and also identified by observing the outline and form of the filling.(19)

Sometimes the dental assistant who fills in the records makes a mistake as to the place and extension of fillings. In most countries dentists are required to keep records for a certain time after treatment. Some dentists throw their records away when the patient has changed to another dentist or if the patient has died. The most dangerous factor is illegibility of the records and sometimes even the dentist himself cannot read the abbreviations used by him or his assistant.

#### Photography

Imaging of the patterned bruise of a bite mark is a variable in the process of bite mark analysis that the investigator can control. The technique and equipment employed by the operator will influence the quality of the photographic evidence.(28)

Forensic photography requires accurate results when depicting an object in its 2D representation. Consistency is required in framing of the object in the centre of the image, the sharpness of the focus and, absence of photographic distortion. Consistency of colour and tonal range are equally important. Care must also be taken to eliminate any unwanted or distracting shadows. High-end digital single-lens-reflex (DSLR) cameras are used to achieve these results, equipped with a range of lenses and separate flash systems.

Colour representation and reproducibility- The same photo image on different monitors can look very different if the monitors are not professionally calibrated. Further variation is produced on printing the digital image: often the printed image does not represent what appears on screen. The latest digital SLR cameras have very high pixel counts.(28)

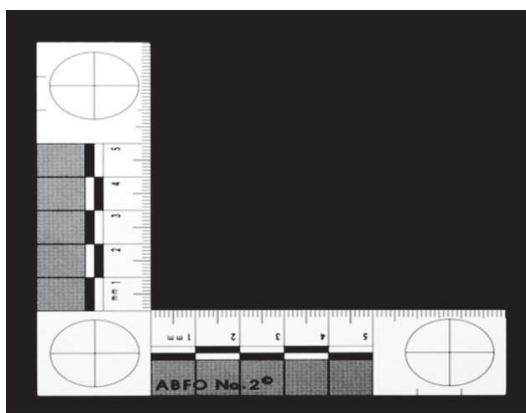
#### Lenses fall into two categories:

- **Prime lenses-** have fixed focal length. A 105mm lens provides fine detail that is needed to demonstrate individual teeth marks accurately. Lens with lower focal length (example- 20 mm), produces noticeable barrel distortion.
- **Zoom lenses-** have a range instead of fixed focal length and are commonly supplied with a camera when sold as a kit. Zoom lenses should be avoided when photographing bite marks because the operator can often change the focal length without realising.(28)

Mobile phones with cameras should be considered a last resort for use in recording patterned injuries such as bite marks. Although they have sensors with large pixel counts, the lenses have short focal lengths. The

lens distortion will reduce the quality of the photographic evidence. Sometimes, a mobile phone may be the only option available to the operator and may provide important information to the investigation.

A rigid scale, such as the ABFO no. 2, L-shaped scale, is essential for photography of any patterned injury. The scale allows the investigator to make consistent measurements of the bruise. Without this scale being placed correctly and photographed with the injury, the subsequent measurements will be subject to error and affect the analysis resulting in inadmissible evidence for court.



It is important to use the same scale when taking photographs of the bite mark and making recordings of the suspect's dental cast, to minimise unwanted measurement error. The scale should have a matt finish to reduce reflection.(28)

### Colour chart

An accurate colour chart is needed when photographing the bite mark to ensure correct colour calibration when using a computer. For consistent results a colour chart should be visible in every image that is taken because slight changes in the distance between the flash and subject will have an influence on brightness within the image and will create slight variance in the colour.



Colour checker chart

### Digital image file formats

The lossless (little compression) type of format used by the camera is either the TIF (Tagged Image File) format or a RAW image format. Many forensic photographers use only RAW files when creating photographic evidence. Thus integrity of the evidence is maintained as all original data is reconstructed faithfully at all stages in the workflow, from viewing to archiving of the image.

The JPEG file format uses a heavier compression, meaning that, to reduce the size (in megabytes), parts of the data from the image file are removed. The JPEG format can introduce changes to the appearance of the image itself. Artefacts can appear around the edges of an object in the digital image. If image enhancement is needed, then further loss of detail is introduced. Changes brought about by image compression may cause issues for the forensic investigator when analysing the images.(28)

To preserve the continuity of the sequence all images must be kept. There is no acceptable reason to delete images; even if some images do not depict important information, the continuity of the sequence should be preserved.

Using of a ring flash is recommended for intraoral photography. Flash devices positioned on top of the camera or to one side will cause shadows to fall over parts of the dentition and obscure information.(28)

### Evidence

A forensic scientist examining a crime scene for fingerprints can provide information about the circumstances in which any fingerprints were obtained, and also be permitted to explain whether the fingerprints match those of the defendant.(5)

Expert witnesses are permitted to rely on the words, thoughts and views of others, and can base their opinions on the published and unpublished material of others (including books, journals and research papers), as well as their own training and experience. Expert evidence is given in two ways, via written report and oral evidence.(5)

### Important points

Much attention has been given lately to the incorporation of specific identity marks in dentures. These would be of great value in the armed forces, fire and police services, airline crews and residents in homes for the aged or mentally ill. Even though the denture bears an identifying mark it does not necessarily mean that it belongs to a particular body; it may have to be shown to fit the mouth of that body or casts made from it. But cast partial dentures may be quite unique in this respect, being specially designed for one person and that person only.(22)

Immersion in water may result in the loss of single root canal teeth from decomposition of their periodontal attachments, but multi-rooted teeth remain because of

their divergent roots. Even in these cases some information can sometimes be gained by carefully examining the empty sockets. These may indicate unusual position of teeth, recent extraction or evidence of chronic infection.(22)

The position of the epithelial attachment relative to the cemento-enamel junction can often be seen and may give an idea of age in terms of young or old. Teeth also bear marks of some systemic disturbances which have occurred during their formation in the form of accentuated Striae of Retzius in enamel or Contour Lines of Owen in dentine. These may correspond with a medical history or be used, by matching sections under a comparison microscope, to determine whether two or more isolated teeth belong to one or more than one body. Other small details which can sometimes provide useful clues are hypoplastic defects, possibly related to a medical history, patterns of attrition, especially unusual ones which may be related to occupation or a particular habit such as pipe smoking. Calculus and gingival conditions may also be noted.(22)

### Conclusion

Forensic odontology is an art and few people have the patience and time to study, research and plan as meticulously as required in this field. This is hugely satisfying for those who would like to see the perpetrators of crime be given justice and punished through concrete evidence to seal their fate. This field is well established in a few countries and is part of a larger team comprising of medical personnel. In India forensic odontology is growing by leaps and bounds and therefore more research and study by dentists is required.

**Conflict of Interest: None**

**Source of Support: Nil**

### References

- 3D Imaging in Forensic Odontology- Sam Evans, Carl Jones, Peter Plassmann - Journal of Visual Communication in Medicine , June 2010; Vol. 33, No. 2, pp. 63-68.
- A brief history of Forensic odontology since 1775. Robert Michael Bruce- Journal of Forensic and Legal Medicine 17 (2010) 127-130.
- A Pathologist's Guide to Forensic Odontology. Identification Catherine M.T. Adams.
- Accuracy of age estimation methods from orthopantomograph in Forensic odontology: A comparative study. Manisha M. Khorate a, A.D. Dinkar, Junaid Ahmed. Forensic Science International 234 (2014) 184.e1-184.e8.
- Acting as an expert witness -Jason Tucker -Centre for Professional Legal Studies, Law School, Cardiff University, UK.
- Advanced Technologies in Forensic Odontology. B. Rai, J. Kaur, Evidence-Based Forensic Dentistry, Springer-Verlag Berlin Heidelberg 2013.
- J. Forens. Sci. Soc. (1971), 11, 223. An Identification by means of Forensic odontology. The Mearns (Garvie) Murder N. W. Kerr, j. M. Murray.
- Forensic Science International, 29 (1985) 259-267. Application of aspartic acid racemization to forensic odontology: post mortem designation of a great death. Tsuneko Ogino, T Hiboshi Ogino, Bartholomew Nagy.
- Bite Marks- I. Douglas R. Sheasby. Forensic Odontology: An Essential Guide, First Edition. 2014 John Wiley & Sons, Ltd.
- Bite Marks-II. Roland Kouble. Forensic Odontology: An Essential Guide, First Edition. 2014 John Wiley & Sons, Ltd.
- Cheiloscopy in identification. Forensic Odontology. B. Rai, J. Kaur, Evidence-Based Forensic Dentistry. Springer-Verlag Berlin Heidelberg 2013.
- Dental age assessment. Sakher Al Qahtani. Forensic Odontology: An Essential Guide, First Edition. 2014 John Wiley & Sons, Ltd.
- Denture marking. Forensic Odontology aspects. B. Rai, J. Kaur, Evidence-Based Forensic Dentistry. Springer-Verlag Berlin Heidelberg 2013.
- Development of the dentition. Alastair. J. Sloan. Forensic Odontology: An Essential Guide, First Edition. John Wiley & Sons, Ltd.
- Disaster victim identification. Catherine Adams. Forensic Odontology: An Essential Guide, First Edition. 2014 John Wiley & Sons, Ltd.
- DNA technology and Forensic Odontology. B. Rai, J. Kaur, Evidence-Based Forensic Dentistry. Springer-Verlag Berlin Heidelberg 2013.
- Forensic odontology - identification by dental means. Sydney Levine, M.D.S., F.R.A.C.D.S. Australian Dental Journal, December, 1977 48 1 Volume 22, No. 6.
- Handbook of Forensic Medicine, First Edition. 2014 John Wiley & Sons, Ltd.
- Forensic Odontology. Gosta Gustafson Australian Dental Journal, August, 1962.
- I. J. Med. Sc. Eighth Series. Vol. March, 1970 3. NO. 3. Forensic Odontology with case report. John F. Owens.
- Forensic Science Society 1988.
- Forensic odontology for the general practitioner. Frank R. Shroff,- Australian Dental Journal, Oct.-Dec. 1973
- Forensic Odontology: History, scope and limitations. B. Rai, J. Kaur, Evidence-Based Forensic Dentistry, Springer-Verlag Berlin Heidelberg 2013.
- Forensic Odontology in the management of Bioterrorism. B. Rai, J. Kaur, Evidence-Based Forensic Dentistry, Springer-Verlag Berlin Heidelberg 2013.
- Forensic Sci Med Pathol (2012) 8:148-156. Forensic odontology involvement in disaster victim identification. John William Berketa, Helen James, Anthony W. Lake.
- Forensic Science International 130 (2002) 174-182 Forensic odontology lessons: multi shooting incident. At Port Arthur, Tasmania Paul T.G. Tylora, Marie E. Wilsona, Tim J. Lyons.
- Forensic photography and imaging. Sam Evans. Forensic Odontology: An Essential Guide, First Edition.