

Content available at: <https://www.ipinnovative.com/open-access-journals>

International Journal of Oral Health Dentistry

Journal homepage: [www.ijohd.org](http://www.ijohd.org)

## Case Report

# Subcutaneous emphysema as a complication of tooth extraction: Case Report

Ayu Vidya Putri<sup>1,\*</sup>, Seto Adiantoro<sup>2</sup>, Harmas Yazid Yusuf<sup>1</sup>

<sup>1</sup>Dept. of Oral and Maxillofacial Surgery, Faculty of Dentistry Universitas Padjadjaran, Bandung, Indonesia

<sup>2</sup>Dept. of Oral and Maxillofacial Surgery, Dr. Hasan Sadikin Hospital, Bandung, Indonesia



### ARTICLE INFO

#### Article history:

Received 14-02-2022

Accepted 05-03-2022

Available online 23-03-2022

#### Keywords:

Iatrogenic

Tooth extraction

### ABSTRACT

Subcutaneous emphysema is an uncommon complication of dental procedures. This complication arises when air forced beneath the tissue. In dentistry it may appear with the use of high-speed bur and could cause a serious complication including airway obstruction. This case report highlights a complication during dental procedure to give information for the clinician the factors, diagnosis, and management of subcutaneous emphysema. A 33 years old male patient with difficulty in breathing and swelling at right lower jaw, neck and chest region. The swelling occurred about 2 hours before admission during tooth extraction of second right lower molar using a high-speed bur about 30 minutes, then he started to feel difficulty in breathing with swelling at right lower jaw, neck and chest region occurred and pain. Then he was transferred to Hasan Sadikin Emergency Department for further treatment. The patient was diagnosed with subcutaneous emphysema at right lower jaw, neck and chest region due to suspect iatrogenic. The management of this patient was conservative treatment with oxygenation 3 lpm, close observation vital sign and wide emphysema, IVFD ringer lactate 1500 cc/ 24 hours, medication with Ceftriaxone 1 gr, Ketorolac 30 mg, Omeprazole 20 mg intravenous and being hospitalized for 4 days. After general condition stable he was performed tooth extraction. Iatrogenic subcutaneous emphysema could be a serious and potentially life-threatening, so dentist has to be more careful while using high-speed bur for tooth extraction.

This is an Open Access (OA) journal, and articles are distributed under the terms of the [Creative Commons Attribution-NonCommercial-ShareAlike 4.0 License](https://creativecommons.org/licenses/by-nc-sa/4.0/), which allows others to remix, tweak, and build upon the work non-commercially, as long as appropriate credit is given and the new creations are licensed under the identical terms.

For reprints contact: [reprint@ipinnovative.com](mailto:reprint@ipinnovative.com)

## 1. Introduction

Subcutaneous emphysema is a condition in which air becomes invaded under the subcutaneous layer of the skin. Subcutaneous emphysema could arise after dental procedure, it is an uncommon complication which caused by the invasion of high-pressure air came out from high-speed hand pieces and air or water from dental syringes. Close observation is required if signs of dysphagia and dyspnea are present. In severe cases it can spread to the neck, mediastinum, and thorax along with the fascial planes, resulting in cervical emphysema, pneumomediastinum, and pneumothorax.<sup>1</sup> Subcutaneous emphysema may become a

complication and life-threatening if accompanied by an infection or air embolism.<sup>2</sup> This type of emphysema may be traumatic, iatrogenic or may occur spontaneously.<sup>3</sup> The clinical diagnosis of cervicofacial emphysema is based on the sudden onset of swelling with crepitation in the absence of erythema, edema, significant tenderness or lymphadenopathy.<sup>4</sup>

Subcutaneous emphysema is the condition when air or other gases penetrate to the skin and submucosa resulting in soft tissue distention.<sup>3</sup> The word emphysema came from the ancient Greek language and means "to blow in".<sup>5</sup> Subcutaneous emphysema in dentistry was first documented in 1900 by a case of a bugle player was playing his instrument after did a dental extraction.<sup>6</sup> Subcutaneous emphysema often associated with head and neck trauma,

\* Corresponding author.

E-mail address: [ayuvidyaput@gmail.com](mailto:ayuvidyaput@gmail.com) (A. V. Putri).

surgical procedures, general anaesthetic or infections. It is a lesser known complication of dental extraction, due to the use of high-speed air- turbine hand pieces causing air, bacteria, oil and debris to be force fully injected into surrounding connective tissue.<sup>7</sup>

In dentistry, the use of dental handpiece which driven by air appears to be the main cause of incidents, appearing in 50% of reported cases.<sup>8</sup> High speed dental handpiece generating air have been documented for associations with subcutaneous emphysema during the surgical removal of teeth and delivery of restorative treatment including direct restorations, crowns, and stainless steel crowns. Instances during endodontic treatment have been reported, an outcome typically linked to air from high-speed handpieces and air syringes. Extrusion of hydrogen peroxide irrigants beyond the apical foramen produces oxygen which can accumulate within tissue compartments to produce emphysema. Air cooling sprays from dental lasers have also been reported as causes where lasers have been used for incision and drainage of abscesses, frenectomies, and periodontal debridement. Procedures for site development prior to dental implants, such as maxillary sinus floor elevations, as well as placement of zygomatic dental implants have also been identified as causes.<sup>9</sup> The appearance of this condition after dental procedures is infrequent, nevertheless due to the advent of high pressure air instruments such as high-speed hand pieces and air syringes, this phenomenon is increasing.<sup>5</sup>

The following report presents a case of subcutaneous emphysema occurred during second molar extraction with the use of an air turbine handpiece. Case management is described and issues relative to the diagnosis and prevention of this surgical complication are discussed.

## 2. Case Report

A 33 years old male patient came with difficulty in breathing and swelling at right lower jaw, neck and chest region. The swelling started occurred about 2 hours before admission during tooth extraction of second right lower molar in private clinic by general practitioner using a high-speed bur for about 30 minutes, then he started to feel pain, followed by difficulty in breathing accompanied with swelling at right lower jaw, neck and chest. Then he was brought to Hasan Sadikin Emergency Department for further treatment. The patient was diagnosed with subcutaneous emphysema at right lower jaw, neck and chest with suspected caused by iatrogenic.

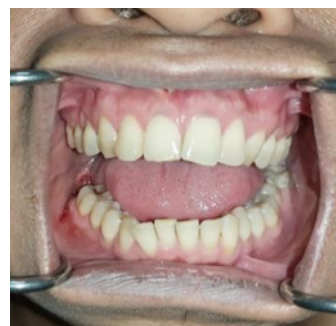Patient came with tachypnea, respiratory rate was 24 times per minute, blood pressure was 120/90 mmHg, heart rate 78 times per minute, sub febrile temperature and Oxygen saturation level was 98%. In general examination, there was asymmetrical face swelling at right lower jaw extended to neck and chest region. In eye examination conjunctiva was non anemic, sclera non icteric, we

found swelling and crepitation in neck region. There was crepitation at intercostal space (ICS) level 2 at right hemithorax and ICS 1 at left hemithorax. In Thorax examination, there was no rhonchi and wheezing, vesicular breathing sound was equal between right and left side of the thorax, and there was crepitation on chest examination.

In extra oral examination (Figure 1) there was an asymmetrical face, swelling at right lower jaw extended to neck and chest region with 8 x 3 x 2 cm, with characteristic of the swelling was localized, no fluctuation, no redness, no febrile temperature on the site of swelling and there was crepitation and pain on palpation. In intra oral examination (Figure 2), there was found hyperemia at gingiva of tooth 47 region, with an open gingiva looked like dissected gingiva and the tooth had not been extracted yet. In examination of lip, tongue, palate, vestibule, floor mouth, buccal mucous, were normal, and tonsil was difficult to be assessed. On clinical examination and panoramic x-ray (Figure 5), we found third molar impaction of teeth 38, pulpitis irreversible of teeth 37, pulpitis reversible of teeth 36, apical periodontitis of teeth 47 and missing of tooth 48. Mouth opening was limited with 1.5 cm, and there was calculus all over region.

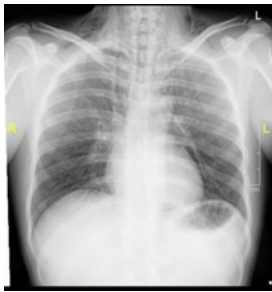

**Fig. 1:** Profile photos of the patient showed clinical condition of the patient first arrived on emergency room



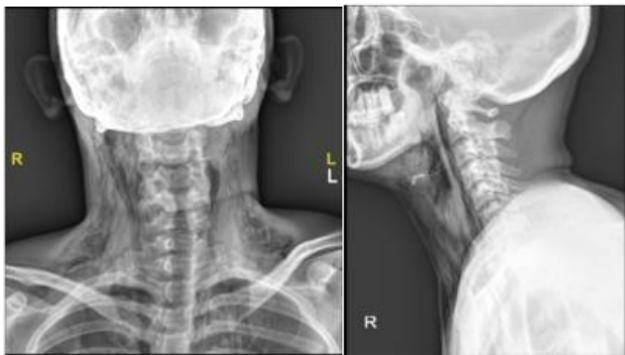**Fig. 2:** Intra oral of the patient, showed unfinished tooth extraction of mandibular second molar and limited mouth opening of the patient

In laboratory finding, hematology was normal, chemical blood component was normal. Covid-19 Screening (Rapid



**Fig. 3:** Thorax x-ray

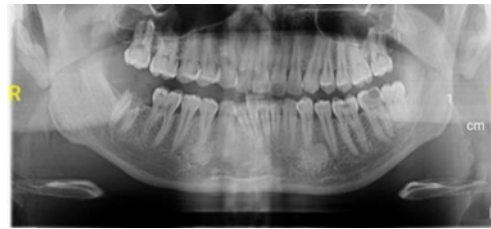
Test) Anti SARS-CoV-2 was non-reactive. In blood gas analysis there was decrease of pO<sub>2</sub> and Saturation. In thorax X- Ray on (Figure 3) there was radiolucency of air density in colli to bilateral shoulder, with impression subcutaneous emphysema at region colli bilateral, there was no bronchopneumonia and cardiomegaly. On neck soft tissue photo on (Figure 4) there was radiolucency with air density at bilateral colli and air column still open.



**Fig. 4:** Radiolucency with air density at bilateral colli in neck soft tissue photo

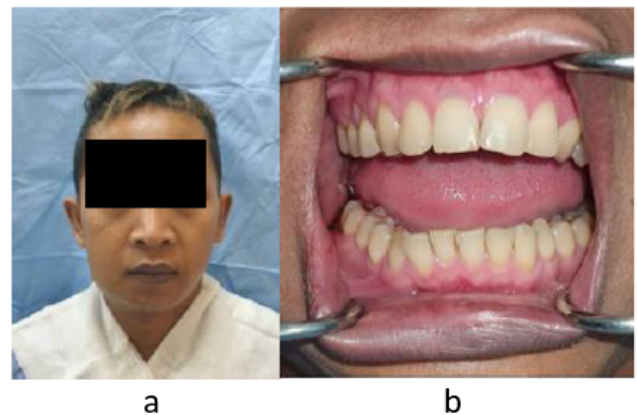
After the patient arrived at emergency room, the patient was examined by several departments, including Cardiothoracic surgery because of the complaint on thoracic area. The diagnoses that resulted from all examinations were subcutaneous emphysema at right lower jaw neck and chest region due to suspect iatrogenic with Apical periodontitis of teeth 47.

Comprehensive management could be carried out after all the results of the examination s were carried out and the diagnosis is established. The management in emergencies includes administration of oxygenation using a nasal canula of 3L / min, observation of vital signs and the wide and spread of emphysema, administration of ringer lactate 1500 cc/ 24 hours, medication with Ceftriaxone 1 gr, Ketorolac 30 mg, Omeprazole 20 mg. After all, actions had been taken, the patient was put into an inpatient room to observe the actions that have been taken and prepare for tooth extraction when condition is stable.



**Fig. 5:** Panoramic x-ray, there was apical periodontitis due to gangrene of pulp tooth 47

After 3 days being hospitalized the patient's condition has been declared stable respiratory rates was normal, the swelling was reduced, the crepitation on colli and chest was reduced, and the patient was performed tooth extraction of tooth 47 by local anesthesia without using a high speed bur and high pressure air interference and then after 24 hours observation after tooth extraction the patient condition was stable (Figure 6) and he was allowed to discharged home, and he was planned to control at outpatient clinic of cardiothoracic surgery department and oral maxillofacial surgery department.



**Fig. 6:** Patient condition after 3 days being hospitalized

### 3. Discussion

Most patients who developed complication subcutaneous emphysema after a dental procedure have only mild to moderate local swelling. However, spread of larger amounts of air into deeper spaces may sometimes caused serious complications.<sup>4</sup> Swelling, dysphagia, chest pain, and crepitus are common signs and symptoms of emphysema and may occur immediately or within a few hours or days of the triggering procedure.<sup>10</sup> On this case, the patient has chief complaint of swelling at left lower jaw extended to neck and chest region, who developed during tooth extraction of right lower mandibular second molar. Patients with subcutaneous emphysema related to dental procedures usually have a history of dental procedures

performed using a device that delivers high pressure, such as a dental handpiece or an air water syringe. Subcutaneous emphysema usually occurs during or immediately after a dental procedure.<sup>10</sup> The patient on this case has a history of dental procedure using high speed bur for 30 minutes. When a pressurized drill is overused or used at an improper angle, it forces pressurized air and unsterile water beneath soft tissue spaces via disruptions in the dentoalveolar membrane. Even when a high-pressure air device is not used, air can be introduced through disruption of the mucosal barrier at the wound or incision site.<sup>3</sup>

There are two different pathways by which high-pressure air invades subcutaneous tissue. First the high pressure generated from the air released by the high speed bur will enter and expand to compress the bone tissue. Especially if there has been damage to the bone in the affected area, which can be caused by pathological lesions or iatrogenic injuries, this will increase the risk of developing subcutaneous facial emphysema. Another which can be the cause of the spread of the high-pressure air path that can be through the periosteal and submucosal tissues. In making the flap, excessive reflection on the mucoperiosteal flap during surgical extraction for example in the third molar surgery with subperiosteal dissection can cause the spread of high air pressure causing subcutaneous emphysema. Weakness of the gingival attachment can also create higher air pressure to invade the subcutaneous soft tissue.<sup>1</sup> Air and water may then dissect along the multiple fascial planes between the mouth and mediastinum, especially near the roots of the molars that directly communicate with the sublingual and retropharyngeal spaces, risking the spread of contaminants.<sup>11</sup> In the present case, gingival tissue of second right lower molar was disrupted during dental procedure then air could have been forced into subcutaneous tissues during tooth sectioning with the high-speed air turbine handpiece.

Air can penetrate the cervical fascial planes and extend to the mediastinum, leading to more life threatening consequences. The presence of pain both in the thorax and in the back, would suggest the presence of mediastinum emphysema, and a chest film to confirm the diagnosis is mandatory.<sup>12</sup> The patient performed thorax and neck soft tissue x-ray on emergency unit and was found radiolucency of air density in colli to bilateral shoulder, with impression subcutaneous emphysema at region colli bilateral, by these modalities we diagnosed the patient with subcutaneous emphysema at right lower jaw, neck and chest region due to suspect iatrogenic.

A differential diagnosis must be made following the sudden onset of swelling in the head and neck region subsequent to a dental procedure. There are four differential diagnoses to consider in addition to subcutaneous air emphysema. Angioedema appears primarily in the maxilla. It is characterized as having well reddened area with a

burning sensation. A hematoma is a pooling of blood outside of the blood vessels and inside the tissues with the absence of crepitus. Anaphylaxis usually has a steep fall in blood pressure with facial symptoms presenting in a profuse and bilateral manner. Cellulitis can present with a central area that has an abscess, a fever, redness, a tight and glossy appearance of the skin and tenderness in the affected area. Subcutaneous air emphysema is a rare but, potentially life-threatening event.<sup>4,13</sup>

Subcutaneous emphysema is usually resorbed spontaneously without complications, which explains why treatment of subcutaneous emphysema is usually symptomatic. Prophylactic antibiotics, close observation of the airway and monitoring the progression of the extension of the gas are recommended.<sup>12</sup> By the literature recommendation from Umberto et al., we administered antibiotics Ceftriaxone 500 mg, for prophylaxis, anti-inflammatory for reducing pain Ketorolac 30 mg and PPIs Omeprazole 40 mg intravenous, we observed the wide of the crepitation and swelling of chest of patient. If migration of the accumulated gas is reported, and imaging shows pneumothorax or pneumomediastinum, or if the patient is in significant distress during the observation time, aggressive treatment such as drainage or chest tubing are necessary.<sup>4</sup>

Prevention of emphysema requires adherence to well-accepted surgical procedures. Mucoperiosteal flap elevation should be minimal and should not extend to the lingual alveolus of the mandibular third molar area. Muscle attachments should be preserved whenever possible.<sup>12</sup> When using a handpiece to section a tooth in preparation for an extraction, it is recommended that the surgeon avoid direct contact between the head of the handpiece and the tooth in an effort to prevent the direct penetration of air into the tissues.<sup>4</sup>

#### 4. Conclusion

From this case report we found a patient who developed subcutaneous emphysema while receiving a dental procedure using high air pressure hand piece. It is an uncommon complication, but spread of larger amounts of air into deeper spaces on this case caused dysphagia that may potentially become a life threatening condition. Appropriate immediate treatment should be performed, with oxygenation, oxygen inhalation through a cannula or mask can promote air absorption and a consideration to administer antibiotic prophylaxis to avoid risk of secondary infection is necessary. On this case the patient was being hospitalized for monitoring general condition and widespread diffusion of emphysema. Symptom improvement was determined by clinical examination for crepitus on palpation at the sites of subcutaneous emphysema.

## 5. Source of Funding

None.

## 6. Conflict of Interest

The authors declare that there are no conflicts of interest regarding the publication of this paper.

## References

1. Lee SW, Huh YH, Cha MS. Iatrogenic subcutaneous cervicofacial emphysema with pneumo mediastinum after class V restoration. *J Korean Assoc Oral Maxillofac Surg*. 2017;43(1):49–52.
2. Jeong CH, Yoon S, Chung SW, Kim JY, Park KH, Huh JK. Subcutaneous emphysema related to dental procedures. *J Korean Assoc Oral Maxillofac Surg*. 2018;44(5):212–9.
3. Toragay A, Aydin E, Cilasun U, Durmaz L, Arslan G. Subcutaneous emphysema after dental treatment: A case report. *Paediatr Anaesth*. 2006;16(3):314–7.
4. Julia F, Roland W. Soft tissue cervicofacial emphysema after dental treatment report of 2 cases with emphasis on the differential diagnosis of angioedema. *Arch Dermatol*. 2005;141(11):1437–40.
5. Vidal CAG, Pizarro CAV, Arriagada AA. Subcutaneous emphysema secondary to dental treatment: Case Report. *Med Oral Patol Oral Cir Bucal*. 2007;12:76–8.
6. Ikuko A, Takayuki A, Hiroshi Y, Yooshihide O, Akihiro K. Pneumomediastinum and subcutaneous emphysema after dental extraction detected incidentally by regular medical checkup: a case report. *J Tripelo*. 2019;.
7. Tan S, Nikolarakos D. Subcutaneous emphysema secondary to dental extraction: A case report. *Aust Dent J*. 2017;62(1):95–7.
8. William JM. Subcutaneous air emphysema in dentistry. *Biomed J Sci Tech Res*. 2018;6(1):4931–3.
9. Raoul J. Management of subcutaneous facial emphysema secondary to a class V dental restoration. *Clin Case Rep*. 2019;7(5):1025–30.
10. Gabrielle B, Serena A, Andrea C. Massive Cervicothoracic Subcutaneous Emphysema and Pneumomediastinum Developing during a Dental Hygiene Procedure. *Case Rep Dent*. 2017;2017:7016467. doi:10.1155/2017/7016467.
11. Brzycki RM. A case report: subcutaneous emphysema and pneumomediastinum following dental extraction. *Clinical Practice and Cases. Clin Pract Cases Emerg Med*. 2021;5(1):58–61.
12. Umberto R, Galanakis A, Lerario F, Daniele GM, Tenore G, Palaia G. Subcutaneous emphysema during third molar surgery: a case report. *Braz Dent J*. 2011;22(1):83–6.
13. Chen SC, Lin FY, Chang KJ. Subcutaneous emphysema and pneumomediastinum after dental extraction. *Am J Emerg Med*. 1999;219(7):678–80.

## Author biography

**Ayu Vidya Putri**, Resident

**Seto Adiantoro**, Staff of Dept. of Oral and Maxillofacial Surgery

**Harmas Yazid Yusuf**, -HOD

**Cite this article:** Putri AV, Adiantoro S, Yusuf HY. Subcutaneous emphysema as a complication of tooth extraction: Case Report. *Int J Oral Health Dent* 2022;8(1):67-71.