

Content available at: <https://www.ipinnovative.com/open-access-journals>

International Journal of Oral Health Dentistry

Journal homepage: www.ijohd.org

Case Report

Furcal perforation repair using MTA — A clinical case series

Reshma Dodwad¹, K. N. Raghu², Mithun J Kaslekar², Vikram Shetty³, Alwin Antony⁴,
Ummey Salma⁵, Avineet Kaur^{6,*}

¹Dept. of Pedodontics & Preventive Dentistry, Krishnadevaraya College of Dental Sciences and Hospital, Bengaluru, Karnataka, India

²Dept. of Conservative Dentistry & Endodontics, S J M Dental College and Hospital, Chitradurga, Karnataka, India

³Dept. of Conservative and Endodontics, Al Badar Rural Dental College & Hospital, Gulbarga, Karnataka, India

⁴Dept. of Pedodontics, K V G Dental College & Hospital, Sullia, Karnataka, India

⁵Dept. of Pediatric and Preventive Dentistry, Ramaiah University of Applied Sciences, Bengaluru, Karnataka, India

⁶Dept. of Periodontology, Swami Devi Dyal Dental College and Hospital, Golpura, Haryana, India



ARTICLE INFO

Article history:

Received 22-05-2021

Accepted 02-08-2021

Available online 24-09-2021

Keywords:

Furcal perforations

MTA

MTA Bio

Endodontic retreatment

Healing

ABSTRACT

The success of any endodontics therapy depends on, the diagnosis, treatment planning, access cavity preparation, maintenance and shaping following the canal obturation. Access is the initial and mainly crucial point of root canal treatment. For a good endodontic results well-designed access preparation is required. Perforations are a possible complication during root canal treatment. An assortment of materials including, calcium hydroxide, amalgam, glass ionomer, zinc oxide–eugenol and resin modified GI are being used for perforations. The idyllic material for treating perforations should be radiopaque and nonabsorbable. Mineral trioxide aggregate (MTA) with distinctiveness are as with high-quality outcomes in repair perforations. The idea of this case series is to explain the handling of furcal perforation.

This is an Open Access (OA) journal, and articles are distributed under the terms of the [Creative Commons Attribution-NonCommercial-ShareAlike 4.0 License](https://creativecommons.org/licenses/by-nc-sa/4.0/), which allows others to remix, tweak, and build upon the work non-commercially, as long as appropriate credit is given and the new creations are licensed under the identical terms.

For reprints contact: reprint@ipinnovative.com

1. Introduction

Perforation in the floor of the pulp chamber of multirooted teeth causes an inflammatory response in the periodontium, which can lead to irreversible loss of periodontal attachment in the area.¹ Pulp chamber perforations consist of internal or external root resorption, large carious lesion, and iatrogenic damages are some of the etiological factors involved.²

The alteration of furcation perforation can be attained by intracoronary or surgical approach. The root perforation can be treated surgically, a surgical attempt will often lead to pocket formation, loss of attachment, and periodontal furcation involvement.³

The prognosis may be questionable if radicular furcation is involved, but on the other hand the prognosis is usually good if diagnosed accurately and treated with a good material.⁴ The prognosis is related more with the size, contamination location of the lesion.⁵ The main principle of conservative furcal perforation treatment is to seal the defect with filling material as soon as possible.⁶

Mineral trioxide aggregate (MTA) was brought into market for the repairing lateral perforations by Loma Linda University in 1993.^{7,8} Various clinical applications such as management of Apexogenesis/apexification, internal root resorption, pulpotomy, repair of the root, pulp capping, and furcation perforations. MTA promotes dental tissue regeneration.⁹ MTA is offering better microleakage safeguard than traditional endodontic repair.¹⁰

* Corresponding author.

E-mail address: kauravineet85@gmail.com (A. Kaur).

Researcher also established and observed some new cementum development adjacent to MTA which proves it to be superior than other endodontic materials. Thus making MTA is considered as a gold standard because of its unsurprising periodontal ligament (PDL) regeneration.¹¹ In this case series, 3 cases are described in which MTA was used to repair furcation perforation. Thus cases illustrate the potential benefits of MTA.

2. Case Series

2.1. Case 1

A 35-yr-old female patient reported to the dental clinician having chief complain of pain in her lower left back region since one month. On clinical examination a temporary dressing was observed with respect to 36, on percussion there was a pain. Restorative material was eliminated perforation was made and investigated clinically and radiographically. The mesial and the distal canals were cleaned and shaped in a crown down technique using ProTaper Rotary File Systems and with plentiful irrigation using 5.25% sodium hypochlorite and finally with 2% Chlorhexidine . Obturated with gutta-percha points and AH Plus using lateral condensation technique after selecting master cone. The perforation was sealed with mineral trioxide aggregate. In next appointment, MTA was applied and the tooth was temporary filled with Cavit temporary restoration material.

The patient was again rechecked after 24 hours to the department and it was found that there no signs or symptoms. Temporary sealing materials were removed and in this appointment, permanent restoration was done using Type GIC. In another appointment a full metal crown was given.

Radiographically there is an evidence of bone formation adjacent to the MTA on three months with 6 months after treatment, radiography there was an osseous healing at the apex and the furcation

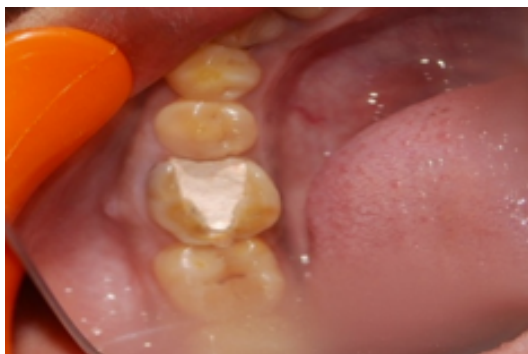

Fig. 1: Pre operative

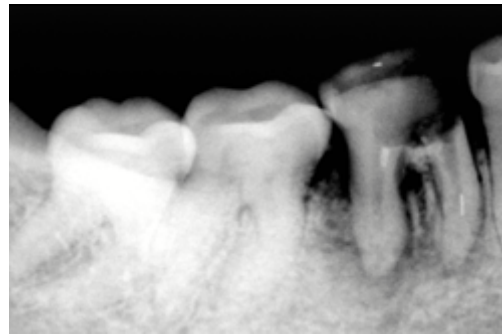


Fig. 2: Caries excavation done

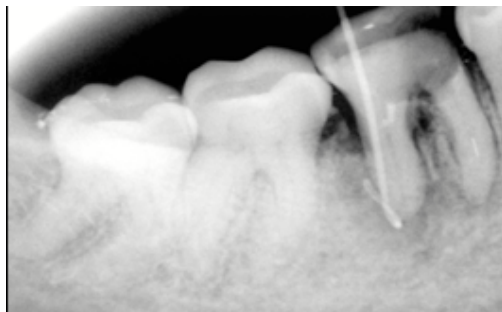

Fig. 3: Radiograph showing sinus tracing

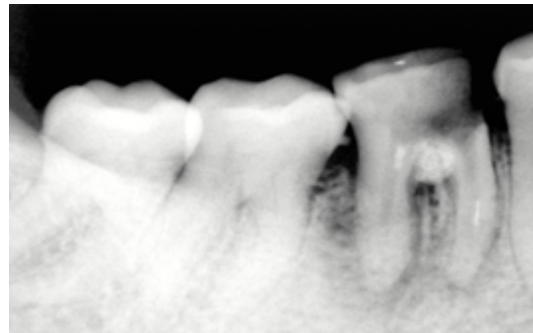


Fig. 4: MTA placement done

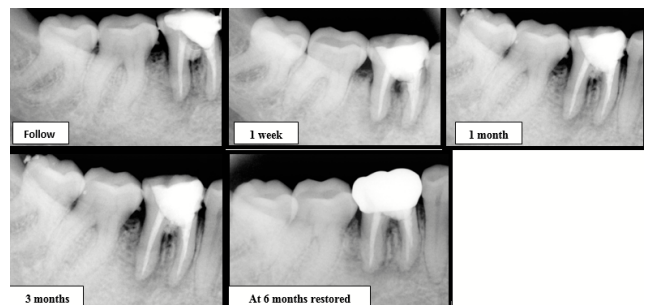


Fig. 5: Root canal therapy completed

2.2. Case 2

A fit and fine 27-Yr-old woman came to the clinic with a history of incomplete root canal treatment 6 months back associated with pain in the lower back region.

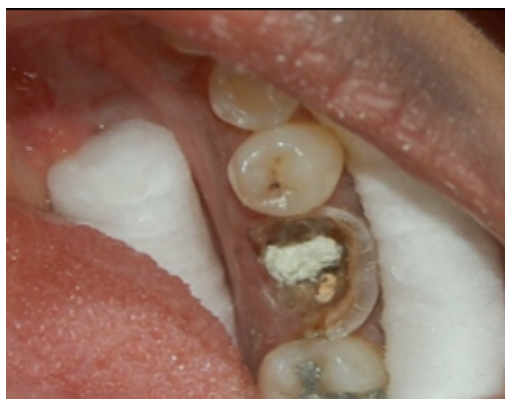

Fig. 6: Obturated 36 with extensive caries and furcal perforation

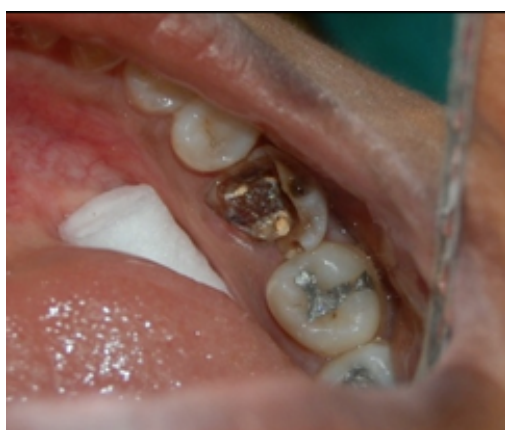

Fig. 7: Furcal defect sealed with MTA

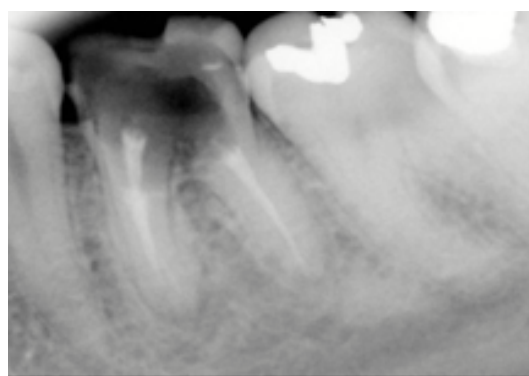


Fig. 8: Radiograph showing root canal treated tooth with furcal defect

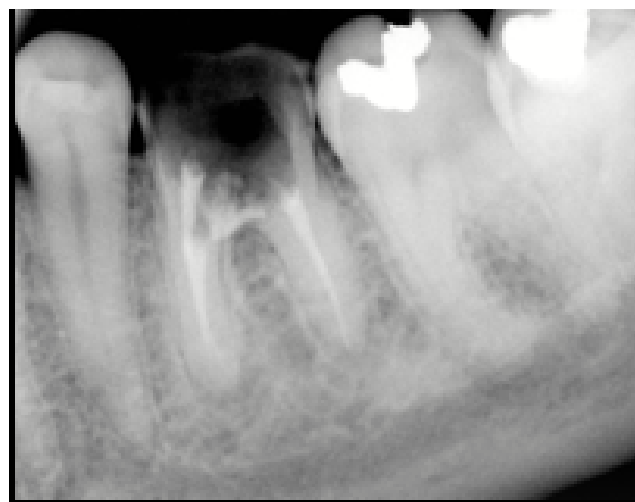

Fig. 9: Furcal defect sealed with MTA

On clinical examination it was observed there was no sensitivity on percussion and palpation. Radiographically a little radiolucent area in furcal region with respect to 36 was observed. The caries and temporary restoration was eliminated.

Hemorrhage was restricted with plentiful irrigation with 1% sodium hypochlorite. The working lengths were determined with Raypex 5. The mesial and distal canals were cleaned and shaped in a crown-down technique using ProFile ISO files and plentiful irrigation with 5.25% sodium hypochlorite was done.

The root canals were obturated with gutta-percha points and AH 26 using the lateral condensation technique. MTA was then placed in the pulp chamber and the tooth was temporary Cavit temporary restoration material was filled. The patient recalled to the clinic three days later with no signs or symptoms. Now in another scheduled time, permanent restoration was done with the help of composite resin, in another appointment a full metal crown was given.

2.3. Case 3

A 21-year female patient visited a dental clinic with grievance of pain on chewing and history of root canal treatment and crown 6 months before her visit.

Several treatment options were disclosed to patient, among which patient opted for RCT along with repair of the perforation with MTA. The furcal perforation was definite by periapical radiography with respect to 46. RCT was completed, and irrigated with 1% sodium hypochlorite. Grey MTA was applied. Radiographically when observed after ten days, the patient had no symptoms. After 6-month follow-up, a bone formation was evident.

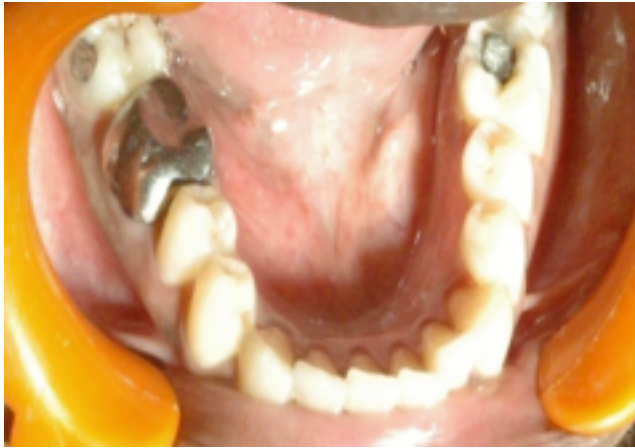

Fig. 10: Preoperative with crown

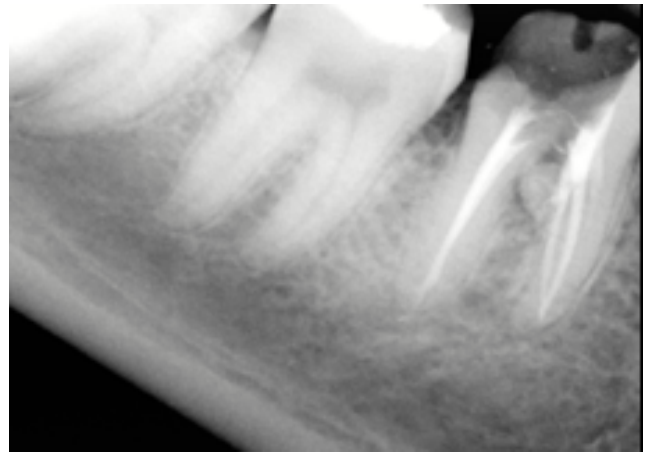

Fig. 13: Obturation was redone

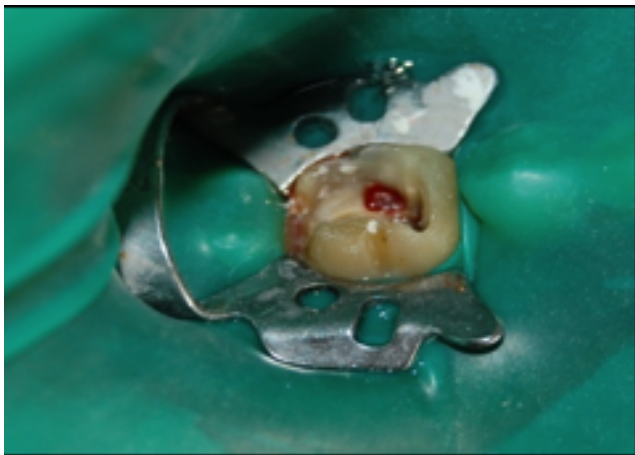

Fig. 11: Perforation site with bleeding

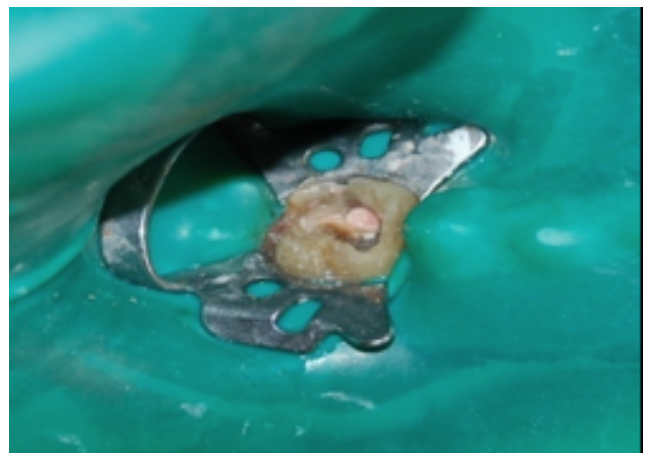


Fig. 14: Furcal perforation sealed with MTA

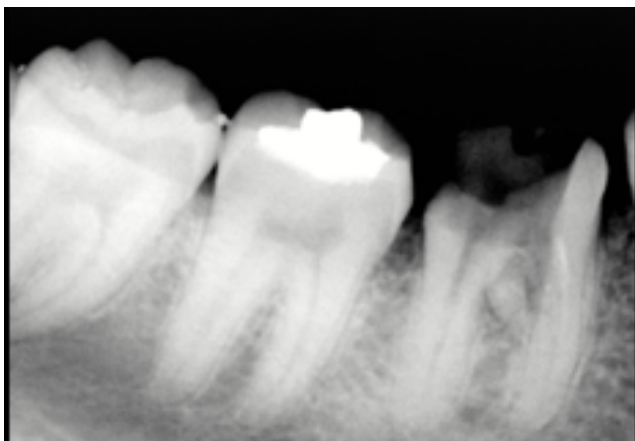


Fig. 12: Perforation site sealed with MTA

3. Discussion

Furcal perforation is unwanted trouble which occur during RCT or post preparation. Equally, a danger of perforation may take place during elimination of affected tissue in a patient with caries that involves pulpal chamber. For ensuring a positive prognosis a situation should be addressed quickly and immediately.¹² In the above 3 cases discussed , the problem was resolute without delay by application of MTA.

Main et al. used a material which has superb sealing properties (MTA) for 16 cases of perforation repair and found out that the material is very appropriate for repair of such perforations. Ferris and Baumgartner and in another study Hamad et al. also compared white and grey MTA and came to a conclusion that there was no disparity in their capability to seal perforations. On the other hand they established that significantly there was more leakage from an orthograde approach as compared with retrograde approach when perforations were repaired.³

Retention capacity of the MTA can be reduced so contamination should be avoided. Previous literature have declared that contact with adjoining tissues may boost the sealant capacity of MTA, as tissues have acidic environment which enhance this property. In the cases presented above, sealing of the lesions could be practical.¹⁰ To put off overfilling or underfilling, one can use a resorbable collagen matrix before MTA application, depending upon on the size of the lesion. Although at hand, there is no size classification for furcal lesions to verify suitable treatment and prognosis so, all options are considered to have a fortified prognosis.¹²

4. Conclusion

Although use of MTA has been reported but literature on its success is restricted. Three familiar clinical presentations of perforation with relation to caries have been described above here. Even though the prognosis is better in case of smaller lesions MTA treatment is observed when radio graphically observed with good prognosis.

5. Source of Funding

None.

6. Conflict of Interest

None.

References

1. Samiee M, Eghbal MJ, Parirokh M, Abbas FM, Asgary S. Repair of furcal perforation using a new endodontic cement. *Clin Oral Investig.* 2010;14(6):653–8.
2. Bryan EB, Woollard G, Mitchell WC. Nonsurgical repair of furcal perforations: a literature review. *Gen Dent.* 1999;47(3):274–82.
3. George S, Shivanna V, Dhanyakumar NM. Calcium phosphate cement: A new saviour for furcation perforation? - An in-vitro study. *Endodontology.* 2006;18:7–11.
4. Tsesis I, Fuss Z. Diagnosis and treatment of accidental root perforations. *Endod Top.* 2006;13(1):95–107. doi:10.1111/j.1601-1546.2006.00213.x.
5. Fuss Z, Trope M. Root perforations: classification and treatment choices based on prognostic factors. *Endod Dent Traumatol.* 1996;12(6):255–64. doi:10.1111/j.1600-9657.1996.tb00524.x.
6. Ruddle JC, Hargreaves KM, Berman LH. Nonsurgical endodontic retreatment; 2002. p. 919. Available from: https://www.endoruddle.com/tc2pdfs/49/NSRCTOverview_Jun2004.pdf.
7. Lee SJ, Monsef M, Torabinejad M. Sealing ability of a mineral trioxide aggregate for repair of lateral root perforations. *J Endod.* 1993;19(11):541–85. doi:10.1016/S0099-2399(06)81282-3.
8. Deus GD, Reis C, Brandão C, Fidel S, Fidel RA. The ability of Portland cement, MTA, and MTA Bio to prevent through-and-through fluid movement in repaired furcal perforations. *J Endod.* 2007;33(11):1374–7. doi:10.1016/j.joen.2007.07.024.
9. Torabinejad M, Chivian N. Clinical application of mineral trioxide aggregate. *J Endod.* 1999;25(3):197–205. doi:10.1016/S0099-2399(99)80142-3.
10. Duarte MA, Demarchi AC, Yamashita JC, Kuga MC. Fraga Sde C. pH and calcium ion release of 2 root-end filling materials. *Oral Surg Oral Med Oral Pathol Oral Radiol Endod.* 2003;95(3):345–7. doi:10.1067/moe.2003.12.
11. Hashem AAR, Hassanian EE, Proroot M. MTA-Angelus and IRM Used to Repair Large Furcation Perforations: Sealability Study. *J Endod.* 2008;34(1):59–61. doi:10.1016/j.joen.2007.09.007.
12. Fuss Z, Trope M. Root perforations: classification and treatment choices based on prognostic factors. *Endod Dent Traumatol.* 1996;12(6):255–64. doi:10.1111/j.1600-9657.1996.tb00524.x.

Author biography

Reshma Dodwad, Reader

K. N. Raghu, Professor

Mithun J Kaslekar, Senior Lecturer

Vikram Shetty, Reader

Alwin Antony, Senior Lecture

Ummey Salma, Research Scholar

Avineet Kaur, Senior Lecturer

Cite this article: Dodwad R, Raghu KN, Kaslekar MJ, Shetty V, Antony A, Salma U, Kaur A. Furcal perforation repair using MTA — A clinical case series. *Int J Oral Health Dent* 2021;7(3):226-230.