



## Case Report

# Rehabilitating anterior teeth esthetically with ceramic laminate veneers

Neeti Solanki<sup>1</sup>, Sunit Kumar Jurel<sup>1,\*</sup>, Pooran Chand<sup>1</sup>, Raghuwar Dayal Singh<sup>1</sup>

<sup>1</sup>Dept. of Prosthodontics, King Georges Medical University, Lucknow, Uttar Pradesh, India



### ARTICLE INFO

#### Article history:

Received 23-10-2020

Accepted 24-12-2020

Available online 21-04-2021

#### Keywords:

Laminate veneers

Ceramic veneers

Minimal tooth preparation

Direct esthetic restorative treatment

### ABSTRACT

Restoration of an unaesthetic smile can be accomplished by various treatment approaches, indirect and direct. However, use of direct treatment modalities such as laminate veneers ensures minimal loss of tooth tissue, along with, pleasing final result which increases the acceptability of the treatment by the patient. Ceramics have been proved superior to composites for laminates, owing to increased strength, abrasion resistance and color stability. In this case report, anterior maxillary discolored dentition is restored by using ceramic laminate veneers.

© This is an open access article distributed under the terms of the Creative Commons Attribution License (<https://creativecommons.org/licenses/by/4.0/>) which permits unrestricted use, distribution, and reproduction in any medium, provided the original author and source are credited.

## 1. Introduction

Diastema, discoloration or malformed shape of the anterior teeth can be esthetically unpleasant and unacceptable to the patient and may affect the patient psychologically if not managed. These conditions can be managed by either direct or indirect esthetic restorative treatment approaches. Advantages of direct restoration with composite resin are simplicity of the technique, preservation of tooth structure, minimal cost as well as reversibility.<sup>1</sup> However, when extensive tooth reconstruction is required, failure rates of composites can average as high as 2.9% annually.<sup>2</sup> The failure can be attributed to marginal defects,<sup>3</sup> secondary caries, fracture of the restoration, or a high degree of color instability.<sup>4</sup> Ceramics have emerged as a desirable option for indirect esthetic restorative procedures,<sup>5,6</sup> especially in the form of veneers.<sup>5,7</sup> This is due to a superior compressive strength, surface smoothness, abrasion resistance, gloss, and low plaque accumulation seen with ceramics.<sup>8,9</sup> Minimally invasive preparations required for laminate veneers or a minimum reduction has emerged as a successful treatment modality owing to the less invasive nature of this approach. The choice of minimal or no tooth preparation is a key factor

in the prognosis. Satisfactory esthetic outcome is obtained with ceramic laminate veneers of minimum thickness along with superior biocompatibility.

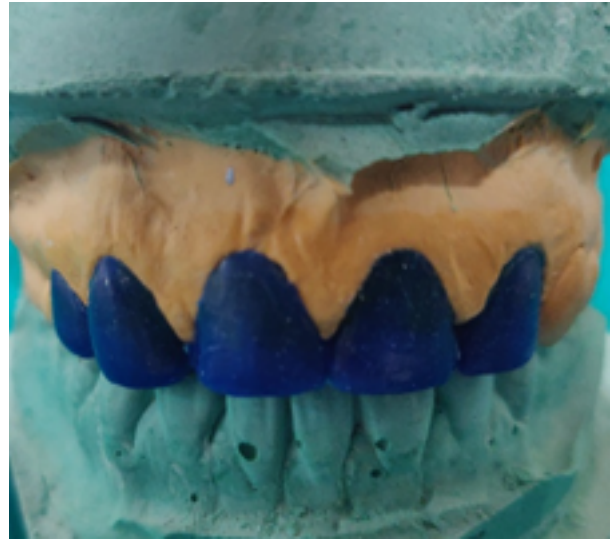## 2. Case Report

A 23-year-old female reported to the department of Prosthodontics, with the complaint of unaesthetic appearance due to discolored anterior teeth. Clinical examination revealed, carious and discolored maxillary anterior teeth along with spacing between 12 11 21 22 (Figure 1). The attempt at obliterating the spacing, between 11 and 21, with composite was noted. Both sides maxillary canines were found to be congenitally missing. Considering the age, the spacing along with the esthetic demands of the patient, composite veneers were planned for the patient. To begin with, the radiographic and photographic records from the patient were obtained and primary impression for both the arches were made with irreversible hydrocolloid. Prior to the tooth reduction procedure, a preliminary wax up and mock-up of the anterior 14 12 11 21 22 was done for proper treatment planning and to visualize the final contour of the veneers (Figure 2). Also, the diagnostic wax up helps in the fabrication of an index, which can later guide the tooth reduction as well as assist in the fabrication of provisional.

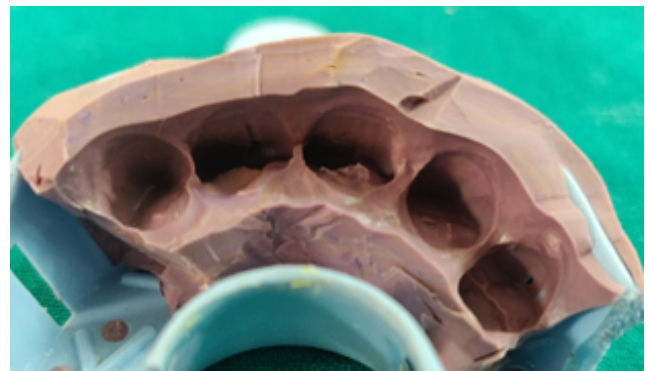
\* Corresponding author.

E-mail address: [sunitkgmc1977@gmail.com](mailto:sunitkgmc1977@gmail.com) (S. K. Jurel).

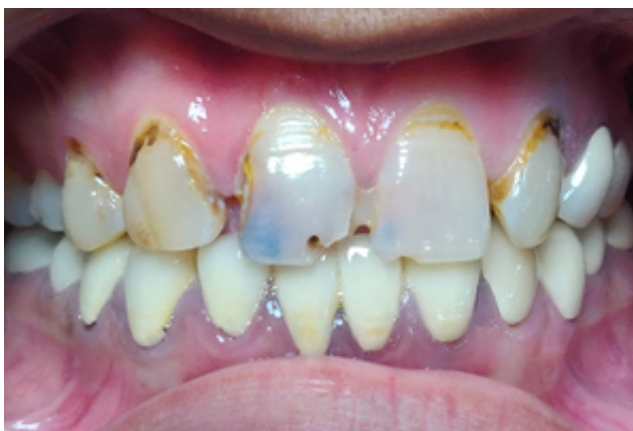Patient's approval was taken for the final treatment plan. Following the mock-up, the space available for the veneers and the path of insertion is checked and the areas requiring preparation are marked on the dental stone model. A silicon index was then fabricated (Figure 3). For ceramic veneers, the minimum required thickness is approximately 0.3 to 0.5 mm on the buccal surface, and 1.5 mm on the incisal edge. A conservative preparation of the enamel was performed on maxillary teeth in question, using diamond burs in a conventional manner (Figure 4). Following preparation, gingival displacement was achieved using retraction cord (#000 and #00). The retraction cords were removed after five minutes and the impression was made with polyvinyl siloxane impression material. Shade matching was done using the shade guide (VITA, 3D Master) and the ceramic shade was designated as A1. The glass-ceramic lithium disilicate was used for the fabrication of the laminates in the laboratory (IPS e.max Press, Ivoclar Vivadent). The final prosthesis was evaluated in the patient's mouth for proximal and cervical adaptation, periodontal relation, colour, form and function (Figure 5). Detrimental contacts during various movements are removed, if any. Prior to final cementation, the resin cement with appropriate shade was selected followed by etching the internal surface of veneers using 9.5% hydrofluoric acid for 20 seconds. The enamel of the prepared teeth was treated with 37% phosphoric acid for 30 seconds (Total Etch, Ivoclar Vivadent). The veneers were then silanized with a silane coupling agent (Monobond Plus, Ivoclar Vivadent). Dual cure resin cement was used for final cementation. Excessive cement was removed prior to curing the cement. The final step was to verify occlusal contacts, and protrusive & lateral movements were checked.



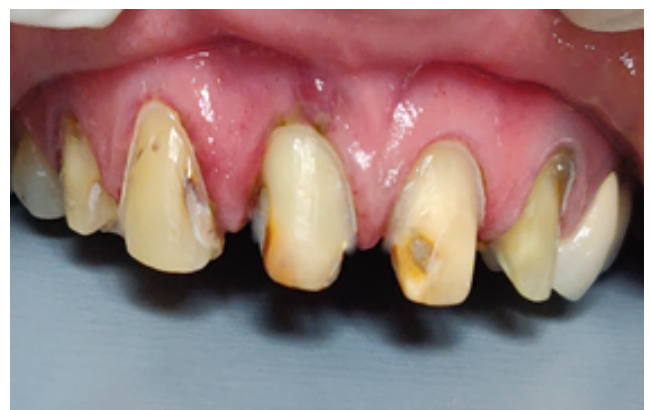**Fig. 2:** Diagnostic wax-up and mock-up



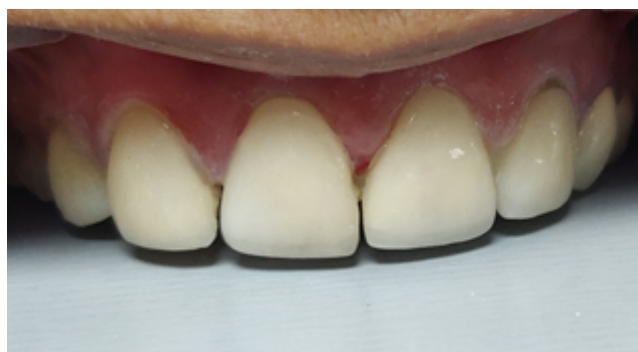**Fig. 3:** Silicone putty index



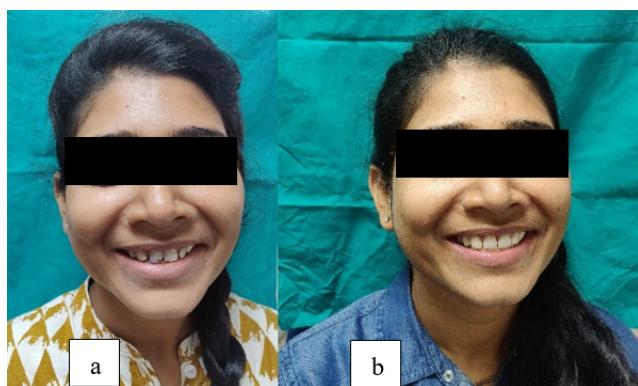**Fig. 1:** Clinical intraoral examination showing discolored maxillary anterior teeth with diastema between 12 & 11 and 21 & 22



**Fig. 4:** Minimally prepared 14 12 11 21 22 for receiving laminate veneers



**Fig. 5:** Laminates checked in the patient's mouth for form, function and occlusion



**Fig. 6:** a: Pre op clinical; b: Post op clinical

### 3. Discussion

Restoring fractured, malformed, mal-aligned or discolored anterior teeth can be accomplished by various treatment approaches. Porcelain laminates and sectional veneers has emerged as a superior alternative to conventional prosthetic approaches. Esthetic enhancement of the smile can be achieved with both direct and indirect techniques.<sup>10,11</sup> Indirect techniques are more preferable when multiple teeth are involved, even though they are more time consuming and may require more appointments compared to the direct ones, owing to better final esthetic outcome.<sup>12</sup> Diagnostic mock-up is crucial with indirect techniques, as it aids in visualizing the final outcome, which can be advantageous, both for the clinician and the patient. Minimal tooth preparation with laminates, preserves the tooth tissue and the thickness of the ceramic restoration provides for excellent colour stability, strength and translucency wherever indicated. In the present clinical report, laminate veneers improved the patient's esthetic appeal drastically (Figure 6)

### 4. Conclusion

In the present case report, ceramic laminate veneers have been used as the indirect treatment approach for rehabilitation of malaligned and discolored maxillary anterior teeth. The final result was esthetically pleasing and

minimal invasive, hence, increasing the satisfaction level of the patient.

### 5. Source of Funding

None.

### 6. Conflict of Interest

The authors declare that there is no conflict of interest.

### References

1. Heymann HO, Hershey HG. Use of composite resin for restorative and orthodontic correction of anterior interdental spacing. *J Prosthet Dent.* 1985;53(6):766-71. doi:10.1016/0022-3913(85)90153-2.
2. Tuncer D, Yazici AR, Özgünaltay G, Dayangac B. Clinical evaluation of different adhesives used in the restoration of non-carious cervical lesions: 24-month results. *Aust Dent J.* 2013;58(1):94-100. doi:10.1111/adj.12028.
3. Kopperud SE, Tveit AB, Gaarden T, Sandvik L, Espelid I. Longevity of posterior dental restorations and reasons for failure. *Eur J Oral Sci.* 2012;120(6):539-48. doi:10.1111/eos.12004.
4. Garoushi S, Lassila L, Hatem M, Shembesh M, Baady L, Salim Z, et al. Influence of staining solutions and whitening procedures on discoloration of hybrid composite resins. *Acta Odontol Scand.* 2013;71(1):144-50. doi:10.3109/00016357.2011.654253.
5. Walter RD, Raigrodski AJ. Critical appraisal: clinical considerations for restoring mandibular incisors with porcelain laminate veneers. *J Esthet Restor Dent.* 2008;20:276-81.
6. Guess PC, Stappert CF, Strub JR. Preliminary clinical results of a prospective study of IPS e.max Press- and Cerec ProCAD- partial coverage crowns. *Schweiz Monatsschr Zahnmed.* 2006;116:493-500.
7. Signore A, Kaitsas V, Tonoli A, Angiero F, Silvestrini-Biavati A, Benedicenti S. Sectional porcelain veneers for a maxillary midline diastema closure: a case report. *Quintessence Int.* 2013;44:201-6.
8. Seghi RR, Sorensen JA. Relative flexural strength of six new ceramic materials. *Int J Prosthodont.* 1995;8:239-46.
9. McLaren EA. All-ceramic alternatives to conventional metal-ceramic restorations. *Compend Contin Educ Dent.* 1998;19:307-8.
10. Mangani F, Cerutti A, Putignano A, Bollero R, Madini L. Clinical approach to anterior adhesive restorations using resin composite veneers. *Eur J Esthet Dent.* 2007;2(2):188-209.
11. Horvath S, Schulz CP. Minimally invasive restoration of a maxillary central incisor with a partial veneer. *Eur J Esthet Dent.* 2012;7(1):6-16.
12. Mangani F, Cerutti A, Putignano A, Bollero R, Madini L. Clinical approach to anterior adhesive restorations using resin composite veneers. *Eur J Esthet Dent.* 2007;2(2):188-209.

### Author biography

**Neeti Solanki**, Junior Resident

**Sunit Kumar Jurel**, Professor Jr. Grade

**Pooran Chand**, Professor and Head

**Raghuwar Dayal Singh**, Professor

**Cite this article:** Solanki N, Jurel SK, Chand P, Singh RD. Rehabilitating anterior teeth esthetically with ceramic laminate veneers. *Int J Oral Health Dent* 2021;7(1):72-74.