



Case Report

Esthetic rehabilitation with modified Groper's appliance in a four year old child: A case report

Upasana Shrivastava¹, Khushboo Barjatya^{1,*}, Updesh Masih¹, Binti Rani Chand¹,
Abhilasha Manker¹, Preene Juneja¹

¹Dept. of Pediatric & Preventive Dentistry, Sri Aurobindo Institute of Medical Sciences, Indore, Madhya Pradesh, India



ARTICLE INFO

Article history:

Received 27-02-2021

Accepted 17-03-2021

Available online 21-04-2021

Keywords:

Numerous tooth
Maxillary incisors

ABSTRACT

The biggest task for a paediatric dentist is the restoration in a young child who has severely damaged anterior teeth and suffered from multiple tooth loss due to severe early childhood caries. Early loss of anterior teeth has a major effect on the psychology and behaviour of children. The aim of this paper is to describe the rehabilitation of deciduous anterior teeth with a fixed, aesthetic and functional appliance (modified Groper's Appliance). Such appliances are considered to be elective and their placement is normally at the demand of parents.

© This is an open access article distributed under the terms of the Creative Commons Attribution License (<https://creativecommons.org/licenses/by/4.0/>) which permits unrestricted use, distribution, and reproduction in any medium, provided the original author and source are credited.

1. Introduction

The aesthetic recovery in the preschooler who has experienced numerous tooth loss due to rampant early childhood caries (ECC) or serious dental trauma is the biggest obstacle for the dentist.¹ Early tooth loss has a profound impact on general oral health of a child even after eruption of permanent teeth, which often leads to undesirable tooth movements of primary or permanent teeth including loss of arch length.²

Untimely loss of maxillary incisors due to caries is very common in young children.² ECC, previously known as baby bottle caries, nursing bottle caries, baby bottle tooth decay, or nursing decay, is comparatively recent term for infants and preschooler that describes rampant dental caries.¹ The extent of decay of the teeth in ECC is usually so severe that most of the anterior crowns are decayed or lost by the time the child is brought to the dentist.¹ Esthetic and functional rehabilitation of pre-schoolers with ECC is the biggest challenge for paediatric dentists.²

Anterior teeth loss in children has a wide-ranging effect on the child's psyche. It is very important to restore

all functions such as mastication, speech, abnormal oral habits including the aesthetics of the child, when these teeth are lost by replacement and prosthetic management. The substitute should be such that it should not intervene with the underlying successor's eruption process. There are various aesthetic alternatives available, including removable or fixed partial dentures.³

This case report illustrates a modified Groper's appliance for grossly decayed primary maxillary incisors.

2. Case Report

A four-year-old boy reported to the Department of Pediatric and Preventive Dentistry with a complaint of decayed upper front teeth. On clinical and radiographic examination, root stump was present i.r.t 51,52, 61 and 62 (Figures 1 and 3), carious with pulpal involvement was noticed with 74 and 84 (Figure 2). Smooth surface caries was present with 53, 54, 63, 64, 71 and 72. Fusion with smooth surface caries was noticed with 81, 82 (Figures 1 and 2). Occlusal pit caries was present with 55, 64 and 65. Thus, a diagnosis of severe early childhood caries (S-ECC) was made. Based on the clinical and radiographic findings, the following treatment plan was made. Pulpectomy of 74 and 84 followed by

* Corresponding author.

E-mail address: khushboo.barjatya@gmail.com (K. Barjatya).

Stainless steel crown. GIC restoration with 55,64 and 65. Extraction of 51, 52, 61 and 62 followed by fixed functional space maintainer.

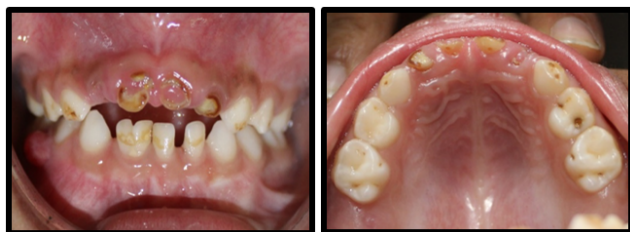

Fig. 1: Showing grossly carious 51,52,61,62

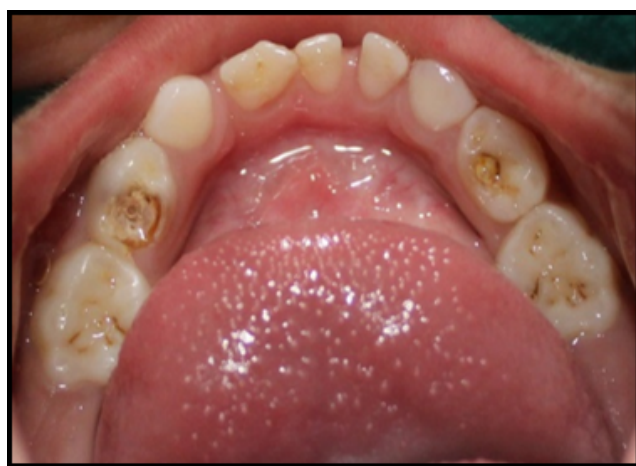

Fig. 2: Preoperative mandibular view

3. Appliance Fabrication

Before fabrication of appliance; 51, 52, 61, 62 were extracted and pulpectomy was performed with 84 and 74. Bands were adapted on 55 and 65 and alginate impressions were made for the upper and lower arches. On the upper cast, a stainless steel wire (0.9 mm) framework was made, spanning from one band to the other. The ends of the wire are then soldered to the corresponding molar bands. In the anterior region 4 brackets were soldered and was tried in patient's mouth for fitting (Figure 4). After trial acrylic teeth were trimmed and occlusion was checked using lower cast. Using Transbond light cure adhesive (Koden, Newington, USA), teeth were bonded to the brackets and cold cure acrylic was used to increase the anchorage between teeth and acrylic. Glass ionomer luting cement was used for cementation of molar bands on 55 and 65, after appropriate trimming and polishing (Figures 5 and 6).

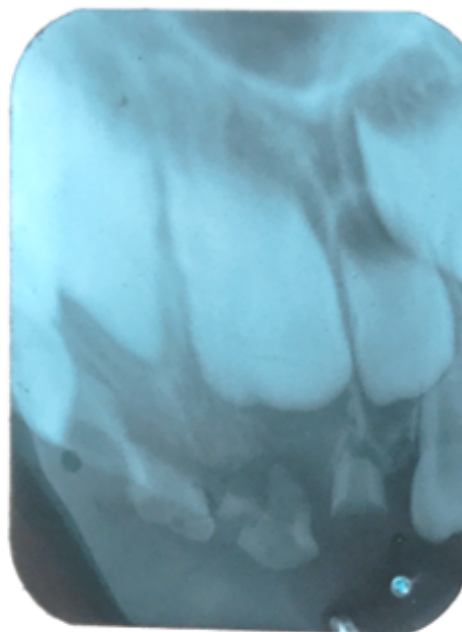


Fig. 3: IOPA showing anterior root resorption

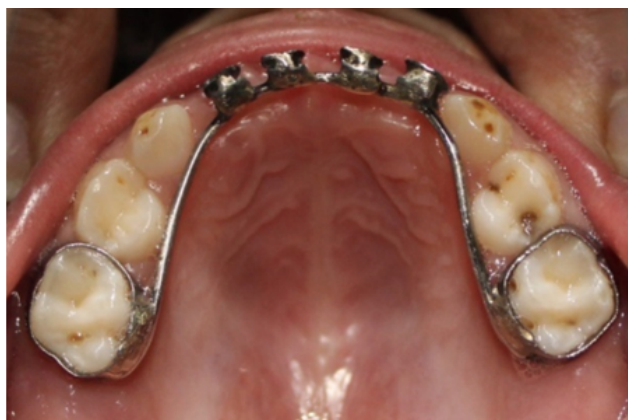

Fig. 4: Metal trial of appliance with 4 brackets in anterior region

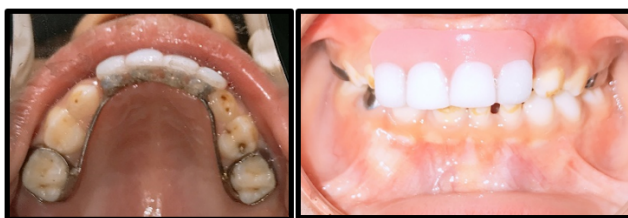

Fig. 5: Postoperative photograph after the placement of appliance

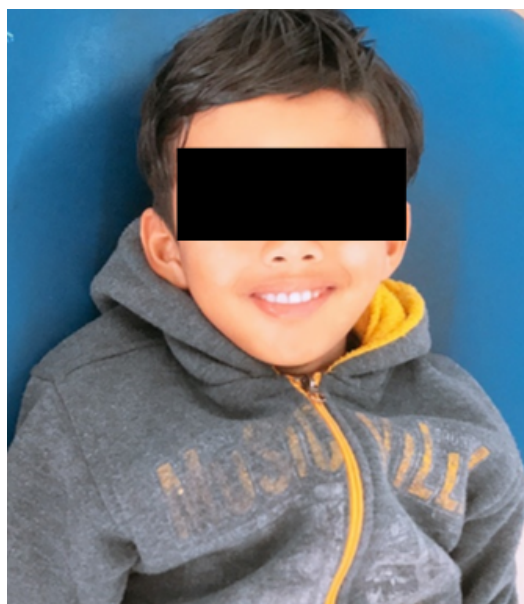

Fig. 6: Facial view postoperatively

4. Discussion

Problems associated with untimely tooth loss include: adjacent teeth tipping, antagonist teeth over-eruption, midline deviation, masticatory abnormality, speech difficulties and lingual dysfunction.^{4,5} Parental desire, space maintenance, aesthetic restoration and function maintenance are the reasons for replacing the edentulous upper anterior span with an aesthetic appliance.^{2,5}

The aesthetic restoration of anterior deciduous teeth has a vital psychological influence on the self-esteem of the patient. The permanent successors may be proclined after early loss of deciduous maxillary anterior teeth and therefore the arch length or perimeter is increased.⁶ Inappropriate speech may result in absence of maxillary anterior teeth, the lingual sides of which are required by the tongue for certain phonations. Usually, it affects sounds such as 's', 'z' and 'th'.⁵

A research by Riekman and Badrawy (1993) stated that speech difficulties resulted in the loss of deciduous anterior teeth before the age of 3 years. The motives for replacing missing anteriors are to restore an esthetic appearance and facilitate the child's normal psychological development.⁵

When taking into account all the variables, if parents inclines to replace the missing anterior teeth of their child, their wish should not be discouraged.

To build strength instead of bonding, banding of molars was carried out. In a case, Bhasin et al. used a bonded space maintainer to preserve the space in the primary molar region. It is necessary to choose the material that is cost-effective and will be able to function before the permanent teeth erupt without interfering with the normal eruption process.^{6,7}

In the present case, it was plan for minimum amount of palatal coverage causing no or minimum irritation. Aesthetic space maintainer has been found to have a much broader acceptability and compliance by paediatric dental patients to wear the appliance. This is also a solution to paediatric edentulous anterior arches with compromised speech, esthetics and behaviour of the patient including poor social acceptance. Thus in this case, it was plan to use fixed functional space maintainer for aesthetic and functional replacement of 51, 52, 61, and 62.

5. Conclusion

Early childhood caries of an anterior tooth can result in psychological distress to the child at a younger age. With this appliance, the restoration of anterior esthetics gave the child and his parents an important psychological boost. In addition to improving facial esthetics, it acts as a functional space maintainer, helping to establish proper speech; preventing any untoward oral habits from emerging, thereby helping the child's sound development during the foundation years.

6. Source of Funding

None.

7. Conflict of Interest

The authors declare that there is no conflict of interest.

References

- Waggoner WF, Kupietzky A. Anterior esthetic fixed appliances for the preschooler: considerations and a technique for placement. *Pediatr Dent.* 2001;23(2):147–50.
- Sharma MP, Srivastava B, Gupta N, Gambhir N, Singh R. Esthetic & Functional Rehabilitation in a Four Year Old Pediatric Patient with Modified Groper's Appliance - A Case Report. *J Clin Dent Heal Talk.* 2019;11(4):46–8.
- Joybell CC, Ramesh K, Simon P, Mohan J, Ramesh M. Dental rehabilitation of a child with early childhood caries using Groper's appliance. *J Pharm Bioallied Sci.* 2015;7:S704. doi:10.4103/0975-7406.163483.
- Liegeois F, Limme M. Modified bonded bridge space maintainer. *J Clin Pediatr Dent.* 1999;23:281–4.
- Chalakkal P, Devi RS, Srinivas GV, Venkataramana P. Dentulous appliance for upper anterior edentulous span. *J Clin Diagn Res.* 2013;7(12):3086.
- Khare V, Nayak PA, Khandelwal V, Nayak UA. Fixed functional space maintainer: novel aesthetic approach for missing maxillary primary anterior teeth. *BMJ Case Rep.* 2013;p. bcr2013009585. doi:10.1136/bcr-2013-009585.
- Parihar V, Choudhary R, Singh V, Sihag T, Malhotra R. Groper' S Appliance. *An Anterior Fixed Aesthetic Appliance.* 2017;1(1):1–4.

Author biography

Upasana Shrivastava, PG Student

Khushboo Barjatya, Professor

Updesh Masih, Professor and HOD

Binti Rani Chand, Reader

Abhilasha Manker, Senior Lecturer

Preene Juneja, Reader

Cite this article: Shrivastava U, Barjatya K, Masih U, Chand BR, Manker A, Juneja P. Esthetic rehabilitation with modified Groper's appliance in a four year old child: A case report. *Int J Oral Health Dent* 2021;7(1):65-68.