



## Original Research Article

## In vitro study to compare the accuracy of four diagnostic methods for locating the second mesiobuccal canal in maxillary molars

Saurabh Gupta<sup>1</sup>, Rishu Mittal<sup>1,\*</sup>, Poonam Bogra<sup>1</sup>, Saru Dhir Gupta<sup>2</sup>, Radhika Goyal<sup>1</sup>, Nikita Goyal<sup>1</sup>

<sup>1</sup>Dept. of Conservative Dentistry & Endodontics, J.N Kapoor DAV Dental College, Yamuna Nagar, Haryana, India

<sup>2</sup>Dept. of Pedodontics, MM College of Dental Sciences & Research, Ambala, Haryana, India



## ARTICLE INFO

## Article history:

Received 05-01-2021

Accepted 11-01-2021

Available online 21-04-2021

## Keywords:

Diagnostic methods

Direct visual method

Magnifying loupes

Dental operating microscope

CBCT

Cross-sectioning

Diagnostic accuracy

## ABSTRACT

**Aim:** The aim of this in vitro study is to compare the efficacy of three diagnostic methods, Direct visual method, Magnifying loupes and Dental operating microscope in recognising all the canals of the root canal system in maxillary first molars using CBCT and reference standard method.

**Materials and Methods:** A total of 65 maxillary first molars were selected for this study. Teeth selected were evaluated by Periapical radiographs and CBCT. Access cavities of selected extracted human maxillary first molars were prepared, and the floor of the pulp chamber was then explored to locate the MB2 canal in five stages: Stage I (Direct Visual Method), Stage II (under  $\times 3.5$  Magnifying Loupes with light-emitting diode [LED] light), Stage III (Under Dental Operating Microscope), and Stage IV (Cross-sectioning was done below CEJ and the sections were evaluated using stereomicroscope at 10x magnification).

**Statistical Analysis:** The descriptive statistics were tabulated using Chi square test to compare the efficacy between the diagnostic methods. Sensitivity, specificity, Positive/Negative predictive values were calculated for each method.

**Results:** The results obtained in this study showed that CBCT was most accurate with the dimensional accuracy of 96% followed by Dental operating microscope which performed better (with the diagnostic accuracy of 76%) than the magnifying loupes (with the diagnostic accuracy of 64%) direct visual method (with the diagnostic accuracy 60%).

**Conclusion:** The dental operating microscope was most effective in the detection of MB2 canals followed by magnifying loupes and direct visual method. Additionally, CBCT could be used as a supplementary diagnostic tool in cases in which canals are not found using the methods available in the dental office.

© This is an open access article distributed under the terms of the Creative Commons Attribution License (<https://creativecommons.org/licenses/by/4.0/>) which permits unrestricted use, distribution, and reproduction in any medium, provided the original author and source are credited.

### 1. Introduction

A major cause for the failure of root canal therapy is the inability of clinician to localize and treat all the canals of the complex root canal system. The clinical impact of missed anatomy can be clearly understood with the large number of re-treatment case reports available in the literature. According to a study done by Hoen and Pink, missed canals are noted in 42% teeth that required endodontic retreatment. Canals may be left untreated mainly because their presence

is not recognised by the dentist.<sup>1</sup>

Traditionally, clinical inspection and intraoral radiography were the methods used to identify root canals. However, efficacy of clinical inspection is directly dependent on examiner's knowledge and skills<sup>2</sup> whereas radiography is limited by technical factors such as contrast and angulation.<sup>3</sup> Each method has its own unique limitation which contributes to a relatively high rate of unidentified canals particularly when canal location and number are atypical.

Endodontics, as we all understand, is confined to narrow operating space as it deals with miniscule anatomy.<sup>4</sup>

\* Corresponding author.

E-mail address: [dr.rishumittal@gmail.com](mailto:dr.rishumittal@gmail.com) (R. Mittal).

Unaided eyes can only see up to the level of canal orifice.<sup>5</sup> Moreover, natural vision may begin to deteriorate at the age of 40 for maximum people.<sup>6</sup> As a result, it is assumed that higher magnification, achieved either by using recently introduced diagnostic aids such as magnifying loupes or an operating microscope, may enhance the ability of clinician to detect even those canals that could not normally be observed by naked eye alone.<sup>7</sup>

Cone beam computed tomography (CBCT) presents a new technological approach that is non-invasive and overcomes many of the disadvantages of clinical inspection and radiography because the operator can visualise the morphologic characteristic of the sample in 3-dimensional slices without destroying the specimens.<sup>8</sup> CBCT has the unique ability to provide high-resolution images in multiple planes of space while eliminating superimposition of surrounding structures.<sup>9</sup>

So, many methods are available to aid the clinicians in detecting additional canals in Mesiobuccal root of maxillary first molar, but no studies have evaluated the diagnostic efficacy of Direct visual inspection, inspection using loupes, inspection using microscope and analysis of CBCT images.

Thus, an invitro study is designed to compare the diagnostic efficacy of direct visual method, magnifying loupes and dental operating microscope in locating MB2 canals in maxillary molars using CBCT and reference standard method of cross-sectioning.

## 2. Materials and Methods

The study was conducted in the department of Conservative Dentistry and Endodontics at J.N Kapoor D.A.V. (C) Dental College, Yamunanagar. For this in-vitro study, approximately 200 extracted human permanent maxillary first and second molars (preferably from the age group of 18-55 years) were obtained. The inclusion criteria were maxillary first molars with the roots of fully formed apices and with no previous restorative and endodontic treatment.

On the basis of this exclusion and inclusion criteria, a total of 65 maxillary first molars were selected for this study (Figure 1). Teeth selected were cleaned using ultrasonic scaler and gracey curette so as to remove soft tissues and hard aggregations, if present, on their surfaces.

These selected teeth were further evaluated by periapical radiographs to evaluate their internal anatomy as well as to rule out any internal resorption or calcification (Figure 2). These selected teeth were then stored in 10% formalin at the room temperature till their further use.

For this in-vitro study, firstly CBCT Images (Figure 3) were obtained using a Newtom 3-D unit operating at 90 KVP. All images were analysed independently by an expert radiologist. The operator was kept blind to the results of CBCT findings till completion of the study.

The teeth were accessed with sterile Endo Access Bur & Endo Z bur (Dentsply-Maillefer, Ballaigues, Switzerland).

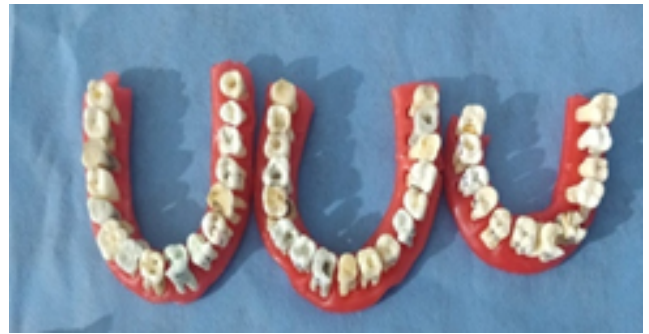

Fig. 1: Samples for the study

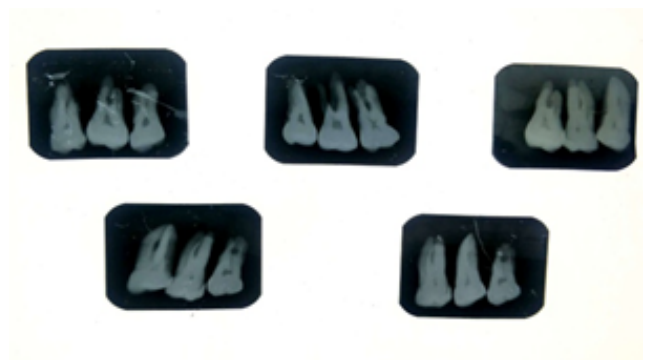

Fig. 2: Preoperative radiographs of maxillary molars

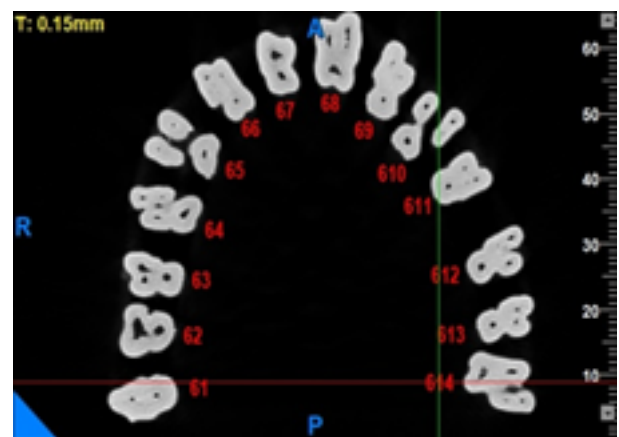


Fig. 3: CBCT scan image

The access cavity was prepared initially with triangular outline. Mesiobuccal 1 (MB1), distobuccal, and palatal (P) canal orifices were located with the help of an endodontic explorer (DG16, Hu-Friedy), and canals were negotiated with 10 or 15 K-files (Mani, Japan). Hand instrumentation followed by copious irrigation with 3% sodium hypochlorite (Parcan; Septodont, Saint-Maur-des-Fosses, France) was used to remove the contents within pulp chamber and root canal space. The outline of the access cavity was further improved from a triangular to a rhomboidal shape (Figure 4)

to increase the visibility of the pulpal floor.

The pulp chamber floor was then negotiated to locate the MB2 canal in four stages.

### 2.1. Stage I (Direct visual method)

Initially, the MB2 canal orifice was located with a DG16 explorer under direct vision. The explorer was run from the main MB1 canal toward the palatal canal 1–2 mm mesially.

### 2.2. Stage II (Using magnifying loupes with light-emitting diode light)

The teeth which did not detect the presence of MB2 canal after Stage I were examined under magnification ( $\times 3.5$ ) using Dental Loupes (Unicorn Denmart Galilean Dental Loupes) with LED light with the help of a DG16 explorer.

### 2.3. Stage III (Under dental operating microscope $\times 16$ )

Further, the teeth in which the MB2 canal could not be detected after Stage II, dental operating microscope at  $\times 16$  magnification (Labomed Prima DNT Microscope with 5 Step magnification changer) was used.

### 2.4. Stage IV (Cross-sectioning)

Finally, the selected 48 maxillary molars were cross-sectioned (Figure 4) below the cement-enamel junction (CEJ) at three different levels using diamond discs (SS White) at low speed and then these sections were analysed by the examiner under stereomicroscope at 10X magnification to confirm the presence of all the canals in the root canal system.

The teeth which could not detect the MB2 canal after Stage IV were reported to be absent or missing.

Throughout the procedure, copious irrigation was done with 3% sodium hypochlorite solution and normal saline intermittently. After locating the canal orifice, the MB2 canal was negotiated using 06, 08, and 10 K-files. The presence of MB2 canal located was confirmed with working length determination radiographs (Figure 5).

## 3. Results

The number of teeth in which MB2 canal was found with each diagnostic method has been shown in Table 1.

Direct visual method (DVM), Magnifying loupes and Dental operating microscope (DOM) detected significantly lesser canals compared to the cross-sectioning.

## 4. Discussion

A predictable successful endodontic therapy starts with identification of all the canals in the root canal system. If a canal is not identified, it cannot be cleaned and filled and is the potential cause of failure in the endodontic therapy.

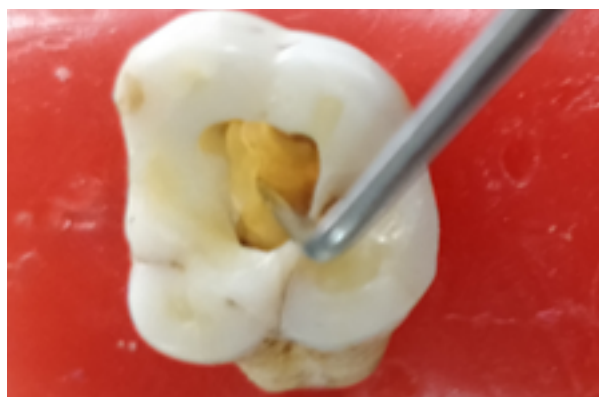


Fig. 4: Access cavity preparation

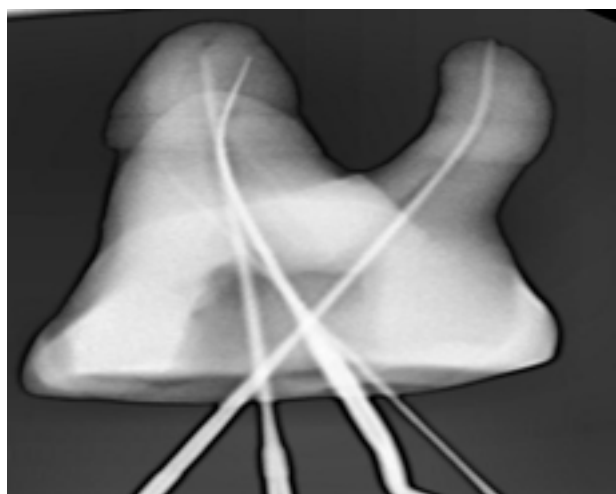


Fig. 5: Post operative radiograph

Table 1:

Method	No. of MB2 canals (%)
CBCT	48 (96)
Direct Visual Method	30 (60)
Magnifying Loupes	32 (64)
Dental Operating Microscope	38 (76)
Cross-sectioning	50 (100)

CBCT was the most accurate in the detection of the MB2 canals in maxillary molars

Many diagnostic methods are available to aid clinicians in detecting the MB2 canals in maxillary first molars,<sup>10–13</sup> but no studies have evaluated the diagnostic efficacy of direct visual inspection, inspection using loupe, inspection using microscope, and analysis of CBCT images.

The present study highlights the importance of recent advancing techniques such as CBCT in determining the root canal morphologies in the maxillary first molar and the use of magnifying aids such as magnifying loupes and dental operating microscope for locating canals which are usually missed by naked eye in general practice.

**Table 2:**

Method		Cross-sectioning (%)		Total	p-value
		Yes	No		
CBCT	Yes	48 (73.8)	0 (0)	48 (73.8)	0.360
	No	2 (3)	15 (23)	17 (26)	
<b>Total</b>		50 (77)	15 (23)	65 (100)	
DVM	Yes	30 (46)	0 (0)	30 (46)	< 0.001*
	No	20 (31)	15 (23)	35 (54)	
<b>Total</b>		50 (77)	15 (23)	65 (100)	
M. Loupes	Yes	32 (49)	0 (0)	32 (49)	< 0.001*
	No	18 (27.6)	15 (23)	33(50.7)	
<b>Total</b>		50 (77)	15 (23)	65 (100)	
DOM	Yes	38 (58.4)	0 (0)	38 (58.4)	< 0.001*
	No	12 (18.4)	15 (23)	27 (41.5)	
<b>Total</b>		50 (77)	15 (23)	65 (100)	

Chi-square test, \* Significant difference

**Table 3:**

	CBCT	DVM	Magnifying loupes	DOM
Sensitivity	96.00% (86.29-99.51%)	60.00% (45.18-73.59%)	64.00% (49.19-77.08%)	76.00% (61.83-86.94%)
Specificity	100.00% (78.20-100.00%)	100.00% (78.20-100.00%)	100.00% (78.20-100.00%)	100.00% (78.20-100.00%)
Positive Predictive Value	100.00% (78.20-100.00%)	100.00% (78.20-100.00%)	100.00% (78.20-100.00%)	100.00% (78.20-100.00%)
Negative Predictive Value	88.24% (65.86-96.68%)	42.86% (34.82-51.29%)	45.45% (36.54-54.67%)	55.56% (43.29-67.18%)
Accuracy	96.92% (89.32-99.63%)	69.23% (56.55-80.09%)	72.31% (59.81-82.69%)	81.54% (69.97-90.08%)

Maxillary first molar is one of the most misunderstood tooth, as its root canal system presents a variety of considerations for the treating practitioner. Clinically, the mesio-buccal root contains a second root canal system which can be identified and treated in more than 70% of the cases.<sup>14</sup> Also, MB2 canal often goes unnoticed as it departs the pulp chamber at a sharp mesial inclination and is then bent again in the distal direction, making its detection highly challenging.<sup>12</sup> Inability to identify this MB2 may often result in a high percentage of endodontic failure, requiring re-treatment among these teeth.<sup>15</sup>

It is worth mentioning that when a method is used to determine its ability in detecting what it is looking for, measuring its diagnostic accuracy is useful to judge the options and choose the best one.<sup>16</sup>

The results obtained in this study showed that CBCT was most accurate with the dimensional accuracy of 96% followed by Dental operating microscope which performed better (with the diagnostic accuracy of 76%) than the magnifying loupes (with the diagnostic accuracy of 64%) direct visual method (with the diagnostic accuracy 60%).

The reason that can be attributed to the increase likelihood of the detection of additional canals using magnification is that when using adequate "illumination and magnification" provided by the DOM, two main features become evident which helps in canal location. The first was the presence of a groove in the pulpal floor, serving as a map for canal location. Second, there was a color difference between the dentin of the pulpal floor and that around the canal orifices, which becomes clearly evident with DOM.<sup>17</sup>

Naked Eye has limited resolving power. Carr reported that the human eye, when unaided by magnification, has the inherent ability to resolve or distinguish two separate lines or entities that are at least 200 microns, or 0.2mm, apart. If the lines are closer together, two separate entities or the objects will appear as one. It means if the distance between MB1 and MB2, anything less than one fifth (i.e., 0.2 mm) of a millimetre, it becomes extremely difficult for the human eye to resolve them as two separate canals and that's where the role of magnification comes into play. Alternatively, a dental operating microscope can dramatically improve the resolving limit from 0.2mm to 0.006 mm.<sup>18</sup>

These results are also supported by Rajput F et al. who in their study stated that dental operating microscope examination may be more effective for location of the MB-2 canal than naked eye examination.<sup>19</sup> The results of this study are also supported by previous studies done by Buhrey et al. who showed that the use of magnification increased MB2 detection rate in comparison to that of non-magnification.<sup>7</sup>

However the differences between dental operating microscope, magnifying loupes and the direct visual method was statistically insignificant. The reason that can be attributed to this is that the operators experience in using visual method and loupes is much more than that of using DOM which actually is of Resident's level. According to Corcoran et al. the examiner's ability to locate root canals is largely dependent on clinical experience.<sup>2</sup>

Additionally, analysis of CBCT images proved to be a highly accurate method for detecting MB2 canals, with diagnostic accuracy similar to that of the reference standard method. This is due to the fact that CBCT has the unique ability of providing 3 dimensional undistorted images without destroying the specimen.<sup>8</sup> Baratto Filho et al. reported that operating microscope and CBCT have been important for locating and identifying root canals, and CBCT can be used as a good method for initial identification of maxillary first molar internal morphology.<sup>20</sup> Michetti et al. compared CBCT reconstructions of root canal systems with histological sections. The authors found a strong correlation between data acquired through CBCT and histological sections.<sup>21</sup>

A limitation of the method is that patients are subjected to a certain radiation dose. The American Association of Endodontists (AAE) and American Association of Oral Maxillofacial Radiology (AAOMR) recommend that the CBCT should not be used in the endodontic routine. However, if necessary, it is preferable to obtain acquisitions with small FOV and voxel aiming to reduce the radiation dose. Besides Radiation issues, the presence of artefacts created by metallic restorations present in mouth may compromise image quality.<sup>22</sup>

In vitro studies have some limitations and translating their results to the clinical situation seems to be inappropriate. However, the recent literature supports our findings and points out that CBCT is reliable tool for detecting missing canals in vivo.<sup>23</sup>

This study, however, supports the fact that the long-term prognosis in endodontics can be enhanced with the use of magnifying aids in locating the untreated canals which often gets overlooked without magnification, for e.g. MB2 canal of the maxillary molars.<sup>24</sup> This huge shift in clinical accuracy, even by using low magnification, is bringing a revolution in the field of endodontics with greater success rate by transforming "tactile-driven endodontics" to "vision-based endodontics".<sup>4</sup> Additionally, CBCT could be used as a supplementary diagnostic tool in cases in which canals are

not found using the methods available in the dental office. However, to reduce the radiation dose, it is preferable to obtain acquisitions with small FOV and voxel.<sup>22</sup>

## 5. Conclusion

The operating microscope was most effective in the detection of MB2 canals. Furthermore, the magnifying loupes with LED light when compared to the operating microscope did not show a significant difference in the detection of MB2 canals, suggesting that magnifying loupes with LED light can be used as a suitable alternative to operating microscope. Additionally, CBCT could be used as a supplementary diagnostic tool in cases in which canals are not found using the methods available in the dental office.

## 6. Source of Funding

None.

## 7. Conflict of Interest

None.

## References

1. Hoen M, Pink F. Contemporary Endodontic Retirements: An Analysis based on Clinical Treatment Findings. *J Endod.* 2002;28(12):834–6. doi:10.1097/00004770-200212000-00010.
2. Corcoran J, Apicella MJ, Mines P. The Effect of Operator Experience in Locating Additional Canals in Maxillary Molars. *J Endod.* 2007;33(1):15–7. doi:10.1016/j.joen.2005.11.005.
3. Hession RW. Endodontic morphology. *Oral Surg Oral Med Oral Pathol.* 1977;44:610–20. doi:10.1016/0030-4220(77)90306-1.
4. Low JF, Dom TNM, Baharin SA. Magnification in endodontics: A review of its application and acceptance among dental practitioners. *Eur J Dent.* 2018;12(04):610–6. doi:10.4103/ejd.ejd\_248\_18.
5. Perrin P, Neuhaus KW, Lussi A. The impact of loupes and microscopes on vision in endodontics. *Int Endod J.* 2014;47(5):425–9. doi:10.1111/iej.12165.
6. Burton JF, Bridgman GF. Presbyopia and the dentist: The effect of age on clinical vision. *Int Dent J.* 1990;40:303–12.
7. Buhrey L, Barrows M, BeGole E, Wenckus C. Effect of Magnification on Locating the MB2 Canal in Maxillary Molars. *J Endod.* 2002;28(4):324–7. doi:10.1097/00004770-200204000-00016.
8. Cotton T, Geisler T, Holden D, Schwartz S, Schindler W. Endodontic Applications of Cone-Beam Volumetric Tomography. *J Endod.* 2007;33(9):1121–32. doi:10.1016/j.joen.2007.06.011.
9. Matherne RP, Angelopoulos C, Kulild JC, Tira D. Use of Cone-Beam Computed Tomography to Identify Root Canal Systems In Vitro. *J Endod.* 2008;34(1):87–9. doi:10.1016/j.joen.2007.10.016.
10. Schwarze T, Baethge C, Stecher T, Geurtsen W. Identification Of Second Canals In The Mesiobuccal Root Of Maxillary First And Second Molars Using Magnifying Loupes Or An Operating Microscope. *Aust Endod J.* 2002;28(2):57–60. doi:10.1111/j.1747-4477.2002.tb00379.x.
11. Vizzotto MB, Silveira PF, Artus NA, Montagner F, Gomes B, da Silveira H. CBCT for the assessment of second mesiobuccal (MB2) canals in maxillary molar teeth: effect of voxel size and presence of root filling. *Int Endod J.* 2013;46(9):870–6. doi:10.1111/iej.12075.
12. Omergordusys M, Gordusys M, Friedman S. Operating Microscope Improves Negotiation of Second Mesiobuccal Canals in Maxillary Molars. *J Endod.* 2001;27(11):683–6. doi:10.1097/00004770-200111000-00008.

13. Alaçam T, Tinaz AC, Genç Ö, Kayaoglu G. Second mesiobuccal canal detection in maxillary first molars using microscopy and ultrasonics. *Aust Endod J.* 2008;34(3):106–9. doi:10.1111/j.1747-4477.2007.00090.x.
14. Ruddle CJ. MB2 root canal systems in maxillary first molars. *Dent Today.* 1995;14(5):38–41.
15. Henry BM. The fourth canal: Its incidence in maxillary first molars. *J Can Dent Assoc.* 1993;59:995–6.
16. Simundic AM. Measures of Diagnostic Accuracy: Basic Definitions. *EJFCC.* 2009;19(4):203–11.
17. DeCarvalho MC, Zuolo ML. Orifice Locating with a Microscope. *J Endod.* 2000;26(9):532–4. doi:10.1097/00004770-200009000-00012.
18. Carr GB, Murgel CAF. The Use of the Operating Microscope in Endodontics. *Dent Clin North Am.* 2010;54(2):191–214. doi:10.1016/j.cden.2010.01.002.
19. Rajput F, Kalhoro FA, Shaikh ML, Khatoon S. Validity of different methods for mb-2 canal location in permanent maxillary molars. *Pak Oral Dent J.* 2014;34(3):548–51.
20. Filho FB, Zaitter S, Haragushiku GA, deCampos EA, Abuabara A, Correr GM. Analysis of the Internal Anatomy of Maxillary First Molars by Using Different Methods. *J Endod.* 2009;35(3):337–42. doi:10.1016/j.joen.2008.11.022.
21. Michetti J, Maret D, Mallet JP, Diemer F. Validation of Cone Beam Computed Tomography as a Tool to Explore Root Canal Anatomy. *J Endod.* 2010;36(7):1187–90. doi:10.1016/j.joen.2010.03.029.
22. AAE and AAOMR Joint Position Statement: Use of Cone Beam Computed Tomography in Endodontics 2015 Update. *Oral Surg Oral Med Oral Pathol Oral Radiol.* 2015;120(4):508–12.
23. Zeng C, Shen Y, Guan X, Wang X, Fan M, Li Y. Rare Root Canal Configuration of Bilateral Maxillary Second Molar Using Cone-beam Computed Tomographic Scanning. *J Endod.* 2016;42(4):673–7.
24. Wolcott J, Ishley D, Kennedy W, Johnson S, Minnich S, Meyers J. A 5 Yr Clinical Investigation of Second Mesiobuccal Canals in Endodontically Treated and Retreated Maxillary Molars. *J Endod.* 2005;31(4):262–4. doi:10.1097/01.don.0000140581.38492.8b.

### Author biography

**Saurabh Gupta**, Professor

**Rishu Mittal**, PG Student

**Poonam Bogra**, Professor and Head

**Saru Dhir Gupta**, Lecturer

**Radhika Goyal**, PG Student

**Nikita Goyal**, PG Student

**Cite this article:** Gupta S, Mittal R, Bogra P, Gupta SD, Goyal R, Goyal N. In vitro study to compare the accuracy of four diagnostic methods for locating the second mesiobuccal canal in maxillary molars. *Int J Oral Health Dent* 2021;7(1):48–53.