



Original Research Article

Angular changes of impacted mandibular third molars and developing mandibular third molars in premolar extraction cases- A retrospective radiographic study

Shanthi Velachery¹, Shahir Backer¹, Sandeep Shetty^{1,*}, Katheesa Parveen¹, Nandish Kumar Shetty¹, Akhter Husain¹

¹Dept. of Orthodontics and Dentofacial Orthopedics, Yenepoya Dental College, Yenepoya (Deemed to be University), Mangalore, Karnataka, India



ARTICLE INFO

Article history:

Received 09-11-2020

Accepted 07-01-2021

Available online 21-04-2021

Keywords:

Mandibular third molars

Impaction

Premolar extraction

ABSTRACT

Background: Successful eruption of impacted third molars requires the establishment of proper mesio-distal angulation as the tooth erupts into the oral cavity. Extraction of premolars in orthodontic cases may favour the eruption of third molars.

Materials and Methods: Patients were divided into 2 categories. Category I - Radiographs of patients undergone orthodontic treatment with third molar roots formation completed and category II - Radiographs of patients undergone orthodontic treatment with third molar roots formation uncompleted. The samples consisted of 24 third molars in each category with a total of 48 samples. On pre operative and post operative OPGs linear and angular measurements were measured.

Results: There was statistically significant difference in the space between the anterior border of the ramus and the second molar. But there was no significant difference in the angulation of the third molars. So even if there is a gain of space for the third molars to erupt, the changes in the angulations of third molar does not favour the spontaneous eruption after the orthodontic treatment with extraction of 1st premolar.

Conclusion: Extraction of 1st premolar has positive influence on the space available for the third molar eruption. But there are no changes in the angulations of the third molars that would in turn help in the eruption.

© This is an open access article distributed under the terms of the Creative Commons Attribution License (<https://creativecommons.org/licenses/by/4.0/>) which permits unrestricted use, distribution, and reproduction in any medium, provided the original author and source are credited.

1. Introduction

Third molars exhibit great variation in shape, size, position, root formation, time of development, and path of eruption. Third molar impaction is the most common of all tooth impactions.¹ In primitive mankind, excessive interproximal attrition allowed mesial drift of the posterior teeth and it decreases the incidence of third molar impaction. The lack of space between the ramus and the second molar has long been cited as a major etiologic factor of mandibular third molar impaction.² Successful eruption of impacted third molars requires the establishment of proper mesiodistal angulation as the tooth erupts into the oral cavity. In some cases, the third molars are uprighted during

the course of eruption, and in other cases third molar tip mesially, leading to difficulty in functioning and requiring orthodontic uprighting.³

For most of the correction of malocclusion space is required and extraction of premolar is the most recommended method of space gaining. This in turn, can affect the angulations and space available for the third molar eruption.⁴

Posterior available space is a significant factor for the eruption of mandibular impacted third molars and high rates of third molar eruption have been reported after the mandibular first molar extraction.^{5,6}

In this study we have considered, patients who have impacted third molars and have undergone extraction of first premolars for the correction of malocclusion. The aim of

* Corresponding author.

E-mail address: shanthi.velachery@gmail.com (S. Shetty).

the study was to evaluate the angular changes of impacted mandibular third molars and developing mandibular third molars in first premolar extraction cases and if first premolar extraction promotes the eruption of impacted third molar.

2. Materials and Methods

This retrospective study was conducted using panoramic radiographs of patients reported for the correction of malocclusion. Ethical clearance was obtained prior to the study- YEC2/395 on 02.06.2020. A total of 48 samples were selected based on inclusion and exclusion criteria. The sample was divided into two categories. Category I - Radiographs of patients undergone orthodontic treatment with third molar root formation completed and Category II - Radiographs of patients undergone orthodontic treatment with third molar roots formation is incomplete. (Table 1)

Table 1: Distribution of patients

Category	Category I	Category II
Root status	Completed third molar roots	Incomplete third molar roots
Teeth	24	24

Inclusion criteria used in category I were patients of age 18 to 25 years, impacted mandibular third molars should be seen on a panoramic radiograph, the root development of the third molars is complete, treatment of the first premolar extraction cases included full closure of the extraction spaces, the total treatment time in the extraction cases should have been not less than 24 months and high-quality pre-treatment and post-treatment orthopantomogram without any magnification and distortion errors and in which a clear, well defined anterior nasal spine (ANS), nasal septum, and the projected shadow of the palatal plane.

In category II, inclusion criteria used was patients of age 14 to 17 years, impacted mandibular third molars should be seen on a panoramic radiograph, incomplete root development of the third molars, treatment of the extraction cases included full closure of the extraction spaces, the total treatment time in the extraction cases should have been not less than 24 months and high-quality pre-treatment and post-treatment orthopantomographs. Exclusion criteria were orthopantomographs with missing third molar, poor quality panoramic radiographs, cases where space closure is not completed.

The OPGs of patients treated in, Mangalore from the year 2015 to 2019 were taken for the study. Forty eight mandibular third molars are considered for the study, out of which roots of 24 third molars have completed and the other 24 have incomplete root formation. All the patients have undergone orthodontic treatment. The subjects included in study, were treated with premolar extraction. At the end of the space closure, all lower third molars were examined on the final orthopantomograph (OPG) as well. The tracing

of pre-treatment and post treatment OPGs were done. The parameters were measured in the photocopy of the traced sheets. The following measurements were done (Figure 1). In molars with incomplete root the long axis is marked by drawing a bisector of the mesio distal width of third molar (Figure 2).

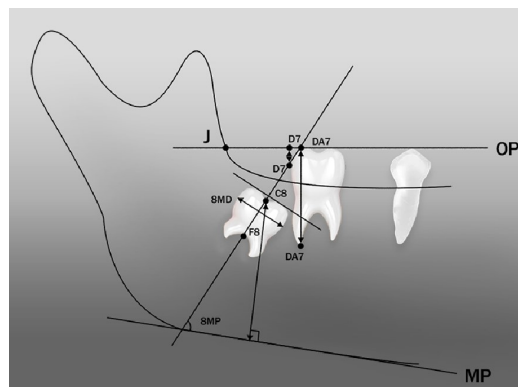


Fig. 1: Angular and linear measurements used in category I

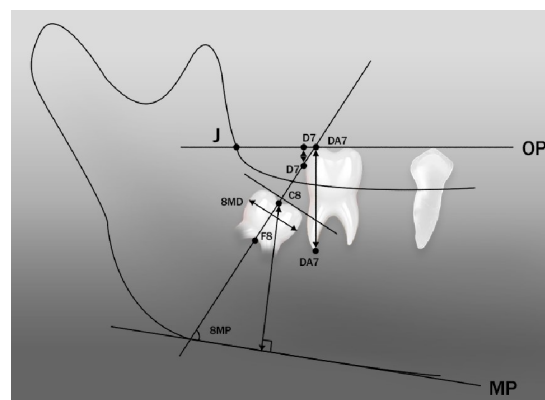


Fig. 2: Angular and linear measurements used in category II

The values got from OPG of pre-treatment and post-treatment OPGs were compared and were used for statistical analysis. Match pair T test with level of significance 5% power 80% and effective size 0.6 the minimum sample size required is 24 in each category.

2.1. Statistical analysis

Data was entered in MS Excel sheet. Statistical analysis was performed with SPSS version 23.0. Data was compared using the match pair T test. The level of significance was 0.05.

3. Results

In category, I Mean preoperative mesio-distal width of 3rd molar was 11.91 mm and postoperative was 11.97 mm.

The parameters J to D7, J to R7 and ratio of available space to the mesio-distal width of third molar signifies the space available for the third molar to erupt. Mean J to D7 preoperative distance was 8.79 mm and postoperative distance was 10.5 mm. Mean J to R7 preoperative distance was 10.6 mm and postoperative distance was 11.8 mm. Mean pre ratio of available space to the width of the third molar (J-D7/8MD) was 0.76 and post-operative ratio was 0.90. Result shows a significant increase in available space for the third molar to erupt. Angular measurement signifies the inclination of the third molar. Mean pre operative OP to 8 angle was 52.2 degree and postoperative angle was 53.5 degree. Mean pre operative MP to 8 angle was 68.1 degree and postoperative angle was 70 degree. Result shows there is no significant change in the inclination of third molar. (Table 3).

Table 2: Parameters

Linear measurements (mm)	
8 MD	Mesiodistal width of the third molar
J-D7	Available space for third molar eruption on the second molar crown level
J-R7	Available space for the third molar on the second molar distal root apex level.
Angular measurement (degree)	
8-MP	Angle between the long axis of the third molar and the mandibular plane.
8- OP	Angle between the long axis of the third molar and the occlusal plane
Ratio	
J-D7/8 MD	Ratio of available space to the width of the third molar

In category II Mean preoperative mesio-distal width of third molar was 11.68 mm and postoperative was 11.60 mm. Mean J to D7 preoperative distance was 6.41 mm and postoperative distance was 9.91 mm. Mean J to R7 preoperative distance was 8.56 mm and postoperative distance was 11.3 mm. Mean pre ratio of available space to the width of the third molar (J-D7/8MD) was 0.59 and post-operative ratio was 0.89. Results show a significant increase in available space for the third molar to erupt. Mean Preoperative OP to 8 angle was 58.0 degree and post-operative angle was 56.8 degree. Mean preoperative MP to 8 angle was 69.1 degree and post-operative angle was 74.1 degree. Result shows there is no significant changes in the inclination of third molar. (Table 4)

4. Discussion

Mandibular third molar impaction is one of the major problems facing the dental profession, with evolutionary changes being cited as a significant culprit. Ironically called the “wisdom teeth,” third molars are commonly blamed for a variety of complications, although their role in such complications has not necessarily been confirmed.⁷ The

Table 3: Measurements considered in category I; The following table depicts the pre and post values of the category I

Parameters	Mesio-distal width of 3rd molar(mm)		J to D7(mm)		J to R7(mm)		Ratio (J-D7/8MD)		OP to 8 (Angle in Degree)		MP to 8 (Angle in Degree)	
	Pre	Post	Pre	Post	Pre	Post	Pre	Post	Pre	Post	Pre	Post
Time interval												
Mean	11.91±2.1	11.97±2.4	8.79±3.1	10.5±3.2	10.6±2.6	11.8±2.3	0.76±0.2	0.90±0.7	52.2±2.8	53.5±3.5	68.1±5.2	70.0±6.8
P value	0.12		0.001		0.01		0.001		0.65		0.39	

Table 4: Measurement in category II ; The following table depicts the pre and post values of the category II

Parameters	Mesio-distal width of 3rd molar(mm)		J to D7(mm)		J to R7(mm)		Ratio (J-D7/8MD)		OP to 8 (Angle in Degree)		MP to 8 (Angle in Degree)	
	Pre	Post	Pre	Post	Pre	Post	Pre	Post	Pre	Post	Pre	Post
Time interval	11.68±3.2	11.60±3.2	6.41±1.2	9.91±5.2	8.56±4.2	11.3±2.2	0.59±0.2	0.89±0.3	58±7.2	56.8±5.9	69.1±4.3	74.1±4.2
P value	0.18		0.001		0.001		0.001		0.65		0.07	

role of mandibular third molars on the relapse of mandibular incisor crowding following the cessation of retention in orthodontically treated patients has been a subject of much speculation. The orthodontist should be aware of the relationship of the mandibular third molars to the remaining teeth in the mandibular arch. The main points to be decided are either these teeth will erupt or get impacted, whether they will cause crowding of the lower anterior teeth, and whether the extraction of other teeth will prevent crowding and influence their eruption.⁸

The implementation of the correct position depends on numerous factors: the development of facial structures, the sagittal growth of the skeletal bases, the resorption on the anterior border of the ramus, the mesial movement of the posterior teeth, the increase in retromolar space, the vertical uprighting, and the mesiodistal dimension of the tooth.^{9,10}

The aim of the study was to evaluate the angular changes of impacted mandibular third molars and developing mandibular third molars in first premolar extraction cases. Thus by doing this study we are assessing two factors, angulation of the third molar and the retromolar space, as a requirement for eruption of third molars.

Angular measurements, i.e. 8-OP and 8-MP represents the angular changes of the third molar. The study shows there is no significant changes in the angular measurements of the third molar with respect to the occlusal plane (OP) and mandibular plane (MP) in both of this category. Capelli,¹¹ using a sample of 60 patients who had received orthodontic treatment, including the extraction of four premolars, found that, the impaction of third molars is associated high mesial inclination of the lower third molar in the ascending ramus. Jain et al.¹¹ compared the angular changes in the developing lower third molars in both first premolar extraction and non-extraction cases. They found that premolar extractions had a positive influence on the developing third molar angulations and non-extraction therapy did not have any adverse effects. Another study by Golovcencuet L et al.¹² radiologic assessment of mandibular third molar before and after orthodontic treatment. They concluded that third molar angulation in relation with the adjacent second lower molar has significant prognostic value regardless of type of treatment, with or without extraction of premolar. Premolar extraction cases exhibit a greater increase in the number of third lower molar with favourable angulation for eruption compared to the non extraction cases. But in our study we found that premolar extraction has no effect on the third molar angulation.

All linear measurements and ratios represent the space available for the third molars to erupt. The results clearly stated that after the orthodontic treatment with first premolar extraction the available space for the eruption of third molar increases. Our results are in agreement with Jain et al.¹¹ But this can also be due to two other factors such as anchorage and mandibular growth. We have considered

cases with maximum anchorage consideration. In maximum anchorage cases, there is 25 percentage of anchor loss.¹³ In a study, Un-Bong Baik et al.¹⁴ they estimated factors associated with spontaneous angular changes of impacted mandibular third molars due to second molar protrusion. They concluded that space available for third molar eruption before and after second molar protrusion are not associated with the uprighting of erupting lower third molars. So the increase in space can be caused by anchor loss.

Another factor that can cause an increase in the available space for third molars is mandibular growth. The age groups that have been considered in this study have the chances of showing late mandibular growth. This can cause increase in space between the body and ramus of the mandible for the eruption lower third molar.¹⁵ According to Kaplan,¹⁶ an insignificant resorption of the anterior border of the ramus is apparently responsible for impaction of third molar. Even if the study does not involve a control group to assess this influence, there are various studies that compare extraction and non-extraction cases. In these studies it has been observed that space available for the third molar has increased in both of the cases, with greater space in extraction case. So in spite of the remodelling happening in the ascending ramus as a part of growth of mandible, extraction has an influence on creating space for the eruption of third molars.

Shortcoming of this study is that anchorage and growth of the mandible have not been considered. This would have been overcome by doing a comparative study between extraction and non-extraction cases. By considering non-extraction cases we could have understood how much influence the anchorage and growth of mandible has on availability of space for the eruption of third molars at the end of orthodontic treatment.

5. Conclusions

1. Premolar extractions had a positive effect on the available space for the third molar to erupt.
2. There were no significant angular changes of impacted mandibular third molars and developing third molars in first premolar extraction cases with maximum anchorage consideration.

6. Source of Funding

None.


7. Conflict of Interest

The authors declare that there is no conflict of interest.

References

1. Hattab FN, Alhajja E. Radiographic evaluation of mandibular third molar eruption space. *Oral Surg Oral Med Oral Pathol Oral Radiol Endodontol.* 1999;88:285–91. doi:10.1016/s1079-2104(99)70029-6.
2. Graber TM, Kaineg TF. The mandibular third molar: its predictive status and role in lower incisor crowding. *Proc Finn Dent Soc.* 1981;77:37–44.
3. Forsberg CM, Vingren B, Wesslen U. Mandibular third molar eruption in relation to available space as assessed on lateral cephalograms. *Swed Dent J.* 1989;13:23–31.
4. Türköz Ç, Ulusoy Ç. Effect of premolar extraction on mandibular third molar impaction in young adults. *Angle Orthodontist.* 2013;83:572–7. doi:10.2319/101712-814.1.
5. Bishara SE. Third molars: A dilemma! Or is it? *Am J Orthod Dentofac Orthop.* 1999;115(6):628–33. doi:10.1016/s0889-5406(99)70287-8.
6. Kim TW, Årtun J, Behbehani F, Artese F. Prevalence of third molar impaction in orthodontic patients treated nonextraction and with extraction of 4 premolars. *Am J Orthod Dentofac Orthop.* 2003;123:138–45. doi:10.1067/mod.2003.13.
7. Alhajja E, AlBhairan HM, AlKhateeb SN. Mandibular third molar space in different antero-posterior skeletal patterns. *Eur J Orthod.* 2011;33:570–6. doi:10.1093/ejo/cjq125.
8. Björk A, Jensen E, Palling M. Mandibular growth and third molar impaction. *Acta Odontol Scand.* 1956;14(3):231–72. doi:10.3109/00016355609019762.
9. Tarazona B, Paredes V, Llamas JM, Cibrian R, Gandía JL. Influence of first and second premolar extraction or non-extraction treatments on mandibular third molar angulation and position. A comparative study. *Med Oral Patol Oral Cir Bucal 2010 Sep 1;15(5):e760-6.* 2010;15(5):e760–6.
10. Kaplan RG. Some factors related to mandibular third molar impaction. *Angle Orthod.* 1975;45(3):153–8.
11. Jain S, Valiathan A. Influence of First Premolar Extraction on Mandibular Third Molar Angulation. *Angle Orthod.* 2009;79:1143–8. doi:10.2319/100708-525r.1.
12. Golovcencu L, Anistoroaei D, Toma V, Cernei ER, Botezatu AC, Zegan G. Radiologic assessment of lower third molar before and after orthodontic treatment. *Rom J Oral Rehabil.* 2019;11(2). doi:10.15713/ins.ijdhc.2.
13. Nanda R, Kluhlberg A. Biomechanical Basis of Extraction Space Closure. In: *Biomechanics in clinical orthodontics.* Philadelphia: W.B. Saunders; 1997. p. 156–82.
14. Baik UB, Bayome M, Abbas NH, Park JH, Lee UL, Kim YJ. Factors associated with spontaneous angular changes of impacted mandibular third molars as a result of second molar protrusion. *Am J Orthod Dentofac Orthop.* 2019;156(2):178–85.
15. Premkumar S. *Textbook of craniofacial growth.* JP Medical Ltd; 2011.
16. Kaplan RG. Some factors related to mandibular third molar impaction. *Angle Orthod.* 1975;45(3):153–8.

Author biography

Shanthi Velachery, Post Graduate Student  <https://orcid.org/0000-0001-9226-182X>

Shahir Backer, Post Graduate Student

Sandeep Shetty, Professor

Katheesa Parveen, Senior Lecturer

Nandish Kumar Shetty, Professor

Akhter Husain, Dean and Professor

Cite this article: Velachery S, Backer S, Shetty S, Parveen K, Shetty NK, Husain A. Angular changes of impacted mandibular third molars and developing mandibular third molars in premolar extraction cases- A retrospective radiographic study. *Int J Oral Health Dent* 2021;7(1):43-47.