

**Short Communication****Assessment of outcome of root canal treatment performed on an incomplete fracture non vital permanent first molar****Sneha Singgam<sup>1,\*</sup>**<sup>1</sup>Dept. of Conservative Dentistry and Endodontics, Dental College, JNIMS, Manipur, India**ARTICLE INFO***Article history:*

Received 15-07-2020

Accepted 24-07-2020

Available online 10-10-2020

*Keywords:*

Cracked teeth

Non vital teeth

Tooth infraction

**ABSTRACT**

Tooth infraction is usually of three types 1) confined to enamel (craze lines) and usually do not require treatment 2) related to cuspal fracture that typically do not involve pulp 3) more centrally located that do involve the pulp. Vertical root fracture (VRF) are longitudinal fracture that originate in root of teeth in contrast to tooth infraction that originate in the crown. VRF occurs usually in endodontically treated teeth. This case report represent tooth infraction originating in the tooth crown on the distal marginal ridge and propagating into the pulp chamber and DEJ (dentino enamel junction). Root canal treatment was performed and in a 7 month follow up period, there was a remarkable improvement in the supporting periodontal structures with bone deposition/remodelling in the crestal and furcation area/region and patient was quite satisfied with the treatment outcome.

© 2020 Published by Innovative Publication. This is an open access article under the CC BY-NC license (<https://creativecommons.org/licenses/by-nc/4.0/>)

**1. Introduction**

Tooth infraction is usually of three fairly distinct types 1) confined to enamel (craze lines) and usually do not require treatment 2) related to cuspal fracture that typically do not involve pulp and 3) more centrally located that do involve the pulp. Clinically, symptomatic tooth infractions are confusing because they often mimic symptoms of other conditions such as earache, sinusitis, temporomandibular joint dysfunction, and other neurological pain conditions like trigeminal neuralgia.<sup>1</sup> When the problem is difficult to identify, it can lead to a long standing pain condition that becomes more diffuse and makes localization of the offending tooth very difficult.<sup>2</sup> The act of chewing is also implicated in the development of infraction.<sup>2</sup> Masticatory forces from repeated occlusal loads and perhaps certain types of food can contribute to such problem.<sup>2</sup> As for the proper diagnosis, patient's history and detail clinical examination are required. Visual examination with the use of transillumination and methylene blue dye is required for examination of disease. Additionally, magnification with

the use of microscope can be very valuable.<sup>3</sup> As for all treatment efforts therefore are attempts- some better than others- at preventing separation of the hard tissues entities, and perhaps keeping bacteria from colonizing the space caused by infractions.

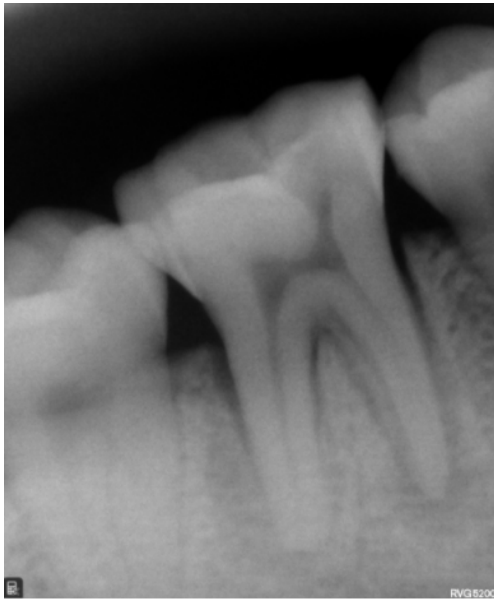**2. Short Communication**

A 20-year old male patient presented with the complaint of discomfort on chewing in the right posterior mandibular molar. He went to a dental clinic few years back and was diagnosed with a cracked tooth and medications were prescribed to relieve the pain. As he became apprehensive and worried, he chose to continue further treatment. On dental examination generalised deposits of calculus and stains were observed with irregularly placed malposed teeth. On further examination, pits and fissures caries with fine craze lines were observed in lower right posterior first molar. On percussion, there was no tenderness and lingual cuspal fracture was observed. A periodontal pocket of about 3 mm was seen on distal aspect of the tooth. As it was unable to diagnose the definite cause of the periodontal pocket an IOPA radiograph was taken. Radiolucency involving pulp

\* Corresponding author.

E-mail address: [snehabubly6@gmail.com](mailto:snehabubly6@gmail.com) (S. Singgam).

was observed on the coronal mesial aspect of the tooth, initially expected to be dental caries but later diagnosed as internal resorption. A fine radiolucent line was observed in distal coronal aspect with widening of the periodontal ligament space and bone loss in the mesial and distal interdental crestal and also the furcation region.[Figure 1]

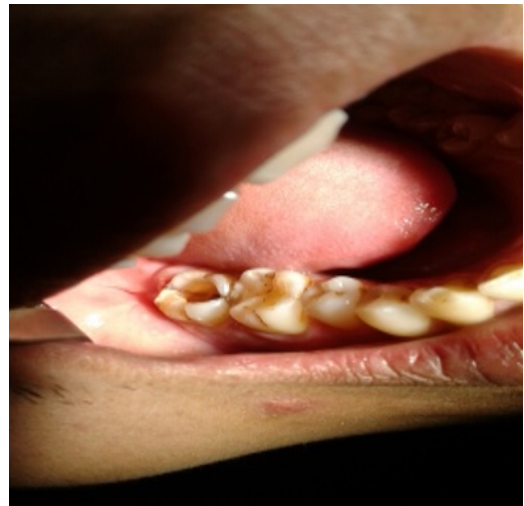

**Fig. 1:**

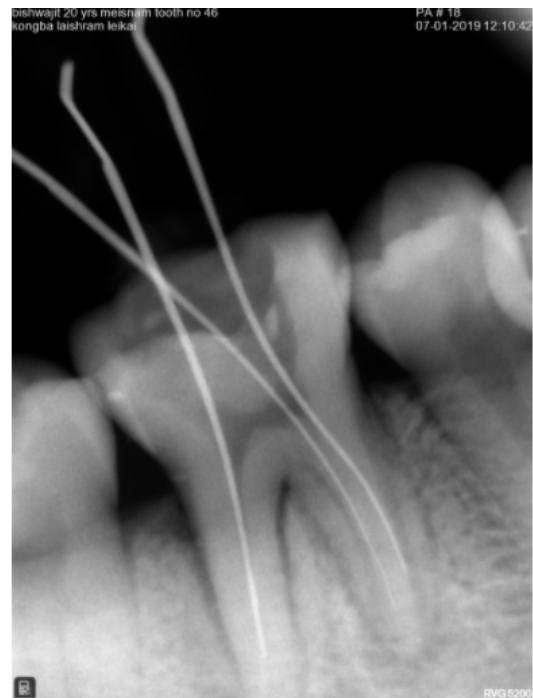To confirm the diagnosis, exploratory excavation was made using TF 20 (non cutting tapered diamond bur) from the mesial discoloured occlusal surface till the distal occlusal surface. Later no dental caries was found and craze/cracked line was observed on distal marginal ridge and wall of the tooth. On further deepening the cavity, the fractured line involved the pulp chamber propagating radicular region and therefore the case was diagnosed as tooth infraction with crack teeth –incomplete vertical fracture involving pulp.[Figure 2].

The patient was advised about the treatment and the possibility of failures and success of treatment outcome. Oral prophylaxis was done and local anaesthesia was given and conventional access cavity was prepared using TF 20 bur. Canals were located with 10 k file and irrigated with copious amount of 3% sodium hypochlorite using 5 ml single use syringe with needle size 0.56×25 mm. Calcium hydroxide intracanal medicament was placed and temporisation was given with zinc oxide eugenol cement. Patient was advised not to chew anything hard until the completion of ongoing root canal treatment.

On second visit, the patient did not complain of pain and swelling. Working length was determined (mb= 18 mm, ml=18 mm, d=20 mm)[Figure 3]. The mesial canals were calcified and the patency were not established till the apical foramen.



**Fig. 2:**

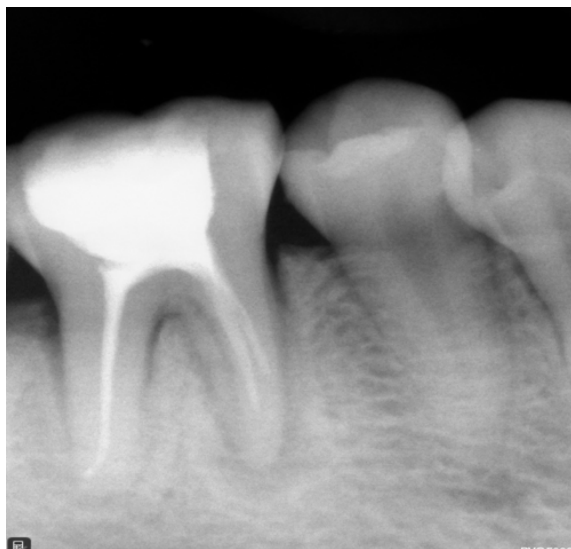

**Fig. 3:**

On the next day, i.e third visit, cleaning and shaping was done with hyflex controlled memory niti rotary file. The mesial canals were prepared till #20.06 and distal canal till #30.04 with endomotor at 500 rpm, 2.5 N-cm torque (coltene/whaledent,usa). Intracanal medicament was placed followed by temporisation and patient was scheduled for the next appointment after a week.

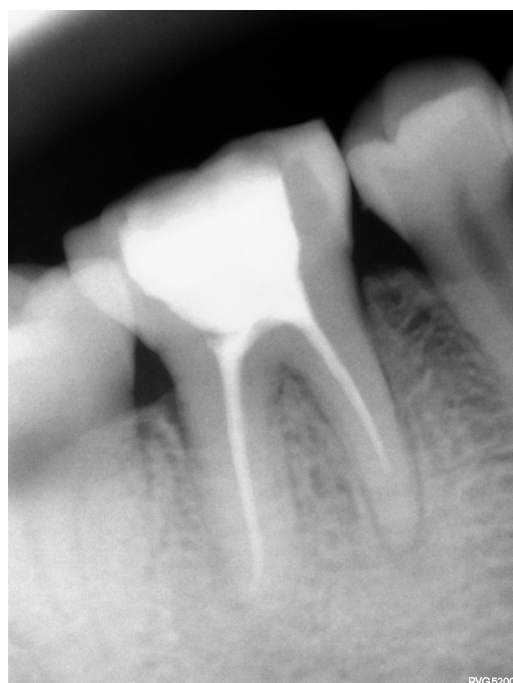On the fourth visit after about one month, there was a remarkable improvement and obturation was done with gutta percha and zinc oxide eugenol paste as sealer using cold lateral condensation technique. The core was

restored with zinc oxide eugenol cement initially.[Figure 4]. The patient was constantly reminded about the outcome of treatment (favourable/non favourable prognosis) and scheduled for the next appointment after 1 month, 3 month and 6 month period.



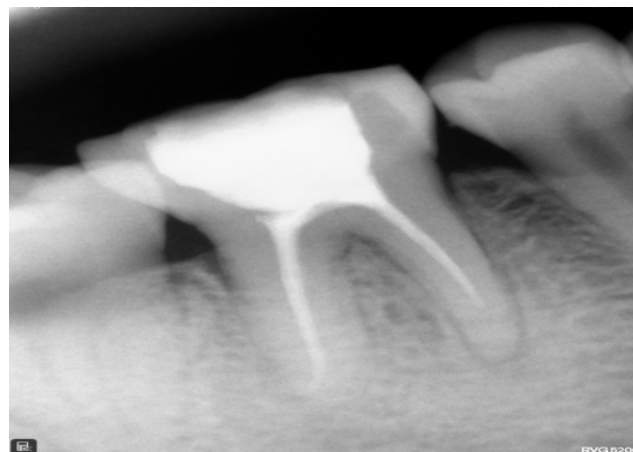**Fig. 4:**

After one month, patient was completely asymptomatic with healing periodontal status and radiographs showed healing bone [Figure 5] but the patient did not report at third month due to personal reasons.

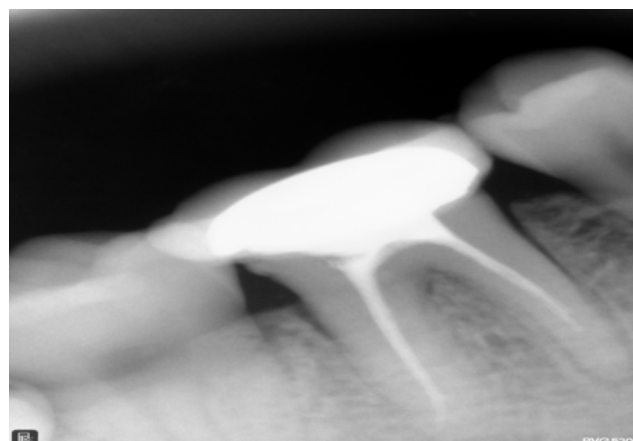


**Fig. 5:**

At sixth month, IOPA radiograph was taken. On radiograph, bone remineralization/ remodelling was observed on mesial/distal crestal bone and furcation region too with improved periodontal ligament attachment and supporting structures.[Figure 6]. Patient was quite satisfied with the outcome. Glass ionomer type ix post endodontic core build up was given and patient was advised for the next appointment after 10-20 days. After about 2 weeks, a metal ceramic crown or porcelain fused to metal crown was placed and patient was advised to maintain a regular follow up.[Figure 7]



**Fig. 6:**



**Fig. 7:**

### 3. Discussion

Cracked tooth is one of the common or frequently encountered case among common dental problems. Prevalence rate of cracked teeth is usually high among female of above 40 years as reported by Cameron et al,<sup>1</sup> although one study by Roh et al<sup>4</sup> showed almost equal distribution between gender groups. Clinical management

of crack or fracture depends on its extent. Prevention of a potential crack or fracture is a fundamental principle and early detection is imperative. Sometimes, tooth infraction do occur due to the result of accumulating unobserved trauma from either normal or excessive occlusal forces that are repetitively applied without patient's awareness<sup>2</sup> Usually treatment of cracked teeth takes five to ten years Krell et al but in our study since the crack was diagnosed early enough duration took around six to seven months with minimal treatment expenditure which is similar to studies by Minocha et al.<sup>5</sup> Based on the study done by Hassan et al<sup>6</sup> an exploratory excavation was done to obtain visual diagnosis. Later IOPA radiographs were taken however diagnosis of cracked tooth syndrome by radiographs is usually questionable, as fractures propagate in a mesiodistal direction; parallel to the plane of the film.<sup>7</sup> Radiographs may be helpful in assessing the status of the pulp and periodontium, and for excluding other dental pathology.<sup>8</sup> In our case since there was pulpal involvement (non vital tooth) root canal therapy was done with regular interval of placement of intracanal medicament in every scheduled appointment similar to studies by Mahgoli et al<sup>9</sup> and Mamoun et al.<sup>10</sup> On the second, third and fourth appointment there was remarkable improvement and patient was quite happy with the outcome. After six months intracoronal restoration or post core restoration was done using glass ionomer type ix similar to Minocha et al<sup>5</sup> as Glass ionomers and adhesives have been previously used for bonding of broken segments of teeth as in cusp fractures when the crack has not invaded the cemento-enamel junction. On the other hand, it would result in better stress distribution in the cement and dentin and would prevent stress accumulation in the cement at the crack site. After 20 days a full porcelain fused to metal crown was placed and patient was advised to maintain regular follow up which may take one to two years as similar to studies by Kanamura J et al.<sup>11</sup> Berman and Kuttler stated that necrotic teeth with longitudinal cracks should be preferably extracted. Also, teeth with deep periodontal pockets have a poor prognosis. However Sim et al<sup>12</sup> reported 92% success rate following root canal treatment of teeth with cracks involving their pulp.

#### 4. Conclusion

There is very little consensus among practitioners as to which cracked teeth require protective restorations, what the restoration should be, or the appropriate timing of restoration. Duration of treatment is one factor while contemplating patients compliance and minimal treatment expenditure with lesser time duration of treatment would favour in such type of cases. This present study also suggest that a crown prevents the flexure of the weakened

supragingival tooth structures, by transferring the stress of occlusal forces to the crown section of the tooth structure circumscribed by the crown margin. Thus a full crown increases the biomechanical stability of a cracked tooth without the need for tooth extraction which is cost effective with beneficial prognostic outcome.

#### 5. Source of Funding

None.

#### 6. Conflict of Interest

None declared.

#### 7. Acknowledgement

The author thank Dr Oinam Joychandra Singh Associate Professor Dept. of Pharmacology, JNIMS. Manipur for his immense contribution in writing the manuscript.

#### References

1. Cameron CE. Cracked-tooth syndrome. *J Am Dent Assoc.* 1964;68(3):405–11.
2. Ailor JE. Managing incomplete tooth fractures. *J Am Dent Assoc.* 2000;131(8):1168–74.
3. Geurtsen W, Schwarze T, Gunay H. Diagnosis, therapy, and prevention of the cracked tooth syndrome. *Quintessence Int.* 2003;34:409–17.
4. Roh BD, Lee YE. Analysis of 154 cases of teeth with cracks. *Dent Traumatol.* 2006;22:118–23.
5. Minocha N. Management of cracked teeth: A case report. *Endodontol.* 2007;19:39–44.
6. Hassan S, Singh K, Salati N. Cracked tooth syndrome: Overview of literature Shamimul Hassan, Kuldeep Singh1. *Int J Appl Basic Med Res.* 2015;5(3):164–8.
7. Türp JC, Gobetti JP. The cracked tooth syndrome: An elusive diagnosis. *J Am Dent Assoc.* 1996;127(10):1502–7.
8. Lynch CD, McConnell RJ. The cracked tooth syndrome. *J Can Dent Assoc.* 2002;68:470–5.
9. Mahgoli HA, Arshad M, Rasouli K. Restoration of endodontically treated cracked maxillary teeth: A case series. *Clin Case Rep.* 2019;7(10):1951–6.
10. Mamoun JS, Napoletano D. Cracked tooth diagnosis and treatment: An alternative paradigm. *Eur J Dent.* 2015;09(02):293–303.
11. Kanamaru J, Tsujimoto M, Yamada S, Hayashi Y. The clinical findings and managements in 44 cases of cracked vital molars. *J Dent Sci.* 2017;12(3):291–5.
12. Pradeepkumar AR, Arunajatesan S. Cracks and fractures in teeth. *Restor Dent Endod.* 2017;2(1):25–30.

#### Author biography

Sneha Singgam Assistant Professor

**Cite this article:** Singgam S. Assessment of outcome of root canal treatment performed on an incomplete fracture non vital permanent first molar. *Int J Oral Health Dent* 2020;6(3):242-245.