

Single Visit Apexification with Biodentine and Platelet Rich Fibrin

Niharika Naithani^{1,*}, Gurudutt Nayak², Himanshu Aeran³, Rahul Dhani⁴

¹PG Student, ²Prof & Head, Dept. of Conservative Dentistry and Endodontics,

³Prof & Head Dept. of Prosthodontics, Director Principal,

⁴Senior Lecturer, Dept. of Prosthodontics,
Seema Dental College & Hospital, Rishikesh.

***Corresponding Author:**

E-mail: drniharika.naithani@gmail.com

ABSTRACT

An immature tooth with pulpal necrosis causes the root canal to be wide, with thin and fragile walls, and the apex remains open. Endodontic treatment options for such teeth consist of conventional apexification procedure with and without apical barriers. Biodentine is new calcium silicate based cement that exhibits physical and chemical properties similar to those described for certain Portland cement derivatives but with distinct advantages. This article demonstrates single visit apexification using Biodentine as an apical barrier along with platelet rich fibrin as internal matrix.

Key words: Apexification, biodentine, internal matrix, platelet rich fibrin, single visit.

Access this article online	
Quick Response Code:	Website: www.innovativepublication.com
	DOI: 10.5958/2395-499X.2015.00011.8

INTRODUCTION

When tooth with incomplete root formation undergoes pulp necrosis due to trauma, caries or other pulpal pathosis, dentin formation is interrupted and root development ceases. Consequently, the root canal is wide, with thin and fragile walls, and the apex remains open.^[1] Apexification is defined as a method to induce a calcified barrier in a root with an open apex or the continued apical development of an incomplete root in teeth with necrotic pulp. The goal of this treatment is to obtain an apical barrier to allow compaction of root filling material.^[2]

Traditionally, the formation of the barrier was accomplished using calcium hydroxide in a multi visit procedure. The disadvantages associated with this procedure are the unpredictable time needed to form an apical barrier, the need for multiple visits, patient compliance, re-infection due to loss of temporary restoration, and also predisposition of the tooth to fracture.^[3,4] Another disadvantage of this technique is the nature of the barrier, which although apparently calcified, is actually porous and is sometimes even found to contain small amounts of soft tissue.^[5]

Considering the various drawbacks associated with calcium hydroxide apexification, the use of apical plug method seems to be a suitable alternate treatment plan for such cases. A number of materials have been proposed for this purpose including tricalcium

phosphate, freeze dried bone, freeze-dried dentin, collagen calcium phosphate, mineral trioxide aggregate (MTA) and Biodentine.

One of the inherent problems associated with this technique is the extrusion of the material across the apex. The use of an artificial barrier or a matrix placement in the area of bone destruction is advised as it provides a base on which the sealing material can be placed and packed. Several materials have been advocated to create a matrix. These include calcium hydroxide, hydroxyapatite, absorbable collagen, calcium sulphate, and autologous platelet rich fibrin membrane (PRF).^[6,7]

Biodentine is a calcium silicate-based material introduced in 2010 by Gilles and Olivier and is composed of a tricalcium silicate powder packaged in capsules (0.7 g) to be mixed with a liquid phase (0.18 mL) containing calcium chloride.^[8]

The aim of the present article is to report the successful closure of root apex in a pulpless permanent maxillary central incisor with wide open apex using Biodentine in combination with a PRF as matrix.

CASE REPORT

A 19 Year old male patient reports to the Department of Conservative Dentistry and Endodontics at Seema Dental College and Hospital with a chief complaint of fractured upper front left tooth. Patient gives a history of trauma of about 12 years back.

Clinical examination revealed mildly discolored upper left maxillary central incisor with Ellis Class III fracture (**Fig. 1**). Radiographic examination revealed periapical radiolucency and an immature wide open apex (**Fig. 2**). Tooth was not tender to palpation and percussion. The vitality of the tooth was performed using thermal and electric pulp test which gave a negative response. A diagnosis of necrotic pulp with

apical periodontitis was made. Patient was informed of the existing condition and endodontic treatment with single-visit apexification was suggested.

Following rubber dam placement, access opening was done and working length was determined radiographically (**Fig. 3**). Cleaning and shaping was performed with K-files (Mani, Prime Dental, Mumbai) using conventional preparation technique. Root canal irrigation was performed with 2ml of 3 % sodium hypochloride (NaOCl) between change of instruments followed by 17% ethylenediamine tetra acetic acid (EDTA) (MD Cleanser, Meta Biomed, Korea) and saline. Root canal was then dried with sterile paper points. Calcium hydroxide (Metapaste, Meta Biomed, Korea) was placed in the root canal, and the access cavity was sealed with IRM (Caulk/Dentsply, Milford, DE, USA). The patient was recalled after 4 weeks.

In the subsequent appointment, under isolation, calcium hydroxide dressing was removed by hand instrumentation and irrigation with 3% NaOCl. Final irrigation was done with 17% EDTA followed by 2% chlorhexidine (Chlor X, PrevestDentPro, India). The root canal was then dried with sterile paper points (Dentsply Maillefer, Ballaiguise, Switzerland).

Simultaneously PRF membrane preparation was carried out, while the clinical procedure was being performed. A 8.5 ml sample of whole blood was drawn by venipuncture of antecubital vein of the patient's right arm and transferred into a 10 ml sterile glass test tube without anticoagulant and was immediately centrifuged (REMI Laboratory Instruments, Mumbai, India) at 3000 revolutions per minute for 10 minutes. The resultant product consisted of three layers: topmost layer consisting of acellular platelet poor plasma, PRF clot in the middle and red blood cells at the bottom. With a sterile tweezer the PRF clot was removed and squeezed between sterile gauze to drive out fluids trapped between in the fibrin to obtain an autologous PRF membrane. The freshly prepared PRF membrane was fragmented, and incrementally placed into the root canal and gently compacted using pre-fitted hand pluggers slightly beyond the apex into the bony space formed due to the periapical lesion in order to achieve a matrix at the level of the apex.

Biodentine was mixed according to the manufacturer's instructions and was carried into the canal with the help of MAP system (Roydent, Dental Products, Johnson City, TN, USA) and was condensed against the PRF matrix using pre-fitted hand pluggers. Several increments were required to form an apical plug of 4 mm thickness, which was confirmed radiographically (**Fig. 4**). Following the placement of Biodentine over the barrier, butt-end of a paper point was used to clear out any excess material from the walls. After 12 minutes, the hardness of the Biodentine was examined using a plunger to confirm its set.

Over this hard set Biodentine, thermoplastised gutta-percha was backfilled. (Calamus Dual, Dentsply

Maillefer, Ballaiguise, Switzerland) with AH Plus resin sealer (DentsplyDeTrey, Konstanz, Germany) (**Fig. 5**). The tooth was immediately restored with a composite restoration (Tetric N Ceram, Ivoclar Vivadent, Schaan, Liechtenstein) and in subsequent visits an all ceramic crown was placed (**Fig. 6a, 6b**). During six months follow up the patient remained asymptomatic with restored aesthetics and functions.

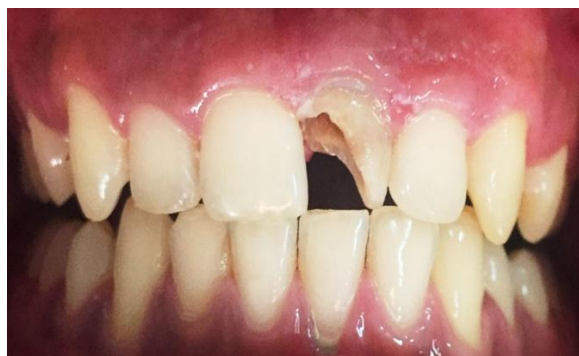

Fig. 1: Preoperative clinical photograph

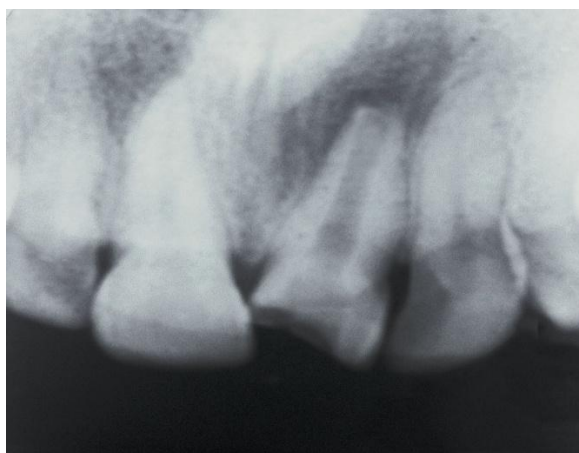

Fig. 2: Preoperative radiograph

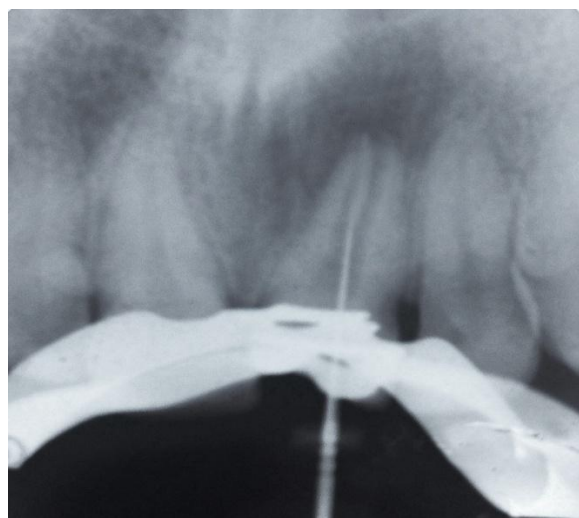


Fig. 3: Working length determination

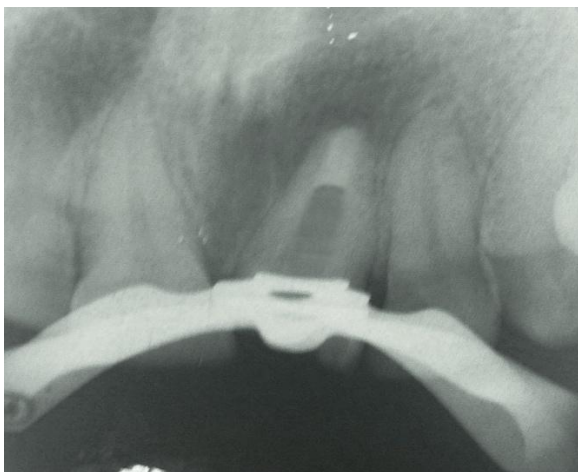


Fig. 4: Apical plug formed with Biodentine

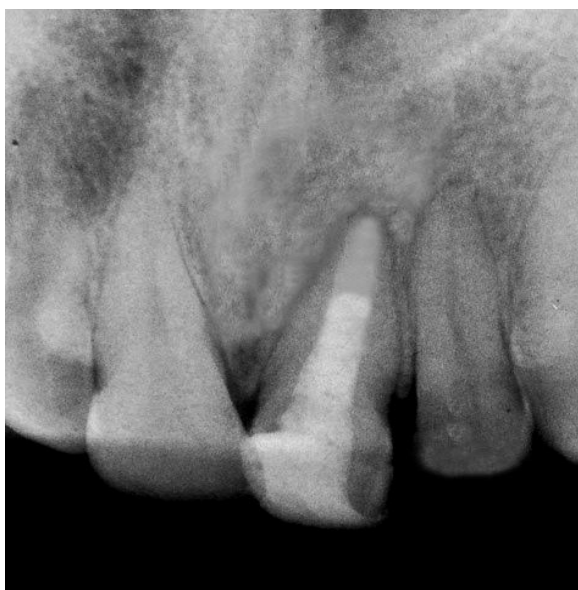

Fig. 5: Backfill with thermoplastised guttapercha and restored with composite

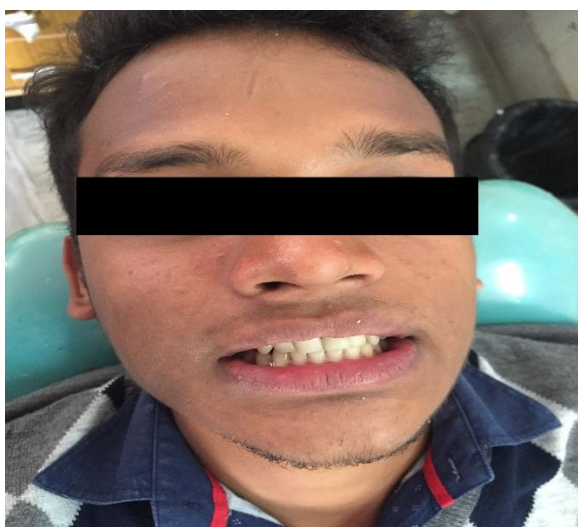

Fig. : 6(a)

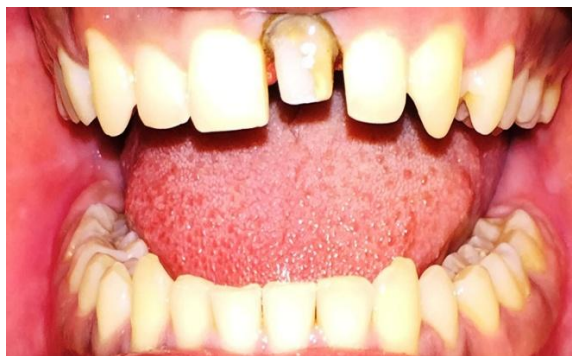

Fig. : 6(b)

Fig. 6a, 6b: All ceramic crown given to restore aesthetics and functions.

DISCUSSION

Biodentine has been developed as a permanent dentine substitute material whenever original dentine is damaged. The material with dentin-like mechanical properties can be used on both crowns and roots. Biodentine consists of a powder in a capsule and liquid in a pipette. The highly purified powder is manufactured in a laboratory using the sol-gel method. Calcium chloride present in liquid quickens the reaction. The working time of Biodentine is up to 6 minutes with a final set at around 10-12 minutes. This represents a great improvement compared to the other calcium silicate dental materials (ProRoot MTA), which set in more than 2 hours.^[8]

There are crystalline precipitates which are formed through interaction of calcium and hydroxyl ions released from set material with phosphates which give biodentine a marginal sealing ability.^[9, 10] Bioactivity of Biodentine is indicated by apatite formation after immersion in phosphate solution^[11]. Comparisons of calcium and silicon done by Han and Okiji showed their uptake by adjacent root canal dentine in the presence of phosphate buffered saline. In both MTA and Biodentine there is formation of a layer which eventually thickens over a period of 30 to 90 days but it is seen that it is more thicker for Biodentine.^[12]

It is crucial for biodentine to limit to apex and not extrude otherwise this extruded material may cause irritation and persistence inflammatory reaction. It may also complicate the repair process.^[11] Introduced in 1992 by Lemon, the internal matrix helps to prevent the extrusion. Though earlier it was designed for root perforations.^[13]

PRF is another alternative which can be used as internal matrix over which the sealing material in this case Biodentine can be placed. PRF derived from the blood has a healing property and is easily accepted by the body. It consists of platelets, leukocytes, cytokines and stem cells.^[14] PRF has osteogenic property. It contains platelets which can release platelet-derived growth factor (PDGF) and insulin-like growth factor (IGF), upto one week.^[15]

CONCLUSION

Biodentine represents a great improvement compared to the other calcium silicate dental materials. The mechanical properties of Biodentine are similar to those of natural dentine. This material is stable, less soluble, non-resorbable, hydrophilic, and easy to prepare and place, needs much less time for setting and produces a tighter seal. In this case report use of Biodentine to achieve single visit apexification of open apex showed promising results.

REFERENCES

1. Komabayashi T, Spångberg LS. Comparative analysis of the particle size and shape of commercially available mineral trioxide aggregates and Portland cement: A study with a flow particle image analyzer. *J Endod* 2008;34:94-8.
2. Trope M. Treatment of immature teeth with non vital pulps and apical periodontitis. *Endotopic* 2007; 14:51-9.
3. Felipe MC, Felipe WT, Marques MM, Antoniazzi JH. The effect of renewal of calcium hydroxide paste on the apexification and periapical healing of teeth with incomplete root formation. *IntEndod J.*2005;38:436-442
4. Metzger Z, Solomonov M, Mass E. Calcium hydroxide retention in wide root canals with flaring apices. *DentTraumatol.* 2001; 17:86-92.
5. Binnie WH, Rowe AH. A histological study of periapical tissues of incompletely formed pulpless teeth filled with calcium hydroxide. *J Dent Res.* 1973;52:1110-1116
6. Mesimeris V, Sade E, Baer PN. Calcium sulfate as a biodegradable barrier membrane: a preliminary report on the "Surgiplast" technique. *Periodontal ClinInvestig.* 1995;17:13-16
7. Bargholz C. Perforation repair with mineral trioxide aggregate: a modified matrix concept. *IntEndod J.*2005;38:59-69
8. Septodont Biodentine™ Active Biosilicate Technology™. Scientific file 2010
9. Camilleri J. Characterization of hydration products of mineral trioxide aggregate. *IntEndod J.*2008;41:408-417
10. Tay FR, Pashley DH, Rueggeberg FA, Loushine RJ, Weller RN. Calcium phosphate phase transformation produced by the interaction of the portland cement component of white mineral trioxide aggregate with a phosphatecontaining fluid. *J Endod.* 2007; 33:1347-1351.
11. Goldberg M. Biocompatibility or cytotoxic effects of dental composites. Oxford: Coxmoor Publishing Co.; 2009. Chapter VI. Emerging trends in (bio) material researches; pp. 181-203.
12. Han L, Okiji T. Uptake of calcium and silicon released from calcium silicate-based endodontic materials into root canal dentine. *IntEndod J.* 2011;44:1081-1087
13. Lemon RR. Nonsurgical repair of perforation defects. Internal matrix concept. *Dent Clin North Am.*1992;36:439-457
14. M. Nevins, W.V. Giannobile, M.K. McGuire, R.T. Kao, J.T. Mellonig, J.E. Hinrichs, et al. Platelet-derived growth factor stimulates bone fill and rate of attachment level gain: results of a large multicenter randomized controlled trial. *J Periodontol*, 76 (2005), pp. 2205-2215
15. Daniele Angerame, Matteo De Biasi, Iva Kastrioti, Vittorio Franco, Attilio Castaldo, Michele Maglione, Application of platelet-rich fibrin in endodontic surgery: a pilot study *Giornale Italiano di Endodonzia* Volume 29, Issue 2, November 2015, Pages 51-57.