



## Case Report

# Hemisection: A conservative approach for tooth preservation

Parikh Nidhi B<sup>1,\*</sup>, Palekar Aparna U<sup>1</sup>, Biradar Basawaraj C<sup>1</sup>, Parakh Sanmay D<sup>1</sup>,  
Gupta Piyush K<sup>1</sup>, Desai Kavisha G<sup>1</sup>

<sup>1</sup>Dept. of Conservative Dentistry and Endodontics, Pravara Institute of Medical Sciences, Rural Dental College, Loni, Maharashtra, India



### ARTICLE INFO

#### Article history:

Received 08-05-2020

Accepted 10-05-2020

Available online 21-07-2020

#### Keywords:

Hemisection

Furcation

Platelet rich fibrin

### ABSTRACT

Hemisection or root resection is a conservative treatment modality for cariously destructed, furcal involvement and failure of retreatment cases. Mandibular molars which are most commonly extracted due to caries and periodontal issues are the major standpoint for occlusion. Hemisection, a treatment modality provides a ray of hope to conserve the natural tooth structure and remove only the diseased portion followed by prosthetic rehabilitation. The present case report exhibits two cases of lower mandibular first molar where one root is resected, while preserving the remaining structure and promoting healing by placing autologous platelet rich fibrin (PRF) in the socket.

© 2020 Published by Innovative Publication. This is an open access article under the CC BY-NC license (<https://creativecommons.org/licenses/by-nc/4.0/>)

## 1. Introduction

Modern advances in all phases of dentistry have provided opportunity to conserve the tooth structure and maintain functional dentition for patients.<sup>1</sup> Loss of posterior teeth may lead to various undesirable consequences. To avoid them various maintenance and prevention measures after prosthetic rehabilitation is necessary. As stated by De Van “perpetual preservation of what remains is more important than the meticulous replacement of what is missing” still rings true.<sup>2</sup>

Root resection is the process by which one of the roots of a tooth is removed at the level of the furcation, presenting with an opportunity to remove the infected part, and preserve the relatively healthy portion of the tooth, while maintaining its integrity within the socket.<sup>3</sup>

Carnevale et al. reported a survival rate of about 93% over a 10-year follow-up among patients who had undergone hemisection as the management of furcated molars instead of extraction.<sup>4</sup> The success of hemisection depends, to a large extent on case selection and following

specific endodontic, surgical, and restorative guidelines. It has been suggested that hemisection treatment modality should always be considered before complete extraction for long term beneficial results.<sup>5</sup>

## 2. Case Report 1

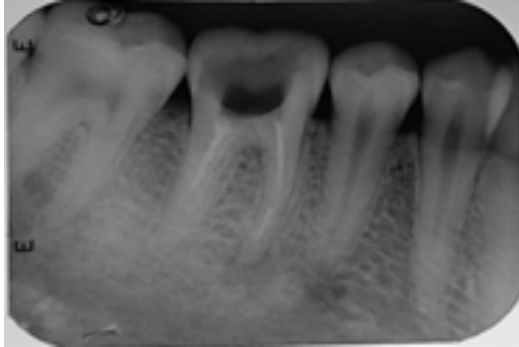
A 30-year-old male reported to the department of Conservative Dentistry and Endodontics, Rural Dental College, Loni with pain in the lower right back region of jaw since a week. Clinical examination revealed dislodged restoration with # 46 tooth with tenderness on vertical percussion. On radiographic (Figure 1) examination # 46 showed a broken instrument (file) of about 3mm long in the mesiobuccal canal along with poorly obturated other canals. Patient gave the history of root canal treatment with the same tooth 6 months ago. Based on the clinical and radiographic signs and symptoms, chronic apical periodontitis was diagnosed. After distal canal retreatment and a composite post-endodontic restoration (Figure 2), surgical resection of mesial root was planned.

The area of interest was anesthetized. A crevicular incision was made involving premolar and molar and an

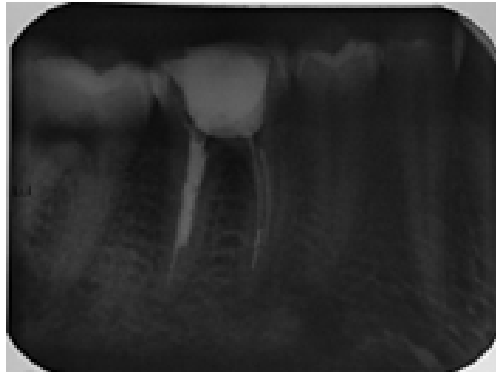
\* Corresponding author.

E-mail address: [nidhiparikh284@gmail.com](mailto:nidhiparikh284@gmail.com) (P. Nidhi B).

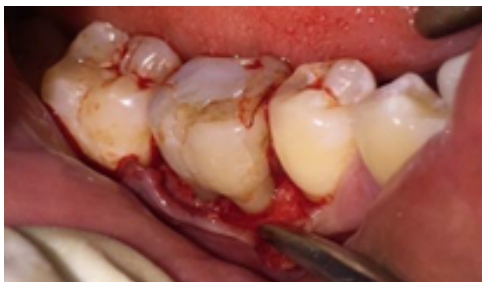envelope flap was raised using periosteal elevator (Figure 3). Using a long shank tapered fissure bur with copious irrigation, sectioning of root below the furcation fornix was done. After complete sectioning, the mesial root was extracted using a forcep (Figures 4 and 5). Odontoplasty was done. Irrigation was done using 5% povidine- iodine (Betadine) and normal saline.



**Fig. 1:** Preoperative periapical radiograph: separated instrument in the mesial root canal



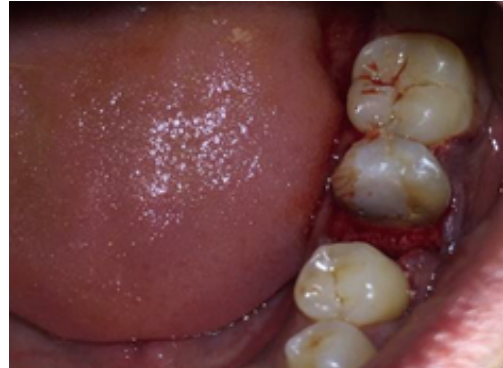**Fig. 2:** Postoperative periapical radiograph: After distal canal retreatment and a composite post-endodontic restoration



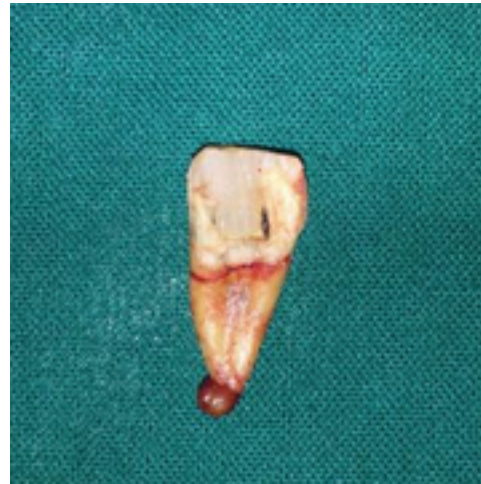**Fig. 3:** Envelope flap was reflected

PRF was prepared by patient's own blood according to the protocol mentioned in the article and placed in the socket to augment healing (Figure 6). The flap was

approximated and interrupted silk sutures were given and post-operative radiograph was taken (Figures 7 and 8). Post-operative instructions were given to the patient, analgesic and antibiotics were prescribed for 3 days and the patient was recalled after 7 days for follow up. After 2 months crown prosthesis was done for # 46 which included # 45 (Figures 9 and 10).



**Fig. 4:** Mesial root resected



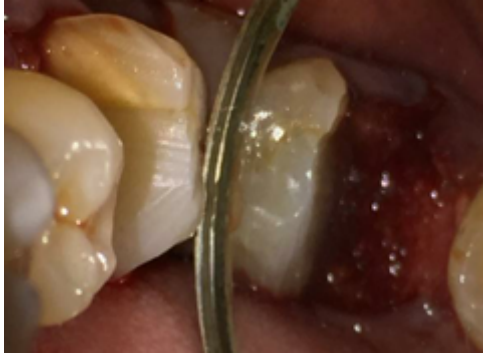**Fig. 5:** Extracted Fragment

### 3. Preparation of PRF

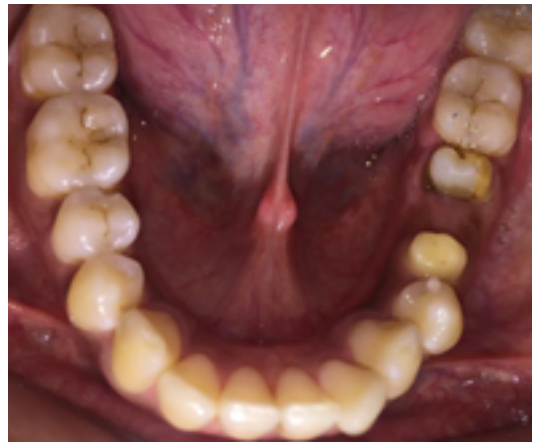For both the cases preparation of PRF was done in the same way.

### 4. Method of preparation of PRF

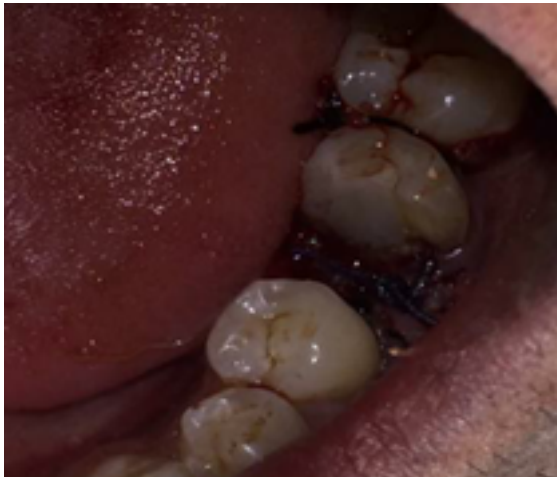Intravenous blood collection was done with scalp vein set. Needle of 21G was inserted into antecubital vein (Figure 11). Blood was collected in a 10 cc vacutainer tube without anticoagulant (Red colour clot activator tubes). After blood collection into two vacutainers, they were centrifuged at 400G force for 12mins in the centrifugation



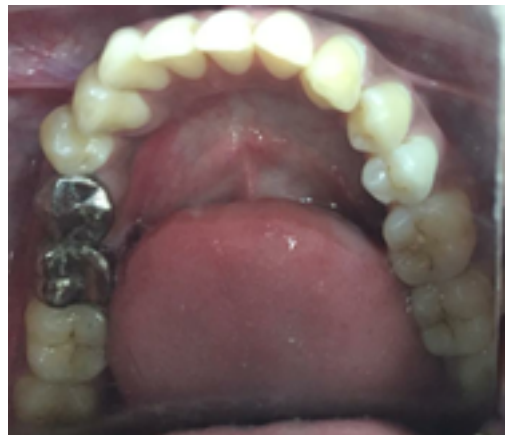**Fig. 6:** Platelet Rich Fibrin Placed into the socket



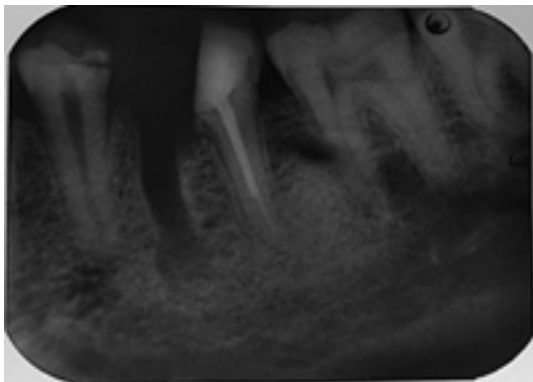
**Fig. 9:** Crown prosthesis for # 46 & # 45



**Fig. 7:** 3-0 silk sutures given



**Fig. 10:** Crown prosthesis for # 46 & # 45

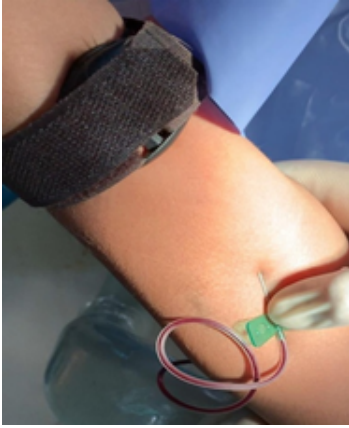

**Fig. 8:** POST-OP IOPA showing resected mesial root

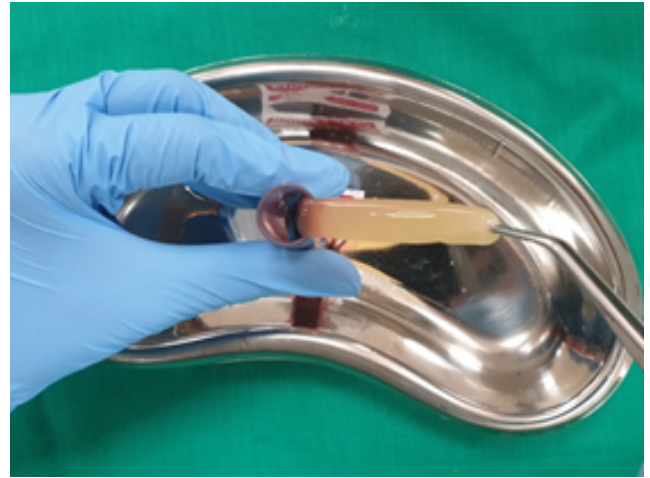machine (REMI) (Figure 12). After centrifugation three distinct layers were seen. At the top was platelet poor plasma (PPP). The middle portion of the test tube had a Platelet rich fibrin and at the bottom were RBC's (Figure 13). The clot thus formed was obtained with help of sterile tweezer and scissors by cutting in such a manner as to preserve a small RBC layer since the platelet concentration is maximum at the junction of PRF clot and RBC layer (Figure 14).

## 5. Case Report 2

A 20-year-old male reported to the department of Conservative Dentistry and Endodontics, Rural Dental College, Loni with pain in the lower left back region of jaw since a week. Clinical examination revealed deep distal caries and destructed distal crown portion with # 36. Tooth was tender on vertical percussion. On radiographic (Figure 15 ) examination # 36 caries was involving pulp and distal root nearly approaching the furcation. Based on the clinical and radiographic signs and symptoms, chronic



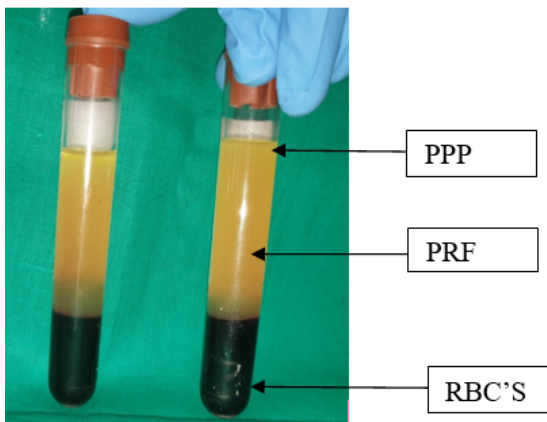
**Fig. 11:** Blood collection from antecubital vein with 21G needle



**Fig. 14:** PRF clot



**Fig. 12:** REMI centrifugation machine

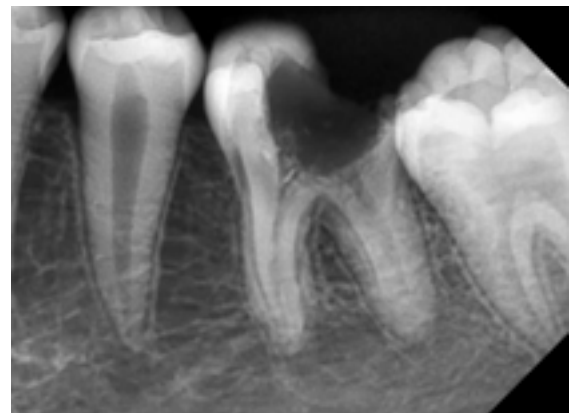


**Fig. 13:** After centrifugation

apical periodontitis was diagnosed.

After mesial canal treatment and a composite post-endodontic restoration (Figure 16), surgical resection of distal root was planned.

As mentioned in previous report following the same protocol distal root was resected, PRF was placed in socket and sutures were given. The images below depict the steps carried out.

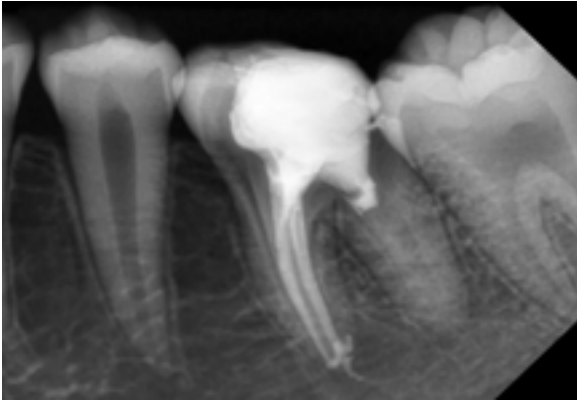


**Fig. 15:** Preoperative periapical radiograph

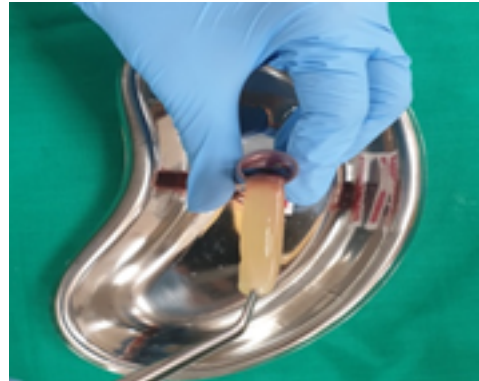## 6. Discussion

Multirrooted teeth are often treated by root resection or hemisection. Root resection is a treatment option for multirooted teeth having endodontic, periodontal, prosthetic or restorative problems.<sup>6</sup>

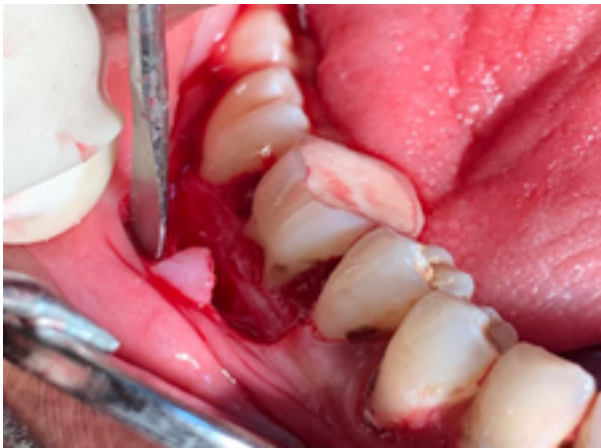In furcation involvement cases it would eliminate morphological characteristics which would aid in an area favorable for good oral hygiene.<sup>6</sup> Uncontrolled bacterial endodontic infection through apical foramen would eventually result in loss of attachment.



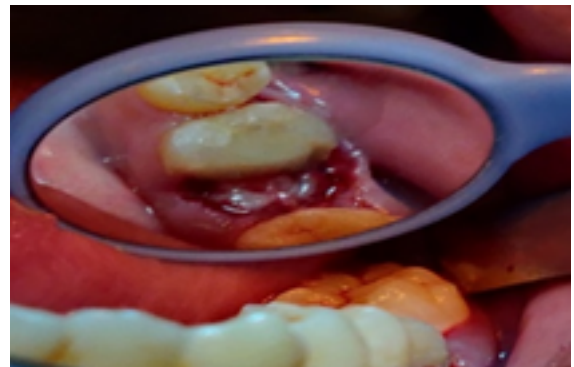
**Fig. 16:** Postoperative periapical radiograph: After mesial canal treatment and a composite post-endodontic restoration



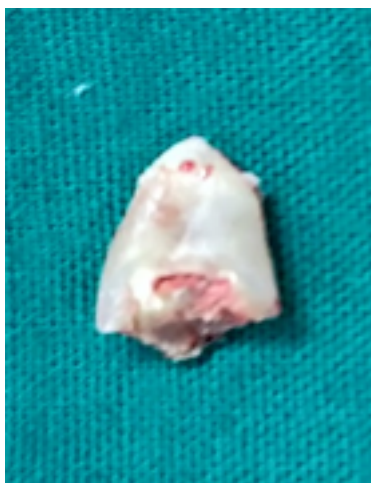**Fig. 19:** PRF Clot



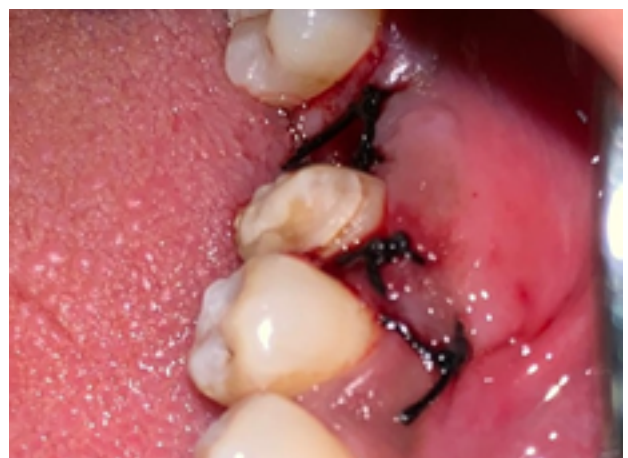**Fig. 17:** Envelope flap was reflected



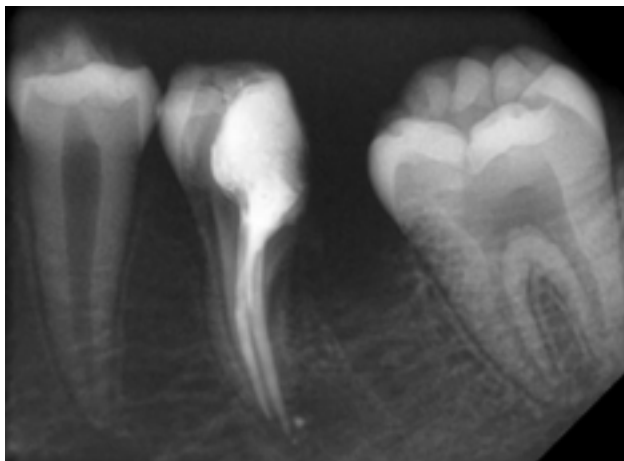
**Fig. 20:** PRF placed into the socket



**Fig. 18:** Extracted Fragment



**Fig. 21:** Silk sutures given



**Fig. 22:** Post operative IOPA showing resected distal root

The planning of resection should depend upon;

1. The root which has the least amount of bone support.
2. The furcation should be obliterated and eliminate the periodontal defect.
3. Should facilitate plaque removal.
4. The root which is most difficult to treat by endodontist.
5. The ability of the remaining root or roots of tooth to serve as abutment.

Possible disadvantages include pain and anxiety to the patient or the caries susceptibility of roots that are reshaped by grinding. If the crown does not have proper physiologic form and if the margins are defected this may lead to periodontal destruction. Even after successful treatment a combined lesion has a poor prognosis as it requires healing of both endodontic and periodontal tissues.<sup>5,7</sup> Langer et al.<sup>8</sup> reported that 54% of failed maxillary molars failed as a result of periodontal reasons, and 60% of failed mandibular molars had a root fracture. As stated by Shin-Young Park et al.<sup>9</sup> endodontic status of molars had no effect on the survival rates. The bone support of the remaining roots at the time of surgery affected the survival rate of molars with periodontal problems. When compared to the success rate of the surgical endodontics in endodontic–periodontal combined lesions the success rate is very low.<sup>9</sup> Failure rate ranges from 25% to 38%. Failure rates of root-resected molars range from 25%,<sup>9,10</sup> to 38%.<sup>11</sup> However, use of PRF in resected areas has better prognosis of the tooth. This second generation platelet concentration eliminated the risk of bovine thrombin use, thus making PRF both non toxic and non immunoreactive. Also the concentrated suspension of growth factors in platelets are involved in wound healing and are postulated as promoters of tissue regeneration.<sup>12</sup> The various growth factors released are transforming growth factor beta-1 (TGF- $\beta$ 1), Platelet derived growth factor (PDGF), vascular endothelial growth

factor (VEGF), epidermal growth factor (EGF), and insulin-like growth factor (IGF). TGF and VEGF plays major role in wound healing and neogenesis. TGF is also crucial during bone formation contributing to osteoblast precursors in chemotaxis and stimulates osteoblast deposition of mineralized tissue on the bone collagen matrix. PDGF helps in cell production and collagen formation. EGF regulates epithelial cell growth and angiogenesis, whereas IGF regulates cell growth.<sup>13</sup> Platelets being trapped in fibrin network keep the growth factors contained within this three-dimensional PRF mesh followed by the slow and gradual release of growth factors over time. Thus PRF contributes to enhanced healing provided by various growth factors which successively reduces alveolar bone loss after extraction and suppresses periodontal problems. Hence making PRF a ‘wonder material’ in advanced surgical dentistry.

## 7. Conclusion

Hemisection should be considered as another weapon in the arsenal of the dental surgeon, determined to retain and not remove the natural teeth. With recent refinements in endodontics, periodontics and restorative dentistry, hemisection has received acceptance as a conservative and dependable dental treatment and teeth so treated have endured the demands of function.

It is one of the treatments available for molars with furcation involvement and endodontic failure. The prognosis for hemisection is the same as for routine endodontic procedures provided that case selection has been correct, the endodontics has been performed adequately, and the restoration is of an acceptable design relative to the occlusal and periodontal needs of the patient. Placement of PRF post operatively gives a better prognosis for the affected tooth.

## 8. Source of Funding

None.

## 9. Conflict of Interest

None.

## References

1. Basaraba N. Root amputation and tooth hemisection. *Dent Clin North Am.* 1969;13(1):121–32.
2. DeVan MM. The nature of the partial denture foundation: Suggestions for its preservation. *J Prosthetic Dent.* 1952;2(2):210–8.
3. Agrawal V, Kapoor S, Shah N. An innovative approach for treating vertically fractured mandibular molar - hemisection with socket preservation. *J Interdiscip Dent.* 2012;2(2):141.
4. Carnevale G, Febo D, Tonelli G, Marin MP, Fuzzi C, M. A retrospective analysis of the periodontal-prosthetic treatment of molars with interradicular lesions. *Int J Periodontics Restorative Dent.* 1991;11(3):189–205.
5. DeSanctis M, Murphy KG. The role of resective periodontal surgery in the treatment of furcation defects. *Periodontol.* 2000;22(1):154–68.

6. American Academy of Periodontology. Glossary of Periodontal Terms; 2001.
7. Oh SL, Fouad AF, Park SH. Treatment Strategy for Guided Tissue Regeneration in Combined Endodontic-Periodontal Lesions: Case Report and Review. *J Endod.* 2009;35(10):1331–6.
8. Langer B, Stein SD, Wagenberg B. An Evaluation of Root Resections: A Ten-Year Study. *J Periodontol.* 1981;52(12):719–22.
9. Park SY, Shin SY, Yang SM, Kye SB. Factors Influencing the Outcome of Root-Resection Therapy in Molars: A 10-Year Retrospective Study. *J Periodontol.* 2009;80:32–40.
10. Green EN. Hemisection and root amputation. *J Am Dent Assoc.* 1986;112(4):511–8.
11. Blomlöf L, Jansson L, Appelgren R, Ehnevid H, Lindskog S. Prognosis and mortality of root-resected molars. *Int J Periodontics Restorative Dent.* 1997;17(2):190–201.
12. Anilkumar K, Geetha A, Umasudhakar, Ramakrishnan T, Vijayalakshmi R, Pameela E. Platelet-rich-fibrin: A novel root coverage approach. *J Indian Soc Periodontol.* 2009;13(1):50–4.
13. Khiste SV, Tari RN. Platelet-Rich Fibrin as a Biofuel for Tissue Regeneration. *ISRN Biomater.* 2013;2013:1–6.

## Author biography

**Parikh Nidhi B** Post Graduate Student

**Palekar Aparna U** Professor and Head

**Biradar Basawaraj C** Professor

**Parakh Sanmay D** Post Graduate Student

**Gupta Piyush K** Post Graduate Student

**Desai Kavisha G** Post Graduate Student

**Cite this article:** Nidhi B P, Aparna U P, Basawaraj C B, Sanmay D P, Piyush K G, Kavisha G D. Hemisection: A conservative approach for tooth preservation. *Int J Oral Health Dent* 2020;6(2):143-149.