



Original Research Article

Dentinal tubule occluding effect of a herbal tooth paste – An invitro scanning electron microscopy analysis

Jasjit Kaur^{1,*}, Rahul Paul², Kirti Rathee², Geetika Arora²

¹Purexa Global Pvt Ltd, East of Kailash, New Delhi, India

²Inderprastha Dental College & Hospital, Ghaziabad, Uttar Pradesh, India



ARTICLE INFO

Article history:

Received 22-05-2020

Accepted 28-05-2020

Available online 21-07-2020

Keywords:

Dentinal tubule

Herbal

Scanning electron microscope

Toothpaste

ABSTRACT

Aim: To evaluate the effects of an herbal desensitizing dentifrice on dentinal tubule occlusion by scanning electron microscopy (SEM).

Materials and Methods: 10 dentine blocks were prepared from the cervical region measuring 2mm×1.5×1.5 mm, was etched with 6% citric acid for 2 minutes, rinsed in distilled water and were desiccated.

Results: All the groups excluding control showed complete occlusion of dentinal tubule on the 30th and 45th day.

Conclusion: As the Herbal toothpaste used in this study occluded the dentinal tubules seen through scanning electron microscopy, it is found to be useful for the treatment of dentine hypersensitivity.

© 2020 Published by Innovative Publication. This is an open access article under the CC BY-NC license (<https://creativecommons.org/licenses/by-nc/4.0/>)

1. Introduction

Dentine hypersensitivity is an important issue that needs addressing both from a diagnostic and management perspective. It is described clinically as issue that needs a management an exaggerated response to anon noxious sensory stimulus.^{1,2} It is viewed as originating from the underlying exposed dentin after the enamel or cementum has been eroded away (Joshi, 2013).³ It is characterized by short, sharp pain arising from exposed dentin in response to external stimuli, typically thermal, evaporative, tactile, osmotic or chemical, and which cannot be ascribed to any other form of dental defect or disease (Pillai, 2013).⁴ Treatment of dentin hypersensitivity is challenging for both the patient and the health care provider. Hypersensitivity can resolve without treatment or may require several weeks of desensitizing agents before improvement is seen.⁵⁻⁷ There are two principal treatment options:- plug the dentinal tubules preventing fluid flow, or desensitize the nerve, making it less responsive to stimulation (Jacobsen, 2001).²

Agents which occlude the dentinal tubules includes ions or salts which are hypothesized to precipitate within the tubule like stannous ion in stannous fluoride, Oxalate ions which react with the calcium in the tooth to form in soluble calcium oxalate crystals that occlude the tubules, Strontium ions also have the property of precipitating together forming a mass that occludes the tubules, precipitates like glutaraldehyde, resins like dentin sealers, methyl methacrylate etc (Jacobsen, 2001).²

Recently herbal products like tooth pastes claim to reduce sensitivity with both desensitizing and occluding action. This tooth paste contains Spinach (Palakya), Rhubarb, Arnica and Licorice.

Palakya (spinach), rhubarb and mint contain natural oxalate compounds, which help in occluding the dentinal tubules.

2. Materials and Methods

The present study was conducted in the Department of Conservative Dentistry and Endodontics, Indraprastha College of Dental Sciences, Ghaziabad. Specimens divided into single group of 10 specimens.

* Corresponding author.

E-mail address: dr.jasjit10@gmail.com (J. Kaur).

10 dentinal blocks of thickness 2mm are prepared, etched with 6% citric acid for 2 minutes, rinsed in distilled water and specimens brushed for 2 minutes twice daily for 45 days with herbal antisensitivity toothpaste using a powered toothbrush.

2.1. Selection of teeth Inclusion criteria

10 intact human maxillary premolars indicated for extraction for orthodontic or periodontal reason were selected for the study and stored in saline.

2.2. Exclusion criteria

1. Carious teeth.
2. Restored teeth.
3. Hypoplastic teeth.
4. Fractured teeth.

2.3. Armamentarium

1. High speed contra angle hand piece.
2. No 245 carbide bur.
3. Straight hand piece.
4. Mandrel.
5. Diamond discs.
6. Power brush.
7. Scanning electronmicroscope.

2.4. Materials used

1. 6% citric acid.
2. Cold cure acrylic resin(DPI).
3. Distilled water.
4. Plaster of Paris.
5. 100% ethanol.

3. Methodology

10 extracted premolars were collected, cleaned of gross debris and sectioned labio-lingually. The specimens were placed in deionized water till dentine blocks were prepared. Each surface were wet ground to remove enamel and to expose a flat underlying dentine surface in the cervical region. Dentine blocks were prepared from the cervical region measuring 2mm ×1.5 ×1.5 mm. One block is obtained from each flat cervical dentine surface. The blocks were ultra sonicated in distilled water for 30 s to remove the particulate matter resulting from cutting. Blocks were mounted in acrylic resin to stabilize while brushing. Smear layer was removed by etching the blocks in 6% citric acid for 2 minutes and rinsed in distilled water. The blocks were stored in distilled water during the experimental period. The blocks were brushed using a power brush for 2 minutes twice daily.

Specimens were washed with distilled water, dried in desiccator for 2 days, sputter coated with thin gold layer and

subjected for SEM analysis and was scored in accordance with the tubule occlusion classification scoring system (Pathan, 2016).⁸

The 10 specimens were brushed for 2 minutes twice daily for 45 days with herbal toothpaste.

Teeth sections were assessed at baseline, 15 days, 30 days & 45 days for the occlusion of dentinal tubules due to the effect of the herbal antisensitivity paste via SEM imaging.

3.1. Scores

1. Occluded (100% of tubules occluded);
2. Mostly occluded (50% to <100% of tubules occluded);
3. Partially occluded (25% to <50% of tubules occluded);
4. Mostly unoccluded (<25% of tubules occluded);
5. Unoccluded (0%, no tubule occlusion).

4. Results




Fig. 1:

X-AXIS- time interval; Y-AXIS- percentage of tubules occluded

On day 0 – baseline all dentinal tubules were open.

Day 15, 20% tubules showed occlusion upto score 3, 50% scored 4 and 30% scored 5.

On Day 30, 20% tubules scored 7 and 8 on occlusion, 50% scored 9 and 10% scored 10.

On day 45, 100% tubules scored 10 with regard to their occlusion.

45th day all the tubular occlusion was found to be complete.

About 80% of occlusion is achieved by 15 to 30 days.

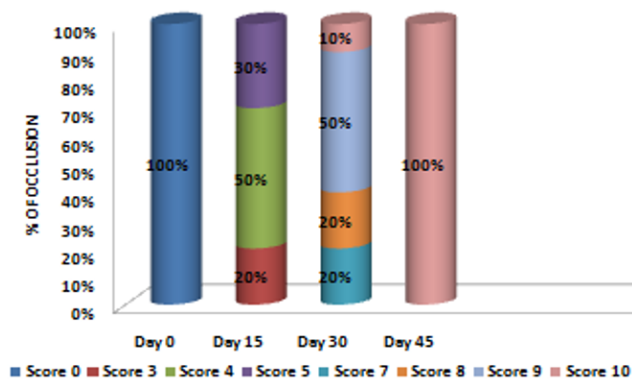


Fig. 2:

5. Discussion

The herbal toothpaste showed tubule occlusion when day 15 analysis was done in comparison to the day 0 SEM microscopy. The occluding effect of this tooth paste is attributed to the presence of Palakya (*Spinacia Oleracea*).

It consisted of 1% *Spinacia oleracea* per gram of dentifrice. It has been found that soluble oxalates and oxalic acid in phytocomplexes present in *Spinacia oleracea* (spinach leaves) form calcium oxalate crystals by reacting with dentinal calcium (Sauro et al., 2006).⁹ The ratios of calcium and oxalate/calcium determine the effect of phytocomplexes on dentinal tubule occlusion. Low amounts of calcium and excess oxalate (oxalate/calcium ratio >1) induce binding of oxalate to calcium, producing calcium oxalate directly inside dentinal tubules (Pashley, 1988).¹⁰ Oxalate crystals are small enough to reach within the tubules and occlude tubular orifices. A study has shown that treatment with oxalate-containing phytocomplexes induce microcrystal deposition on dentine and inside dentinal tubules and thus reduce the tubular diameters by forming crystals or crystal like structures (Sauro, 2006).⁹

In this formulation *Spinacia oleracea*, is the possible mechanism of having a synergistic effect along with licorice, arnica and rhubarb in reducing DH by its dentinal tubule obliterating property.

6. Conclusion

Recently there has been a growing interest in natural products. Herbal based toothpastes have been found as effective as the conventionally formulated dentifrice in the control of plaque and gingivitis. Herbal formulations have also been found to be effective in the prevention of dental caries. From the results of this study, it can be concluded

that herbal formulations are also effective in the treatment of dentine hypersensitivity and this novel herbal dentifrice can be recommended for treatment of DH.

7. Source of Funding

Purexa Global Pvt Ltd.

8. Conflict of Interest

None.

References

- Cunha-Cruz J, Stout JR, Heaton LJ, and JCW. Dentin Hypersensitivity and Oxalates. *J Dent Res*. 2011;90(3):304–10.
- Jacobsen PL, Bruce G. Clinical Dentin Hypersensitivity: Understanding the Causes and Prescribing a Treatment. *J Contemp Dent Pract*. 2001;2:27–34.
- Joshi S, Gowda AS, Joshi C. Comparative evaluation of NovaMin desensitizer and Gluma desensitizer on dentinal tubule occlusion: a scanning electron microscopic study. *J Periodontal Implant Sci*. 2013;43(6):269–75.
- Pillai VP, Neelakantan P. Desensitizing toothpastes for treatment of dentin hypersensitivity. *Int J Pharm Tech Res*. 2013;5(4):1769–73.
- Kumari M, Naik SB, Rao NS, Martande SS, Pradeep AR. Clinical efficacy of a herbal dentifrice on dentinal hypersensitivity: a randomized controlled clinical trial. *Aust Dent J*. 2013;58(4):483–90.
- Markowitz K. The original desensitizers: Strontium and potassium salts. *J Clin Dent*. 2009;20:145–51.
- Markowitz K, Kim S. The role of selected cations in the desensitization of intradental nerves. *Proc Finn Dent Soc*. 1992;88(1):39–54.
- Pathan AB, Bolla N, Kavuri SR, Sunil CR, Damaraju B, Pattan SK. Ability of three desensitizing agents in dentinal tubule obliteration and durability: An in vitro study. *J Conserv Dent*. 2016;19(1):31.
- Sauro S, Gandolfi MG, Prati C, Mongiorgi R. Oxalate-containing phytocomplexes as dentine desensitizers: An in vitro study. *Arch Oral Biol*. 2006;51(8):655–64.
- Pashley DH, Tao L, Boyd L, King GE, Horner JA. Scanning electron microscopy of the substructure of smear layers in human dentine. *Arch Oral Biol*. 1988;33(4):265–70.

Author biography

Jasjit Kaur Manager- Clinical Research and Product Development

Rahul Paul Professor and HOD

Kirti Rathee Senior Lecturer

Geetika Arora Associate Professor

Cite this article: Kaur J, Paul R, Rathee K, Arora G. Dentinal tubule occluding effect of a herbal tooth paste – An invitro scanning electron microscopy analysis. *Int J Oral Health Dent* 2020;6(2):107-109.