

Molar Intrusion with Asymmetrical M-TPA

Riddhi^{1*}, Sangeeta Prasad²

¹Post Graduate Student, ²Associate Professor, Department of Orthodontics and Dentofacial Orthopaedics, A.E.C.S Maaruti College of Dental Sciences and Research Centre, Bangalore - 560076

***Corresponding Author:**

E-mail: redhuriddhi11@gmail.com

ABSTRACT

Introduction: In Orthodontics over-eruption of maxillary molar is a common clinical finding which occurs due to the long-term absence of occlusal contact with its opposing antagonist. Intrusion of single over-erupted molar is a challenge for the orthodontists. Among the various procedures described in literature, mini-screws and TADs are popular. Also modified TPA engaging elastics in distal hooks has been described. However it needs patient compliance.

Methodology: In this case-report, the authors have used a simple modification of TPA. The M-TPA was made with 0.8 mm stainless steel wire with asymmetrical, unequal arms. The shorter arm was engaged to the palatal sheath of the molar to be intruded, so that the appliance lies at 4 mm from palate.

Result & Conclusion: The intrusion was achieved within 3 months. The method is easy, simple, non-invasive with reduced chair-side time and cost-effective.

Key words: Over-erupted Molar, Molar Intrusion, Asymmetrical M-TPA, Tongue forces

Access this article online	
Quick Response Code:	Website: www.innovativepublication.com
	DOI: 10.5958/2395-499X.2015.00009.X

INTRODUCTION

In Orthodontics over-eruption of maxillary molar is a common clinical finding, which occurs due to the long-term absence of occlusal contact with its opposing antagonist. Over-eruption is believed to be related to impaired masticatory function, occlusal interference, loss of periodontal bony support and subsequently development of Temporomandibular disorders (TMDs).¹ Also it leaves inadequate room to restore the mandibular edentulous space, thus making prosthodontic rehabilitation difficult.

Conventional approaches for removing such interference include equilibrating the occlusal surface of molar crown, which is method of choice in cases with mild extrusion. However, most cases often require intentional endodontic therapy, thus making the longevity of the tooth questionable. Other alternatives include surgical techniques like alveolar corticotomy² or posterior subapical osteotomy.³ With surgical impaction crown height can be reduced immediately, but it involves patient discomfort and risks of surgery.⁴ Orthodontic intrusion seemed to be unsuccessful until the development of skeletal anchorage system. Skeletal anchorage, including dental implants⁶, surgical miniplates⁷ and miniscrews⁸, became famous because of its ability to provide absolute anchorage. Anchorage

from the anterior palate has also been advocated to provide more stable results⁹. In some of these studies, elastomeric materials were used¹⁰ along with modified TPA for delivering intrusion forces, which may have several shortcomings like rapid force degradation, hygiene problems, and need for patient cooperation.⁵ This article presents a simplified chair-side modification of TPA with asymmetrical arms. Not only is it an easy and quick method, also it requires no patient compliance.

Appliance Design

The M-TPA was made with 0.8 mm stainless steel wire with asymmetrical, unequal arms (**Figure 1**). The shorter arm was engaged to the palatal sheath of the molar to be intruded, so that the appliance lies at 4 mm from palate. The intrusion is achieved within 3 months. The method is easy, simple, non-invasive with reduced chair-side time and cost-effective.

CASE REPORT

A 17 year old male patient reported with a chief complaint of forwardly placed upper front teeth and grossly decayed lower posterior teeth. On examination he was found to have right lower root stumps due to which the opposing tooth upper right 1st molar has extruded by 3 mm. (**Fig -2,3,4**). The sagittal skeletal relationship was found to be a mild to moderate skeletal class II with hypodivergent jaw bases with convex profile. The treatment plan for extruded upper molar involved extraction of root stumps, intrusion followed by prosthetic restoration of mandibular space.

Appliance -

Modified TPA was fabricated on the working model of the patient with 0.8mm stainless steel wire. The two

arms were made of unequal lengths, (Fig-1) the arm was made 3 mm shorter on the side of extruded molar while the other arm was of length to fit passively into the lingual sheath.

Upper molars were banded with soldered lingual sheaths. Fixed mechanotherapy with PEA appliance was started simultaneously to meet patient's chief complaint.

The asymmetrical M-TPA was inserted (Fig-5). It was activated when the shorter arm was forcefully engaged in the lingual sheath of extruded molar in such a manner that TPA lies 4 mm away from the palate. It was tied securely to sheaths with ligature wire.

The patient was seen at his usual appointments of 4 weeks. The M-TPA remained in patient's mouth and wires were changed for initial levelling and aligning from 0.16 NiTi to .017 x.0 25" NiTi.

RESULT

Significant intrusion of molar was noticed after 3 months. (Fig- 6,7). Post-intrusion OPG did not show any root resorption (Fig 8). Regional superimpositions of pre- and post-intrusion lateral cephalograms showed 3 mm of bodily intrusion achieved (Fig 9). The appliance was left in place for retention.



Fig 1: Asymmetrical TPA

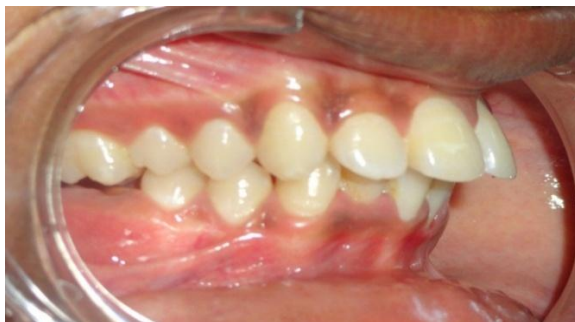

Fig. 2: Extruded upper right first molar with root stumps in antagonist tooth area.

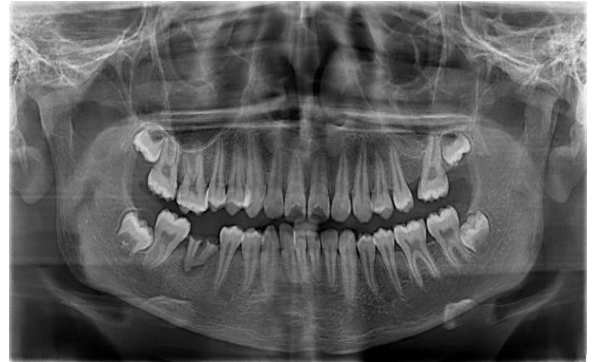

Fig. 3: Pre-Treatment OPG showing 3 mm of Over-extrusion of upper right 1st Molar

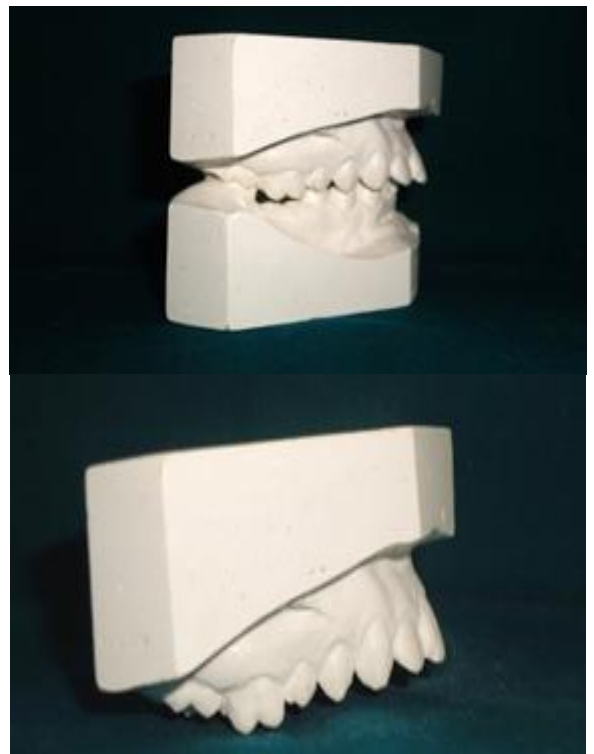


Fig. 4: Pre-treatment Study Models

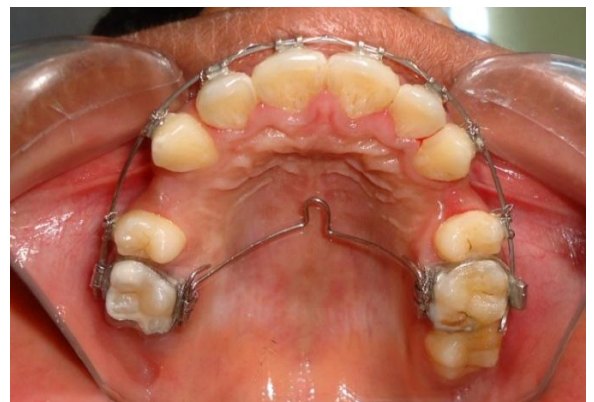

Fig. 5: Appliance Insertion. TPA must be atleast 4 mm away from palate to utilise intrusive forces from constant tongue pressure.

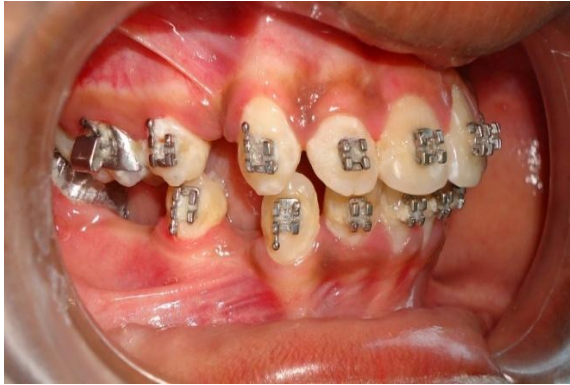

Fig. 6: Intrusion achieved in 3 months

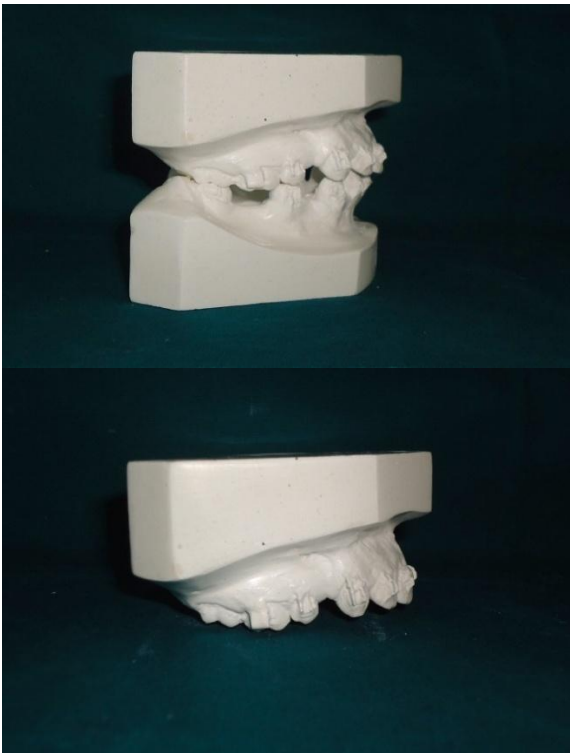


Fig. 7: Post-intrusion Models

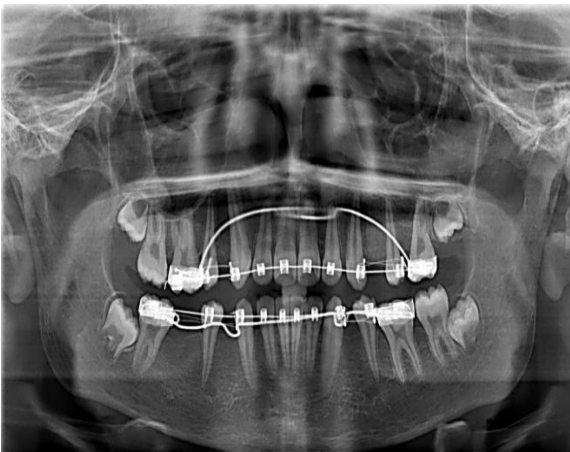

Fig. 8: Post-Intrusion OPG

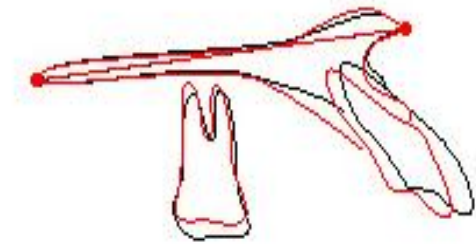


Fig. 9: Lateral Ceph Superimposition: Pre- (BLACK) and Post-intrusion (RED)

DISCUSSION

Intrusion is described as an apical movement in the direction of its long axis into the alveolus in the same direction that forces are imposed by physiologic occlusion.¹¹ The periodontal ligament system is most resistant to orthodontic forces applied in vertical direction towards the apex of the root due to the unique combination of simultaneous hydraulic pressure and fibrous tension applied to the periodontal ligaments. Very light continuously applied forces are most effective.¹¹ M-TPA used here applies light continuous intrusive forces. It was supported buccally by arch-wire. Occlusal pressure was applied constantly by tongue-pressure. As MTPA was placed 4 mm away from palate upon activation, the tongue forces are responsible for the light continuous forces causing molar intrusion, and also the side-effects of extrusion of anchor unit is nullified.

CONCLUSION

Asymmetrical TPA offers a simplified approach for mild molar intrusion in clinical practice. It needs minimal patient compliance, with reduced chair-side time and also non-invasive and cost-effective as compared to mini-screw and TADs.

REFERENCES

1. Lyka I, Carlsson GE, Wedel A et al: Dentists' perception of risks for molars without antagonists. A questionnaire study of dentists in Sweden, Swed. Dent. J. 25:67-73, 2001.
2. Hwang, H.S. and Lee, K.H.: Intrusion of overerupted molars by corticotomy and magnets, Am. J. Ortho. Dentofacial. Orthop.120:209-216, 2001.
3. Schoeman R, Subramanian L: The use of orthognathic surgery to facilitate implant placement: a case report, Int. J. Oral Maxillofac. Implants. 11:682-4, 1996.
4. James C.Y. Lin, Eric J.W. Liou, Chin-Liang Yeh: Intrusion of overerupted maxillary molars with miniscrew anchorage, J. Clin. Orthod. 6:378-383, 2006.
5. Farzin Heravi, Shahin Bayani, Azam S et al: Intrusion of supra-erupted molars using miniscrews: Clinical success and root resorption, Am J. Orthod. Dentofacial. Orthop.139:S170-175, 2011.
6. Shapiro PA, Kokich VG: Uses of implants in orthodontics, Dent. Clin. North Am. 32:539-50, 1988.

7. Sherwood KH, Burch JG, Thompson WJ: Closing anterior open by intruding molars by titanium miniplate anchorage, *Am J. Orthod. Dentofacial. Orthop.* 122:593-600, 2002.
8. Park YC, Lee SY, Kim DH et al: Intrusion of posterior teeth using mini-screw implants. *Am J. Orthod. Dentofacial Orthop.* 123:690-4, 2003.
9. Benedict Wilmes, Manuel Nienkemper, Björn Ludwig, Ravindra Nanda, Dieter Drescher: Upper-molar intrusion using anterior palatal anchorage and the mousetrap appliance, *J. Clin. Orthod.* 27:314-320, 2013.
10. Neal D. Kravitz, Budi Kusnoto, Peter T. Tsay et al: Intrusion of overerupted upper first molar using two orthodontic miniscrews - a case report, *Angle Orthod.* 77,5:915-922, 2007.
11. Julia Elodie Vlachojannis and Margherita Santoro: A novel treatment approach for extruded maxillary molars, *J. Int. Dent. Med. Res.* 4:77-86, 2011.