

## Liver clot- A rare post-operative complication following tooth extraction

Prasanna Kumar D<sup>1</sup>, Meghashri Kabbinahalli<sup>2</sup>, H K Ajeya Ranganathan<sup>3\*</sup>, Madhuri G Palekar<sup>4</sup>

<sup>1</sup>Professor, <sup>2</sup>Reader, <sup>3,4</sup>PG Resident, <sup>1,3,4</sup>Dept. of Oral and Maxillofacial Surgery, <sup>2</sup>Dept. of Prosthodontics and Implantology, K V G Dental College and Hospital, Sullia, Karnataka, India

**\*Corresponding Author: H K Ajeya Ranganathan**

Email: sreeranga1993@gmail.com

### Abstract

Post-operative bleeding is a common post extraction complication usually associated with both intra-alveolar and trans-alveolar extractions. The bleeding is mostly due to venous bleed are usually managed by pressure pack or sutures. Occasionally the clot will increase in size and may extend upto the size of few centimetres which are known as "Liver-clot" due to its similarity with liver tissues in appearance. This event may occur peri-operatively or post-operatively or may occur as delayed response upto 72 hours post-operatively. The dimensions of the clots are dictated by the amount of exposure of blood stream to tissue factors that are present perivascularly. We are reporting a series of cases that developed liver-clot post operatively and have discussed the possible mechanism of clot growth and its spatiotemporal dynamics of the clot in response to tissue factors

**Keywords:** Liver clot, Tissue factors, Venous haemorrhage, Spatiotemporal dynamics.

### Key Messages

Most of the dental procedures are usually associated with intra-operative and post-operative bleeding and each case could potentially turn out to be a case of reactionary haemorrhage. The key to manage such situation is to know the physiology of clotting and prompt application of local haemostatic measures to control bleeding.

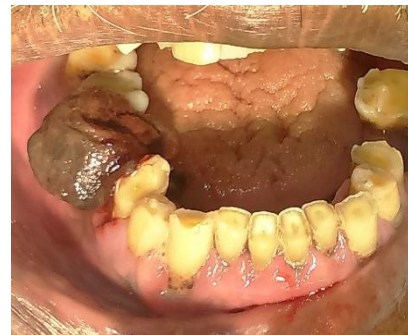### Introduction

Dental extractions are the most common oral surgical procedures that are mostly associated with post-operative bleeding which ranges from minor ooze to complete exsanguination.<sup>1</sup> The reason for increased bleeding from oral wounds may be attributed to the extensive vasculature and constant disturbance of the wound left to heal secondarily.<sup>2</sup> A bright red jelly-like clot occurs over operated/ extracted site known as "liver clot". This is a series of cases of liver clot formation following extraction and influence of tissue factors in the formation along with spatiotemporal dynamics is discussed.

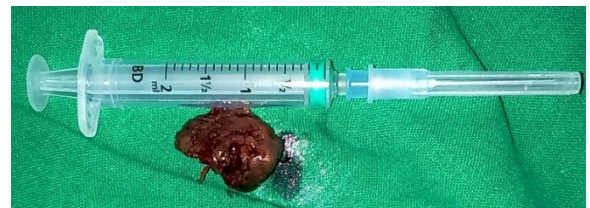### Case Report

#### Case 1

A 65-year-old male patient reported to the department of oral and maxillofacial surgery three days following extraction of mandibular right first molar with the complaint of mass projecting out of the extracted socket and difficulty in chewing food and often bleeding. On inspection, light brown coloured mass measuring about 1.5x1.5cms [Fig. 1.1 and 1.2] and soft in consistency, pedunculated to the extraction socket and non-tender on palpation.



**Fig. 1.1:** Liver clot in the region of 46

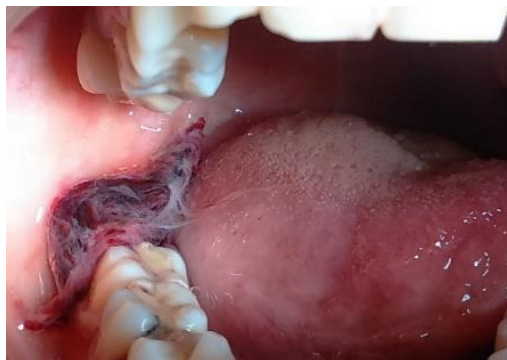

**Fig. 1.2:** Liver clot measuring about 1.5x1.5cms

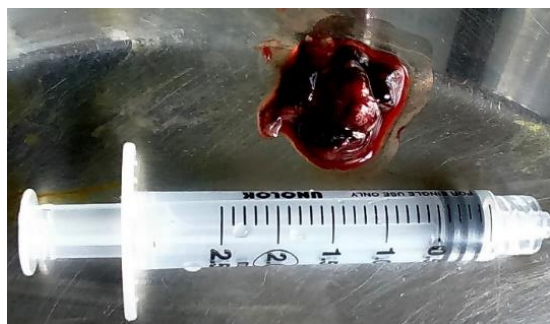#### Case 2

A male patient aged about 22 years reported to our department with a chief complaint of bleeding during mastication since one day. Patient's dental history revealed and uneventful extraction of grossly decayed mandibular right third molar tooth under local anesthesia. The procedure was uneventful and immediate post-operatively, the patient was asymptomatic. However bleeding was noticed 12 hours past extraction which aggravated on mastication.

On inspection, the blood clot was extending over the socket and over the second molar tooth measuring about 1.5x1.5cms [Fig. 2.1 and 2.2] Dark red in colour and soft in consistency and bleeding was noted on palpation and was not pulsatile confirming that the haemorrhage was due to venous bleed.



**Fig. 2.1:** Liver clot in relation to 48

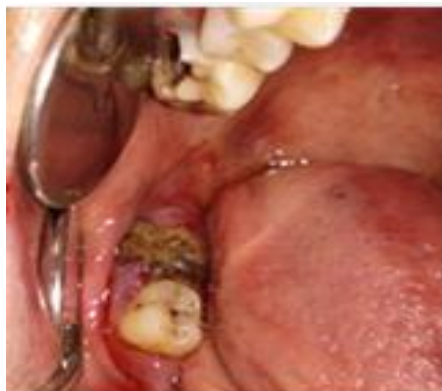

**Fig. 2.2:** Liver clot removed measuring about 1.5 x 1.5cms

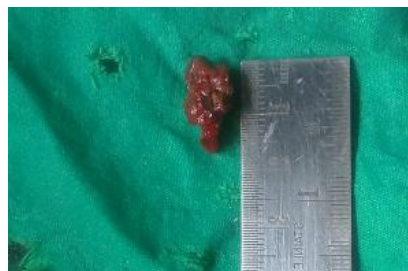**Case 3**

A 45 year old female patient reported to the dental clinic with complaint of decayed lower third molar and was explained the treatment plan and atraumatic extraction of lower right third molar was done on the same day following injection of local anesthetic 2% lignocaine with 1:80,000 adrenaline [LIGNOX 2%A]. The next day, patient reported with the complaint of bleeding during mastication.

The clot was dark red in colour measuring about 1.5x1.5 cms [Fig 3.1 and 3.2], extending upto the occlusal aspect of the second molar tooth from the extraction socket on inspection. Palpation revealed soft consistency of the clot with bleeding on palpation, non-tender and pedunculated to the socket.



**Fig. 3.1:** Liver clot in relation to 48

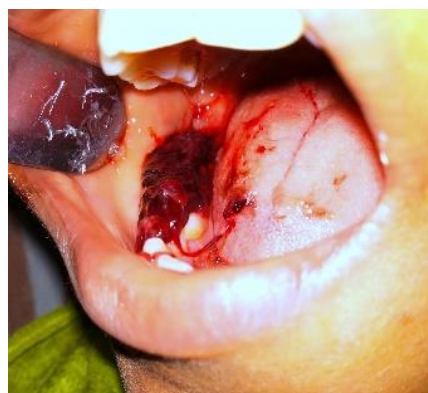

**Fig 3.2:** Liver clot measuring about 1.5x1.5cms

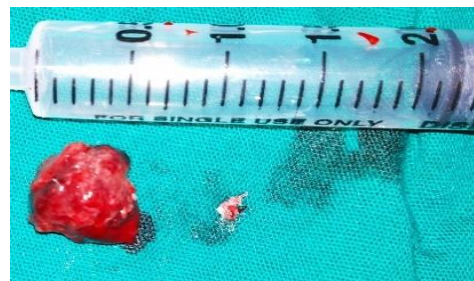
**Case 4**

A 27 year old female patient reported to the department of oral and maxillofacial surgery, on post- operative day one following the extraction of lower right third molar with the chief complaint of difficulty in mastication due to protruding mass from the extraction socket spreading out on the teeth with frequent bleeding. On inspection, dark red coloured mass suggestive of blood clot was projecting out from the extraction socket extending out over the occlusal surface of the lower right first premolar region [Fig. 4.1 and 4.2]. Patient in this case had productive cough and a portion of clot separated off from the socket before it was removed manually.

All the cases were managed with local haemostatic agent [Betroclot drops] and suturing after giving local anaesthesia. The projecting blood clot was removed. Bleeding was noted immediately after the removal of clot and it was comparatively higher in amount of bleeding when compared to normal socket. Absorbable gelatin sponge [Surgigel] was placed in the socket and fig of 8 suture [Trusilk 3.0] placed.



**Fig. 4.1:** Liver clot in the socket extending up to the occlusal surface of the premolars



**Fig. 4.2:** Liver Clot measuring about 1.0x1.0cms

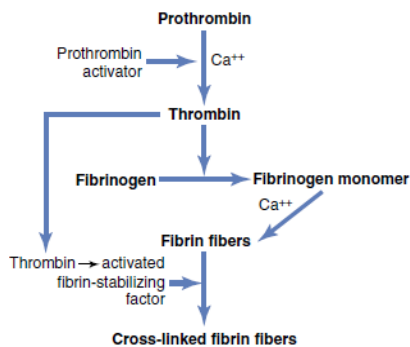
**Discussion**

Injury to wall of vasculature initiates coagulation cascade within 15 seconds to 2 minutes depending on the severity of the injury. The breach in the integrity of vessel wall will be filled up with clot within 3-6 minutes. Further the clots retract closing the vessel within 20 – 60 minutes<sup>3</sup>.

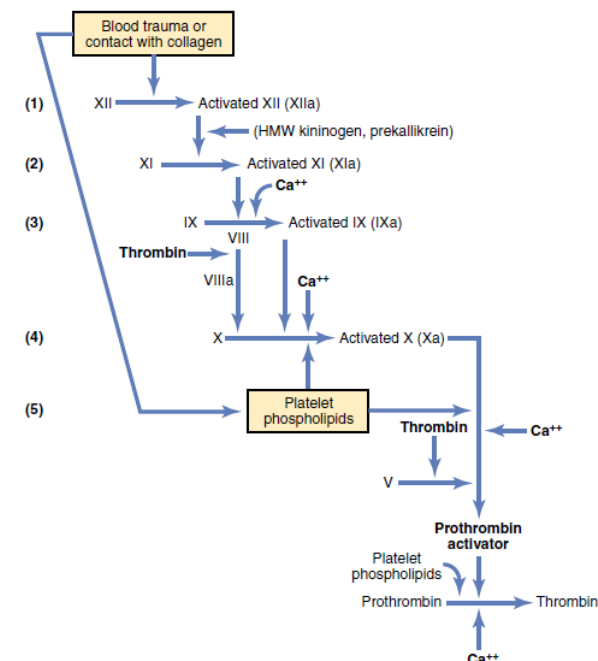
Stages of coagulation [Chart 1].

1. Conversion of Prothrombin to thrombin which occurs in two pathways, Extrinsic [Chart 1.1] and Intrinsic pathways [Chart 1.2]
2. Conversion of Fibrinogen to Fibrin by Thrombin.
3. Enmeshment of platelets, RBC's and plasma by Fibrin fibres to form the clot.

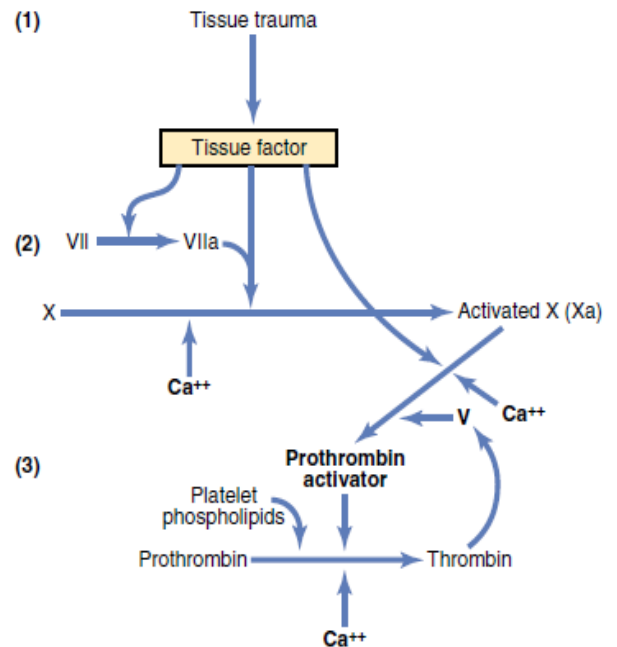
Hemorrhage in its simplest definition refers to the escape of blood from blood vessels.<sup>2</sup> The character of hemorrhage will depend on the type of vessels severed - arteries, veins, or capillaries. *Arterial hemorrhage* will be distinguished by its pulsating character, vigor of the flow, and bright red coloration of the blood. *Venous hemorrhage* is characterized by less rapid, non-pulsatile and darker hue.<sup>4</sup>



**Chart 1:** Schematic flow chart of clot formation



**Chart 1.1:** Extrinsic pathway for initiation of blood clot



**Chart 1.2:** Intrinsic pathway for initiation of blood clot

Hall, J. and Guyton, A. (2011). *Guyton and Hall textbook of medical physiology*. 12th ed. Copyright © 2011 Saunders. An Imprint of Elsevier, INC, all rights reserved.

Due to the connections between terminal branches of veins and jugular systems, the venous bleeding will be more profuse whenever there is any injury to the veins of the Oral and maxillofacial region. Capillary bleed which is responsible for the ooze of blood post operatively in maxillofacial region is more aggressive due to strong arterial pulse on one side of the capillaries and the open, direct, non-valved access to the jugular system on the venous side which would result in a massive liver clot or as just blood tinged saliva which would attract patient's concern.<sup>5</sup>

LIVER CLOT or "CURRANT JELLY CLOT" is defined as a red, jellylike clot that is rich in hemoglobin from erythrocytes within the clot. The possible mechanism for the formation of the liver clot can be due to the venous haemorrhage which is non pulsatile and dark-red in colour.

Tissue factor (TF) is a transmembrane protein that serves as the primary initiator of physiological hemostasis with no enzymatic activity of its own, it binds coagulation factor VII (FVII), promotes its activation, and greatly enhances the proteolytic activity of Factor VIIa (FVIIa).

Exposure of the Sub Endothelial matrix also triggers coagulation wherein enzymatic reaction initiates on exposure of the sub endothelial matrix on the activated platelet surface resulting in the formation of thrombin that polymerizes the fibrin monomers to form fibrous gel stabilizing the clot.

Initiation of venous thrombosis is unclear and may involve the stasis of deoxygenated blood or slow flow of the blood which may result in tissue hypoxia. The clot contains mainly of trapped RBC's, fibrin and some platelets and such

clot may grow at a variable rate ranging upto few centimetres.<sup>6</sup>

TF is not expressed equally by all tissues. Many sites have very low levels of expression, such as most fibroblasts and skeletal muscle. Highest expression levels are seen in the brain, lung, and the epithelial cells of the skin, mucosa, around the blood vessels and glomeruli.<sup>7</sup>

TF expression can be transiently up-regulated in monocytes or macrophages and endothelial cells by a variety of inflammatory mediators. However, cells in contact with the blood do not express TF under normal physiological conditions.<sup>7</sup> The extent of exposure of Tissue factors and collagen to the blood would decide the spatiotemporal dynamics of the clot morphology. The size of clot is directly related to the length of exposure of the tissue factors.<sup>5</sup>

Liver clot is usually removed with high volume evacuation or curetted out with large curette following which firm pressure is applied over the region. Occasionally suture might be needed.<sup>1</sup>

Postoperatively, the operated site should be curetted and cleared to visualize the source of bleeding and if the source

is arterial, the bleeder should be cauterised or ligated. Non arterial bleeding can be managed with procoagulants, absorbable gel sponges and sutures.<sup>8</sup>

Intraoral bleeding can be controlled by application of local styptics [Table 2] such as botroclot solution, Russell Snake venom or Tranexamic acid would control the bleeding from the socket, however while applying the vasoconstrictors such as epinephrine over the bleeding socket, the reverse vasodilatation should be considered owing to the activity of  $\beta$ -adrenergic receptors.<sup>9</sup>

In patients with bleeding disorders certain investigation related to the bleeding should be assessed such as PTT for intrinsic pathway, PT for both pathways and BT for platelet and vascular assessment.<sup>1</sup> In patients with such bleeding disorders or any deficiencies in the components constituting the coagulation pathways should be supplemented through extrinsic source to correct the deficiency before procedure. In all the cases that we presented here, none of the patient had any bleeding disorders.

**Table 2:** Local Hemostatic agents for the management of oral bleeding

Name	Source	Action	Application
Gelfoam (Pharmacia, Mississauga, Ont.)	Absorbable gelatin sponge (methylcellulose)	Scaffold for blood clot formation	Place into socket and retain in place with suture
Surgicel (Johnson & Johnson, Guelph, Ont.)	Oxidized regenerated methylcellulose	Binds platelets and chemically precipitates fibrin through low pH	Place into socket (Note: cannot be mixed with thrombin)
CollaTape (Sulzer Dental, Carlsbad, Calif.)	Highly cross-linked collagen	Stimulates platelet adherence and stabilizes clot; dissolves in 4-6 weeks	Pack ribbon into socket; easier to use than Gelfoam
CollaPlug (Sulzer Dental) Carlsbad, Calif.)	Preshaped, highly cross-linked collagen plugs	Stimulates platelet adherence and stabilizes clot; dissolves in 4-6 weeks	Place into socket
Avitene (Davol, Cranston, Rhode Island)	Microfibrillar collagen	Stimulates platelet adherence and stabilizes clot; dissolves in 4-6 weeks	Mix fine powder with saline to desired consistency
Thrombin (Thrombostat [Pfizer, Toronto, Ont.])	Bovine thrombin (5,000 or 10,000 units)	Causes cleavage of fibrinogen to fibrin and positive feedback to coagulation cascade	Mix fine powder with CaCl <sub>2</sub> and spray into area; alternatively, mix with Gelfoam before application
Glynns Glue (Toronto General Hospital Dental Formulary)	Thrombin, Gelfoam, CaCl <sub>2</sub> and sucralfate	Combination of Gelfoam and Thrombin plus sucralfate's adherent properties	Mix and pack into socket; suture in place
Tissee (Baxter, Mississauga, Ont.)	Bovine thrombin, human fibrin, CaCl <sub>2</sub> and aprotinin	Antifibrinolytic action of aprotinin	Requires specialized heating, mixing and delivery system; inject into socket

Credits: Hassan et al. Life-Threatening Hemorrhage after Extraction of Third Molars: Case Report and Management Protocol

## Conclusion

Dental extractions and periodontal surgical procedures which are proved to be safe procedure might end up with complications in life threatening complication related to bleeding at times due to the underlying bleeding disorders. Besides having thorough knowledge of surgical anatomy and awareness post-surgical complications, thorough planning and careful surgical techniques should be considered.

Dental surgeons play a vital role in recognizing such the bleeding disorders at the earliest and prompt addressing of the underlying defect will help the patient.

## Source of Funding

None.

## Conflict of Interest

None.

## References

1. Richard F. Post-surgical hemorrhage: Formation of a "liver clot" secondary to periodontal plastic surgery. *J Contemp Dent Pract.* 2001;2;1-6.
2. Peterson L. Contemporary oral and maxillofacial surgery. 4th

- ed. St. Louis, Mo.: Mosby, 2007.
3. Hall J, Guyton A. Guyton and Hall textbook of medical physiology. 12th ed. Philadelphia: Elsevier Saunders; 2011.
4. Kruger G, Alling III C. Textbook of oral and maxillofacial surgery. 5th ed. Saint-Louis: Mosby; 1979.
5. Hoffman M. The tissue factor pathway and wound healing. *Semin Thromb Hemost.* 2018;44(2):142-50.
6. Fogelson AL, Neeves KB. Fluid Mechanics of Blood Clot Formation. *Annu Rev Fluid Mech.* 2015;47:377-403.
7. Govindarajan V, Zhu S, Li R, Lu Y, Diamond SL, Reifman J, Mitrophanov AY. Impact of tissue factor localization on blood clot structure and resistance under venous shear. *Biophys J.* 2018;114(4):978-91.
8. Moghadam HG, Caminiti MF. Life-Threatening hemorrhage after extraction of third molars: Case report and management protocol. *J Can Dent Assoc.* 2002;68(11):670-4.
9. Fonseca RJ. Aneesthesia/ dentoalveolar surgery/ office management. 1st ed, Philadelphia: Publication House-Saunders; 2000.

**How to cite this article:** Kumar PD, Kabbinahalli M, Ranganathan HKA, Palekar MG. Liver clot- A rare post-operative complication following tooth extraction. *Int J Oral Health Dent* 2020;6(1):58-62.