

Review on biodentine: A boon to pediatric dentistry

Deepashree Rajendraprasad

Private Dental Practitioner, Shri Gayathri Dental Clinic, India

***Corresponding Author: Deepashree Rajendraprasad**

Email: deepashree161094@gmail.com

Abstract

Biodentine™, a new bioactive cement soon after its launch has drawn attention of all dental practitioners across the world for its superior characteristics. It is widely recommended for its wide spectrum of clinical applications in Pediatric dentistry. This literature review systematically summarizes the availability, composition, properties of biodentine. In nut shell, biodentine is able to function as a reliable alternative and comprises of a much brighter future outlook compared to the conventional cements which are being employed commonly.

Keywords: Biodentine™, Characteristics, Pediatric dentistry, Composition, Properties.

Introduction

From bygone days, Calcium hydroxide was the most preferred material for preserving the pulp vitality but due to its drawbacks like mild antibacterial properties, poor cohesive strength, greater solubility, and marginal leakage.¹ MTA was introduced in 1990. MTA was considered as a “GOLD STANDARD” material for defects related to dentin due to its excellent properties. But there existed shortcomings even with MTA such as not being cost effective, long setting time,^{1,2} difficult handling properties³ and its inherent tendency to undergo discolouration⁴ which led to the pathway for the creation of a new calcium silicate based biomaterial called as ‘BIODENTINE’, introduced by Septodont’s research group [Saint Maur des Forces, France].⁵ It exhibited the identical excellent biocompatibility like that of MTA which can be placed in direct contact with the pulpal tissue,⁶ high mechanical properties and good sealing ability with dentine.⁷ As it fulfilled all the physiognomies of an ideal restorative material such as having good physical and mechanical properties, technical features of the material from the perspective of the dental professional, acceptability of the material by the patients, and other clinical features that lead to the material’s effectiveness, it was rightly called as ‘Bioactive Dentine Substitute’⁸ ‘Dentine In Capsule’.⁹ Soon after its unveiling, its applications are greatly utilized in the department of Pedodontics, Operative dentistry, Endodontics, and also in Periodontics.

Availability

It is existing in the market in the form of capsules containing powder and as pipettes filled with the liquid.⁹

Composition:⁸⁻¹¹

Powder	Liquid
-Tricalcium silicate- Main core material	-Calcium chloride: Accelerator
-Dicalcium silicate- Second core material	-Hydrosoluble polymer – Water reducing agent
-Calcium carbonate and oxide – Filler	/super –plasticizing agent.
-Iron oxide- Colouring agent	
-Zirconium oxide – Radio –opacifier	

Manipulation

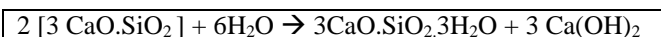
Working time- Upto 6 minutes.⁵

Final setting time – 10 to 12 minutes.⁵

Biodentine can be manipulated by two methods namely the mechanical and the manual method. In mechanical method, both powder and liquid are added and mixed together for 30 seconds in a triturator. In manual method, a mixing pad is taken and both liquid and powder are blend well with spatula for about 30 -45 seconds.⁵

Setting Reaction

When liquid and powder is mixed together, chemical reaction begins where calcium silicate and water reacts thus resulting in hardening of the cement. Therefore, final products of this process are hydrated calcium silicate gel [CSH gel] [CSH= 3CaO.2SiO₂.3H₂O] and calcium hydroxide [Ca(OH)₂].⁷



Properties

Compressive Strength

Grech et al conducted a study which calculated the compressive strength of biodentine in Hank’s balanced salt solution to be 67.18 Mpa when immersed which was relatively much more higher than MTA which has 40 Mpa.⁷

Elastic Modulus

Biodentine has 22.0 Mpa very similar to dentine which has 18.5.²⁵

Microhardness

It is a very important property which determines whether the dental material is very hard or brittle for clinical application. The Vickers mean microhardness value was 62.35 [+/- 11.55] HV which is 2.5 times higher than the ProRoot MTA.¹⁷

Flexural Strength

This property is essential in order to estimate whether the material is capable of withstanding high stress or pressure. When compared to dentine which has a flexural strength of 20 Mpa, biodentine is known to have 34 Mpa which was estimated using three point bending test after 2 hours.⁷

Radio Opacity

Biodentine has a radio opacity of 1.50 (+/- 0.10) mm Aluminium due to opacifier.¹⁷ EE

Porosity and Density

Biodentine exhibited lower porosity compared to ProRootMTA, thereby had higher mechanical strength.⁷

Anti- bacterial Activity

MM Zayed et al conducted a study in which the anti bacterial property of dental cements were estimated by the growth of colonies of Streptococcus mutans, where largest zone of inhibition was exhibited by Biodentine.¹⁹ Another study conducted by Nikhil et al showed the biodentine's anti-bacterial activity after addition of 10% doxycycline or 2% Chlorhexidine which was found to be deadly against Enterococcus faecalis and Candida albicans.²⁰

Push-out Bond Strength

After setting time of 24 hours, Biodentine showed a markedly higher push –out bond strength than MTA.²¹

Solubility

Biodentine showed lower solubility compared to MTA since the release of the calcium ions from MTA accelerated its solubility to a greater extent.¹⁷

Inherent Potential to Undergo Discolouration

A study conducted by Camilleri et al found that biodentine do not undergo discolouration when compared to Neo MTA plus, MTA Plus.²²⁻²³ It shows stability of colour and can be used as a substitute for composite restorations in highly esthetic areas as well.

Durability as an Interim Posterior Restoration

A Prospective study conducted by Koub et al which analyzed the performance of posterior teeth with biodentine as an interim material and it was found to be durable upto 6 months.²⁴

Setting Time

Biodentine has comparatively short setting time of about 10-12 minutes to MTA, which makes it highly preferable for immediate crown restoration in Pediatric Dentistry.¹²

Marginal Adaptation and Sealing Ability

Biodentine after placement enters the pores which is caused by dissolution of organic tissue in dentinal tubules thus establishing micro mechanical bond and providing excellent anti- bacterial seal.¹⁶

Biocompatibility

Biodentine exhibits excellent property of biocompatibility to other materials.¹⁶

Applications in Pediatric Dentistry

The most unique property of biodentine is that of its importance in both crown and root portion of the tooth. In the crown portion, it is used for pulp capping, pulpotomy, deep cavity treatment involving sandwich technique, temporary restoration and as a dentine substitute.^{12,22,29,30-32} In root, biodentine has been indicated in root canal or furcation perforation, cervical root resorption, apexification, retrograde root end filling and also in implant stabilization as a bone substitute material.³³⁻³⁶ Due to all these vital properties, biodentine finds application in many clinical procedures.

Dentine Substitute

There was a strong evidence that no post-operative complications were established when biodentine was used as an alternative in class 1 and 2 composite restorations.³⁵ Even a clinical study with a 6 month follow-up showed a very strong marginal adaptation and superior surface finish with absence of pain and sensitivity on usage of biodentine.²⁹

These results indicated that biodentine could be used as a dentinal substitute under composite restoration for posterior teeth. A study by Valles Et al suggested that biodentine showed colour stability and results proved that biodentine could be a substitute for light cured restorative materials in esthetically sensitive areas.³⁶ Since biodentine had all the mechanical properties similar to dentine in tooth, it can be used as an ideal dentine substitute material.¹⁰

Pulp Capping

Biodentine is recommended as an effective medicament for pulp capping procedure,⁹ as it has the unique feature in dentine bridge formation and tissue reaction.^{9,10,37} Moreover, it has the ability to begin early mineralization from pulpal cells by releasing TGF- BETA, thereby encouraging pulp healing.⁹

Study conducted by Nowicka et al, with biodentine used as pulp capping material found that it exhibited dentine bridge formation without any inflammatory response.³⁹ Thus, once again proving to be good pulp capping agent.

Pulpotomy

In Pediatric dentistry, when the inflammation is in coronal pulp and also when direct pulp capping is not a recommended treatment option, pulpotomy is the most commonly accepted clinical procedure.⁴⁰ One of the key advantages of using biodentine in pulpotomy is that it required less time and also acts simultaneously as a filling and a dressing material.^{9,38,40}

Thereby, it was found that biodentine has the capacity of maintaining pulp vitality in patients opted for pulpotomy treatment.⁴¹ Villat et al treated second premolar teeth in a 12 year old patient with partial pulpotomy. After a 6 months follow up, they identified a homogenous dentine bridge formation and continuation of root development was witnessed which rendered the material to be far better compared to the other materials.⁴²

Apexification

A study conducted by Cauwell et al found that immature necrotic teeth after proper regenerative endodontic procedure with biodentine can still produce continued root development.⁴³ It was highly recommended due to its property to induce new cementum and periodontal ligament formation.¹⁰

Retrograde Filling Material

Pawar et al published a case report in which biodentine was used as a retrograde material for traumatized maxillary central and lateral incisors with large periapical lesion.¹⁸

After a follow-up for 18 months, it was identified that biodentine caused progression of periapical healing.⁴⁴

Repair of Resorption

In two different case reports published by Nikhil et al and Ali et al, both highlighted the unique property of biodentine in treatment of cervical and apical external root resorption cases after a time period of one year.³³⁻³⁴ However, they identified that on the re-treatment cases, there was equal difficulty in removal of biodentine.¹⁰

Repair of Perforations

Biodentine having a high push out bond strength even after being exposed to vast number of endodontic irrigants makes it obviously a preferred choice.^{9,19} Due to the presence of this excellent property in biodentine, it has become a preferred material of choice in perforation repair.⁹

Conclusion

Biodentine proves to be a most promising material of all due to its exceptional properties of being highly biocompatible, bioactive, shorter span of setting time, being versatile as well as easy of handling. Thereby, overcome the shortcomings of other material like that of MTA, calcium hydroxide and formocresol which are available commercially. Thus, biodentine proves to be a 'GOLD STANDARD' replacing all other materials for treatment of primary and permanent teeth. However, long term clinical studies and trials are required to draw further inferences regarding its scope for applications in various fields of dentistry.

Conflict of Interest: None.

References

- Torabinejad M, Hong CU, McDonald F, Ford TP. Physical and chemical properties of a new root-end filling material. *J Endod* 1995;1;21(7):349-53.
- Dammaschke T, Gerth HU, Züchner H, Schäfer E. Chemical and physical surface and bulk material characterization of white ProRoot MTA and two Portland cements. *Dent Mater* 2005;21(8):731-8.
- Johnson BR. Considerations in the selection of a root-end filling material. *Oral Surg, Oral Med, Oral Pathol, Oral Radiol, Endodontol* 1999;87(4):398-404.
- Parirokh M, Torabinejad M. Mineral trioxide aggregate: a comprehensive literature review—part III: clinical applications, drawbacks, and mechanism of action. *J Endod* 2010;36(3):400-13.
- File BS. Active biosilicate technology, septodont. Saint-Maur-des-Fossés Cedex: R&D Department. 2010.
- Laurent P, Camps J, De Méo M, Déjou J, About I. Induction of specific cell responses to a Ca₃SiO₅-based posterior restorative material. *Dent Mater* 2008;24(11):1486-94.
- Kaup M, Dammann CH, Schäfer E, Dammaschke T. Shear bond strength of Biodentine, ProRoot MTA, glass ionomer cement and composite resin on human dentine ex vivo. *Head Face Med* 2015;11(1):14.
- Han L, Okiji T. Uptake of calcium and silicon released from calcium silicate-based endodontic materials into root canal dentine. *Int Endod J* 2011;44(12):1081-7.
- Priyalakshmi S, Ranjan M. Review on Biodentine—a bioactive dentin substitute. *J Dent Med Sci* 2014;13(1):51-7.
- Arora V, Nikhil V, Sharma N, Arora P. Bioactive dentin replacement. *J Dent Med Sci* 2013;12:51-7.
- Camilleri J, Sorrentino F, Damidot D. Investigation of the hydration and bioactivity of radiopacified tricalcium silicate cement, Biodentine and MTA Angelus. *Dent Mater* 2013;29(5):580-93.
- Grech L, Mallia B, Camilleri J. Investigation of the physical properties of tricalcium silicate cement-based root-end filling materials. *Dent Mater* 2013;29(2):e20-8.
- Laurent P, Camps J, About I. Biodentine TM induces TGF-β1 release from human pulp cells and early dental pulp mineralization. *Int Endod J* 2012;45(5):439-48.
- Zanihi M, Sautier JM, Berdal A, Simon S. Biodentine induces immortalized murine pulp cell Differentiation into odontoblast-like cells and stimulates biomineralisation. *J Endod* 2012;38(9):1220-6.
- Atmeh AR, Chong EZ, Richard G, Festy F, Watson TF. Dentin-cement interfacial interaction: calcium silicates and polyalkenoates. *J Dent Res* 2012;91(5):454-9.
- Firla MT. Direct pulp capping with a bioactive dentine substitute. *Oral Health* 2012;102(5):40.
- Setbon HM, Devaux J, Iserentant A, Leloup G, Leprince JG. Influence of composition on setting kinetics of new injectable and/or fast setting tricalcium silicate cements. *Dent Mater* 2014;30(12):1291-303.
- Zayed MM, Hassan RE, Riad MI. Evaluation of the antibacterial efficacy of different bioactive lining and pulp capping agents. *Tanta Dent J* 2015;12(2):132-9.
- Aggarwal V, Singla M, Miglani S, Kohli S. Comparative evaluation of push-out bond strength of ProRoot MTA, Biodentine, and MTA Plus in furcation perforation repair. *J Conserv Dent: JCD* 2013;16(5):462.
- Nikhil V, Madan M, Agarwal C, Suri N. Effect of addition of 2% chlorhexidine or 10% doxycycline on antimicrobial activity of Biodentine. *J Conserv Dent* 2014;17:271-5.
- Vallés M, Mercadé M, Duran-Sindreu F, Bourdelande JL, Roig M. Influence of light and oxygen on the color stability of five calcium silicate-based materials. *J Endod* 2013;39(4):525-8.
- Camilleri J. Staining potential of Neo MTA Plus, MTA Plus, and Biodentine used for pulpotomy procedures. *J Endod* 2015;41(7):1139-45.
- Koubi G, Colon P, Franquin JC, Hartmann A, Richard G, Faure MO, Lambert G. Clinical evaluation of the performance and safety of a new dentine substitute, Biodentine, in the restoration of posterior teeth—a prospective study. *Clin Oral Investigations* 2013;17(1):243-9.
- Chng HK, Islam I, Yap AU, Tong YW, Koh ET. Properties of a new root-end filling material. *J Endod* 2005;31(9):665-8.
- Laurent P, Tecles O. Bioactivity of Biodentine: a Ca₃SiO₅ based dentin substitute. *J Dent Res* 2010;89(B):150.
- Reyes-Carmona JF, Felipe MS, Felipe WT. The biomineralization ability of mineral trioxide aggregate and Portland cement on dentin enhances the push-out strength. *J Endod* 2010;36(2):286-91.
- Koubi S, Tassery H, Aboudharam G, Victor JL, Koubi G. A clinical study of a new Ca₃SiO₅-based material for direct posterior fillings. *Eur Cells Mat* 2007;13(Suppl 1):18.
- Dammaschke T. A new bioactive cement for direct pulp capping. *Int Dent-Aust* 2012;7:52-8.
- Camilleri J. Investigation of Biodentine as dentine replacement material. *J Dent* 2013;41(7):600-10.
- Lavaud A, Morchid L, Thebaud N, Rouas P, Nancy J. Biodentine®, a new dentin substitute: case reports. In 11th congress of the EAPD, Strasbourg 2012.

31. Nikhil V, Arora V, Jha P, Verma M. Non surgical management of trauma induced external root resorption at two different sites in a single tooth with Biodentine: A case report. *Endodontol* 2012;24(2):150-5.
32. Ali MK, Cauwels R, Martens L. The use of Biodentine in the treatment of Invasive Cervical Resorption. A case report. In 11th congress of the EAPD, Strasbourg 2012.
33. Nayak G, Hasan MF. Biodentine-a novel dentinal substitute for single visit apexification. *Restorative dentistry & endodontics*. 2014;39(2):120-5.
34. Mandava P, Bolla N, Thumu J, Vemuri S, Chukka S. Microleakage evaluation around retrograde filling materials prepared using conventional and ultrasonic techniques. *J Clin Diagn Res JCDDR* 2015;9(2):ZC43.
35. Briso AL, Mestreneur SR, Delício G, Sundfeld RH, Bedran-Russo AK, De Alexandre RS, Ambrosano GM. Clinical assessment of postoperative sensitivity in posterior composite restorations. *Oper Dent* 2007;32(5):421-6.
36. Raskin A, Eschrich G, Dejou J, About I. In vitro microleakage of Biodentine as a dentin substitute compared to Fuji II LC in cervical lining restorations. *J Adhesive Dent* 2012;14(6):535.
37. Tran XV, Gorin C, Willig C, Baroukh B, Pellat B, Decup F, Opsahl Vital S, Chaussain C, Boukpepsi T. Effect of a calcium-silicate-based restorative cement on pulp repair. *J Dent Res* 2012;91(12):1166-71.
38. Shayegan A, Jurysta C, Atash R, Petein M, Abbeele AV. Biodentine used as a pulp-capping agent in primary pig teeth. *Pediatr Dent* 2012;34(7):202E-8E.
39. Nowicka A, Lipski M, Parafiniuk M, Sporniak-Tutak K, Lichota D, Kosierkiewicz A, Kaczmarek W, Buczkowska-Radlińska J. Response of human dental pulp capped with biodentine and mineral trioxide aggregate. *J Endod* 2013;39(6):743-7.
40. EL-Ma'aita AM, Qualtrough AJ, Watts DC. The effect of smear layer on the push-out bond strength of root canal calcium silicate cements. *Dent Mater* 2013;29(7):797-803.
41. POPOVIĆ-BAJIĆ MA, Prokić B, Prokić BB, Jokanović V, DANILOVIĆ V, Živković S. Histological evaluation of direct pulp capping with novel nanostructural materials based on active silicate cements and Biodentine® on pulp tissue. *Acta Veterinaria* 2013;63.
42. Cauwels R, Rajasekharan S, Martens L. Regenerative endodontic treatment with Biodentine (tm) in necrotic immature permanent teeth. In 12th Congress of the European Academy of Paediatric Dentistry (EAPD) 2014.
43. Villat C, Grosogeat B, Seux D, Farge P. Conservative approach of a symptomatic carious immature permanent tooth using a tricalcium silicate cement (Biodentine): a case report. *Restor Dent Endod* 2013;38(4):258-62.
44. Pawar AM, Kokate SR, Shah RA. Management of a large periapical lesion using Biodentine™ as retrograde restoration with eighteen months evident follow up. *J Conserv Dent JCD* 2013;16(6):573.

How to cite this article: Rajendraprasad D. Review on biodentine: A boon to pediatric dentistry. *Int J Oral Health Dent* 2019;5(2):55-8.