

Endo-Perio restorative continuum-a case report

Krupali Shah^{1,*}, N.Vimala², Trupti Naykodi³, Suyog Dharmadikari⁴, Leena Padhye⁵

¹PG Student, ^{2,5}Professor, Dept. of Endodontics, ³PG Student, ⁴Associate Professor, Dept. of Periodontics, Dr. DY Patil School of Dentistry, Maharashtra

***Corresponding Author:**

Email: krupalishah2002@gmail.com

Abstract

The relationship between pulpal and periodontal diseases was described first by Simring and Goldberg in 1964.⁽¹⁾ It is caused due to cross infection between the root canal and periodontal ligament.⁽²⁾ It occurs by the way of intimate vascular and anatomic connection between the pulp and periodontium.⁽³⁾ Lesion of the alveolar bone and the periodontal ligament may originate either from the pulp tissue or the periodontium. Teeth with necrotic pulp shows periradicular bone loss secondary to endodontic pathosis. The goal of endodontic and periodontal therapy is to maintain the natural dentition and also to restore the lost periodontium. In this case routine endodontic treatment, periodontal flap surgery with crown lengthening followed by post and core and a full crown restoration was done in 45 and 46. Thus the treatment of endodontic-periodontal lesion requires both endodontic and periodontal regenerative treatments.⁽⁴⁾

Keywords: Endo-perio lesions, Bone graft, rhPDGF, Chorion membrane, Fiber post.

Introduction

The ultimate goal of dental therapy is preservation of natural dentition.⁽⁴⁾ Term “endo-perio” lesion describes lesion caused due to inflammatory products found in periodontium and the pulp in varying degrees.⁽⁵⁾

Tissue of pulp and periodontium are interlinked from the embryonic stage. The dental papilla and dental sac have common mesodermal origin. The cross infection between periodontal ligament and the root canal can occur via anatomic pathway, lateral or accessory canals, apical foramen, palatogingival grooves, dentinal tubules etc.⁽²⁾ Main etiological factors are bacteria, fungi viruses as well as root resorption, dental malformations, perforations, etc.⁽⁶⁾ The bacteria rapidly invades and colonize in a necrotic pulp. The inflammatory by products of the pulp may leach out through these pathways and an inflammatory vascular response in the periodontium is initiated. This causes destruction of the periodontal fibers and resorption of the alveolar bone and cementum.⁽⁶⁾

The role of pulpal pathology in the cause of furcation involvement is unclear. There is high incidence of molar teeth with accessory canals. Furcation involvement presents as a major challenge in endodontic therapy.⁽⁵⁾

The treatment of endo perio lesion requires both endodontic therapy and periodontal treatment along with restorative treatment.

Case Report

An 18 year old female patient reported with decayed teeth in the lower right posterior region. Past medical and dental histories were noncontributory. On intraoral examination, teeth 45 and 46 showed deep carious lesion. On periodontal examination there was deep periodontal pocket of around 10 mm on the buccal wall

of 46. Teeth were tender on both horizontal and vertical percussion. Tooth 45 was vital and 46 was non-vital on heat and cold test. Tooth 47 was missing. Radiographic examination revealed radiolucency involving the furcation area in relation to tooth 46 (Fig. 1.a). On clinical and radiographic examination the patient was diagnosed with primary endodontic lesion with secondary periodontal condition.

Treatment Plan

A multidisciplinary approach was formulated to salvage the tooth. Root canal treatment of 45 and 46 was proposed to the patient and treatment was initiated. Caries excavation and access cavity was made using endo-access bur. Working length was determined using Root ZX mini apex locator (J MORITA, Japan) and confirmed on RVG (Fig. 1.b, Fig. 1.c). Cleaning and shaping was done using K files and hand protaper till F1. During cleaning and shaping, and recapitulation, copious irrigation was done with saline and 2.5% sodium hypochlorite. Master cone radiograph was taken using F1 cones (Fig. 1.d). Final irrigation was done using saline. Canals were dried with paper points. Zinc oxide eugenol cement was used as sealer and obturation done (Fig. 1.e). Temporary restoration was given to seal access cavity (Fig. 1.f). The teeth were kept under observation for a month. There was no change in the periodontal condition of the tooth 46. Hence periodontal regenerative surgery was planned for treatment of furcation defect. First crevicular incision was placed & full thickness flap was elevated buccally. After reflection thorough degranulation and debridement was done of the defect area in tooth number 46 (Fig. 1.g). Intrabony defect was seen after complete degranulation (Fig. 1.h). After root planing, adequate isolation of area was done with proper bleeding control and bone graft material combined with

a recombinant human platelet derived growth factor-BB gel was carried to the area with bone graft (Fig. 1.i, Fig. 1.j, Fig. 1.k). A **chorion membrane** (Freeze dried, irradiated chorion) was placed (Fig. 1.l, Fig. 1.m). The flap was secured with suture and periodontal dressing was given (Fig. 1.n, Fig. 1.o, Fig. 1.p). After 2 months post and core procedure was carried out in 45 and distal root of 46 (post space was prepared till the size of no. 2 Peeso Reamer and fiber post of size 2 was used) (Fig. 2.a). Fiber post were placed in 45 and the distal canal of 46 followed by core build up (Fig. 2.b, Fig. 2.c, Fig. 2.d). Crown lengthening procedure was carried out for both the teeth (Fig. 2.e). Crown preparation of the teeth were done and the teeth were given full metal crowns (Fig. 3).

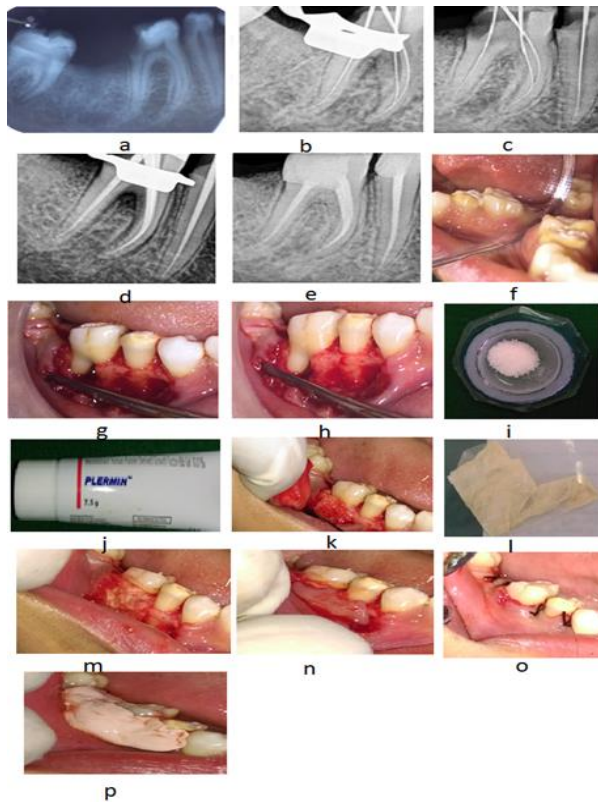


Fig. 1.a: Pre-operative Radiograph; **1.b, 1.c:** Working length Radiograph; **1.d:** Master Cone Radiograph; **1.e:** Obturation Radiograph; **1.f:** Temporary Restoration in 45 & 46; **1.g:** Defect area in tooth 46; **1.h:** Intrabony Defect after Complete Degranulation and Debridment; **1.i:** Bone Graft; **1.j:** rhPDGF; **1.k:** Placement of bone graft and rhPDGF in the defect area; **1.l:** Chorion membrane; **1.m:** Membrane placement in the defect area; **1.n:** position of the flap; **1.o:** flap secured with suture; **1.p:** Periodontal Dressing.

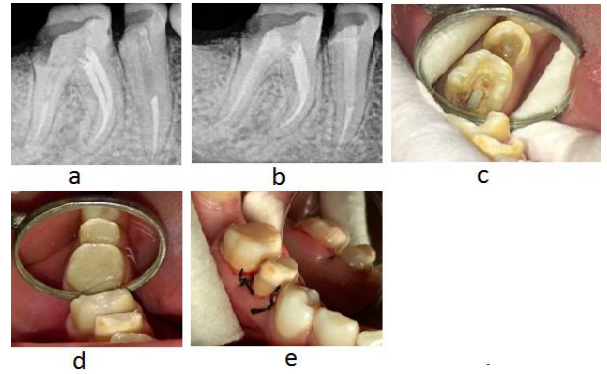


Fig. 2.a: Post Space Preparation; **2.b:** Post Try In; **2.c:** Post cementation; **2.d:** Core Build-up; **2.e:** Crown Lengthening

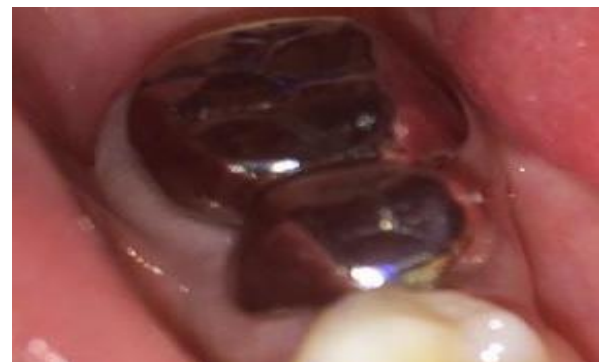

Fig. 3: Metal crown cementation

Discussion

Management of endo- perio lesion is a true challenge. It requires thorough understanding of wound healing process involving both complex tissues.⁽⁷⁾ Endo-perio lesions poses challenge to the clinician as far as diagnosis and prognosis of the teeth are concerned.⁽⁸⁾ Treatment of endo-perio lesion requires both endodontic treatment and periodontal regenerative treatment.⁽⁴⁾ Endodontic treatment precedes periodontal treatment. Depending on the disease status, periodontal therapy may or may not be required. The treatment strategy is to first focus on debridement and disinfection of the root canal system. Second phase includes period of observation.⁽⁹⁾ The goal of periradicular surgery is to remove all necrotic tissues from the surgical site and facilitate the regeneration of hard and soft tissue along with the formation of new attachment apparatus.⁽⁴⁾

Bone grafts aid in healing. They are used as fillers in periodontal defects. They have osteogenic, osteoinductive and osteoconductive properties.⁽¹⁰⁾ Bone graft used was OSSIFI (combined beta tricalcium phosphate plus hydroxyapatite). Hydroxyapatite have great potential as one graft material. Tri calcium phosphate is known as whitlockite. It occurs in alpha and beta phases. It has no adverse effect on cell count, viability and morphology and it provides a matrix that favours limited cell proliferation.⁽¹¹⁾ They are biocompatible and osteoconductive materials. They

provide a chemical environment and a surface conducive to new bone formation.⁽³⁾ Bone graft material was combined with a recombinant human platelet derived growth factor-BB (PLERMIN). rh-PDGF-BB is a potent mitogen, i.e., it is a stimulator for cell proliferation. It is a chemotactic protein ("direct" cell migration) for PDL fibroblast and alveolar bone cells. It also improves angiogenesis (new blood vessel formation).⁽¹²⁾ A chorion membrane was used as a barrier. It has inherent biological properties. It actively promotes wound healing in lieu of simply providing an occlusive barrier for selective cell repopulation. It possesses variety of proteins. These proteins provides a bioactive matrix that facilitate wound healing. They also contain collagen type I, III, IV, V, VI, platelet derived growth factor- α , (PDGF- α), fibroblast growth factor, laminin-5, transforming growth factor- β , etc. These proteins aid in rapid granulation covering the exposed graft.⁽¹³⁾

Patient was kept under observation for 2 months following which post and core was done. The purpose of post is to retain the core. Fiber posts have their modulus of elasticity similar to dentin and they flex with the root when they under stress. It is believed that they distribute stress more evenly throughout the tooth than metal post thus making the root less susceptible to fracture.⁽¹⁴⁾ Crown lengthening procedure was done. The concept of crown lengthening was first introduced by D. W. Cohen (1962). It was indicated to increase clinical crown height lost because of caries or wear or fracture.⁽¹⁵⁾

Conclusion

This case report has shown the successful management of an endo-perio lesion with multiple treatment procedures and predictable outcome.

References

1. Dr. Syed Wali Peeran, Madhumala Thiruneervannan, Khaled Awidat Abdalla, Marei Hamed Mugarbi, Endo-Perio Lesion, *International Journal of Scientific & Technology Research*, Volume 2, Issue5, May 2013.
2. Dr. Asha Prabhu, Dr. Munaf Maknojjia, Dr. Nupur Sah, Dr. Jyotsna Anjankar, Treatment of Endodontic- Periodontic lesion with combination therapy: PRF and DFDBA, *IOSR Journal of Dental and Medical Science*, Vol 14, Issue 12, Ver IV, (Dec.2015), PP46-51.
3. Sharanappa Kambale, Nagaveni Aspalli, Anil Munavalli, Nishant Ajgaonkar, Roopa Babannavar, A Sequential Approach in Treatment of Endo- Perio Lesion A Case Report, *Journal of Clinical and Diagnostic Research*, 2014 Aug, Vol-8(8):ZD22-ZD24.
4. Puspendra Kumar Verma, Ruchi Srivatava, K.K. Gupta, Amitabh Srivastava, Combined endodontic- Periodontal Lesion: A clinical Dilemma, *Journal of Interdisciplinary Dentistry*, Jul-Dec 2011, Vol-1, Issue-2.
5. Bhaumik Nanavati, Neeta V Bhavsar, Jaydeepchandra mali, Endo periodontal lesion- A case report, *Journal of Advances Oral Research*, Vol4, Issue 1: Jan- Apr 2013.
6. Abhishek Parolia, Toh Choo Gait, Isabel C C.M. Porto, Kundabala Mala, Endo-perio lesion: A dilemma from 19th until 21st century, *Journal of Interdisciplinary Dentistry*, Jan-Apr 2013, Vol-3, Issue-1.
7. Se-Lim Oh, Ashraf F. Fouad, Sang-Hoon Park, Treatment strategy for Guided Tissue Regeneration in Combined Endodontic-Periodontal lesion: Case report and review, *Journal of Endodontics*, Volume 35, Number 10, October 2009.
8. Khalid S. Al-Fouzan, A New Classification of Endodontic-Periodontal Lesions, *International Journal of Dentistry*, Volume 2014.
9. Nina Shenoy, Arvind Shenoy, Endo-perio Lesions: Diagnosis and clinical considerations, *Indian Journal of Dental research*, 21(4), 2010.
10. Bassam Michael Kinaia, Sami M. A. Chogle, Atheel M. Kinaia, Harold E. Goodis, Regenerative Therapy A periodontal- Endodontic Perspective, *Dent Clin N Am* 56(2012)537-547.
11. Sumit Kaushal, Anoop Kapoor, Preetinder singh, Gulsheen Kochhar, Nitin Khuller, Patthi Bhasavraj, Evaluation of OSSIFI as Alloplastic Bone Graft Material in Treatment of Periodontal Infrabony Defects, *Journal of Clinical and Diagnostic Research*, 2014 Oct, Vol-8(10):ZC61-ZC65.
12. Myron Nevins, Marcelo Camelo, Marc L. Nevins, Robert K. Schenk, and Samuel E. Lynch, Periodontal Regeneration in Humans Using Recombinant Human Platelet- Derived Growth Factor-BB (rh- PDGF-BB) and Alloplastic Bone, *Journal of Periodontology*, September 2003.
13. Dan J. Holtzclaw and Nicholas J. toscano, Amnion-Chorion Allograft Barrier Used for Guided Tissue Regeneration Treatment of Periodontal Infrabony Defects: A Retrospective Observational Report, *Clinical Advances in Periodontics*, Vol 3, No. 3, August 2013.
14. Restoration of Endodontically Treated Teeth: The Endodontist's Perspective, Part 1, *The Dental Professional Community By The American Association of Endodontists*, Spring/ Summaer 2004.
15. Dr. Gunjan Gupta, Dr. Ramesh Gupta, Dr. Nishant Gupta, Dr. Udit Gupta, Crown Lengthening Procedures- A Review Article, *IOSR Journal of Dental and Medical Sciences*, volume 14, Issue 4, Ver. 1 (Apr 2015) PP27-37.