

Content available at: <https://www.ipinnovative.com/open-access-journals>

International Journal of Oral Health Dentistry

Journal homepage: www.ijohd.org

Case Report

Managing leukoplakia with diode laser: A report of two cases

Smita Ajit Bacholkar^{1,*}, Amita Navalkar¹¹Dept. of Oral Medicine Diagnosis & Radiology, Dr. G.D. Pol Foundation's YMT Dental College and Hospital, Navi Mumbai, Maharashtra, India

ARTICLE INFO

Article history:

Received 19-03-2023

Accepted 01-04-2023

Available online 15-04-2023

Keywords:

Leukoplakia

Lasers

Tobacco chewing

Malignant transformation

Surgery

ABSTRACT

Oral leukoplakia is the most common precancerous lesion of the oral mucosa. WHO defined it as a lesion which has a white patch or plaque on the oral mucosa that cannot be removed by scraping and cannot be classified clinically or microscopically as another disease process. Management of oral leukoplakia should begin with elimination of predisposing habit. There are currently different approaches in the management of Leukoplakia such as scalpel surgery, systemic carotenoids and antioxidants, electro cauterization, cryotherapy and Lasers. Even though on-surgical options are preferred choice of treatment, it takes time to achieve complete regression of lesion and sometimes may not achieve complete resolution. On the other hand, conventional surgical techniques are invasive and cause trauma to the patient. Excision of precancerous oral lesions using LASER offers comparative advantages over traditional scalpel excision. Laser is an acronym for Light Amplification by stimulated emission of radiation. It is surgical technique which excises the targeted tissue using emission of a monochromatic light of specific wavelength. Because of this property, laser excision of the tissue results in complete bloodless field of surgery, reduced chances of post-surgical inflammation and infections and hence better treatment compliance of the patients towards the surgery. This is one of the important goals for management of oral potentially malignant disorders. We present two case reports of homogeneous leukoplakia treated using diode lasers of wavelength 810nm with follow-up. Both cases did not report any post-operative discomfort or inflammation. The aim of this case report is to highlight the importance of laser excision with minimal complications and better treatment outcomes.

This is an Open Access (OA) journal, and articles are distributed under the terms of the [Creative Commons Attribution-NonCommercial-ShareAlike 4.0 License](https://creativecommons.org/licenses/by-nc-sa/4.0/), which allows others to remix, tweak, and build upon the work non-commercially, as long as appropriate credit is given and the new creations are licensed under the identical terms.

For reprints contact: reprint@ipinnovative.com

1. Introduction

Oral leukoplakia is a potentially malignant lesion encountered by oral diagnosticians very commonly. If not treated in time, malignant transformation may occur following a series of mutations. Malignant transformation always complicates management of such lesions. Along with pharmacotherapeutic agents, surgical treatment options are also available. Even though surgical resection is one of the widely accepted treatments for oral leukoplakia, some of its shortcomings are now pushing the clinicians

more towards newer and convenient technologies like electro cautery, laser resection etc. However, these may be invasive, painful and scarring to the patient. LASERS offer the perfect solution to this.

Lasers offer the least intraoperative hemorrhage with minimal trauma to the patient during and after the procedure. It is safe to use, involves bloodless field of surgery, and has rapid and satisfactory post-operative healing. In this case report, we aim to highlight the significance of laser resection with minimal complications in treating oral potentially malignant lesions.

We present two cases of homogenous leukoplakia surgically treated by laser excision with complete follow up.

* Corresponding author.

E-mail address: bacholkarsmita0@gmail.com (S. A. Bacholkar).

2. Case Report 1

A 53-year old male patient reported to OPD of Dental College and Hospital with a chief complaint of a white patch on left side of inner cheek since past 3-4 months. Patient had habit of tobacco chewing with lime 8-10 times a day since 10-11 years. Clinical examination revealed a widely spread, diffuse, non-scrappable keratotic patch on the left buccal mucosa measuring 4 x 3.5 cms in size. Based on clinical examination, provisional diagnosis of homogeneous leukoplakia was made. Incisional biopsy was performed under local anesthesia. Histopathological examination confirmed the diagnosis of homogeneous leukoplakia. Excision was done using Zolar™ photon diode laser of wavelength 810nm with entire set up including fiber stripper, fiber cleaver and protective eyewear using pulse mode. The laser unit was operated by a well -functioning foot control machine and the entire extent of the lesion was ablated steadily with a smooth finger grip. Follow up post 15 days after surgery revealed that healing was satisfactory and patient was completely asymptomatic.

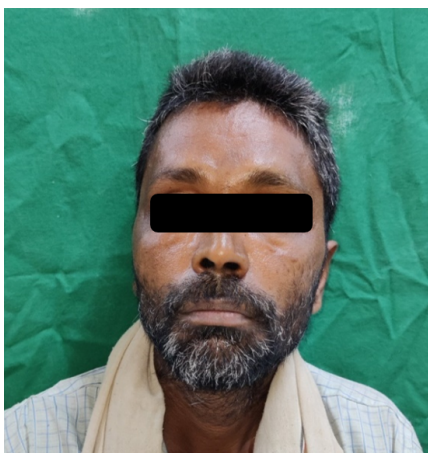

Fig. 1: Profile of the patient

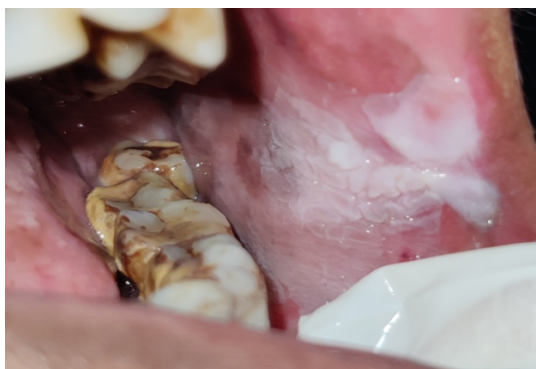

Fig. 2: Leukoplakia on left buccal mucosa

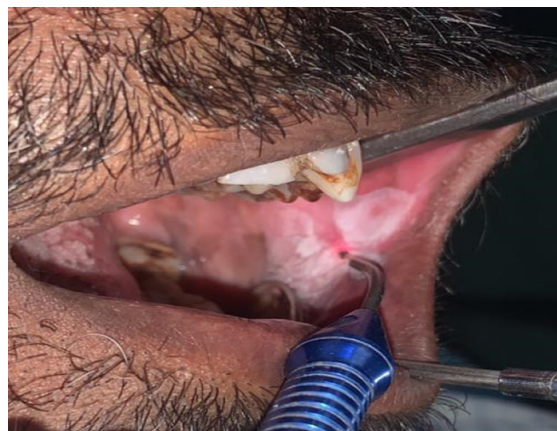

Fig. 3: Laser excision of the lesion

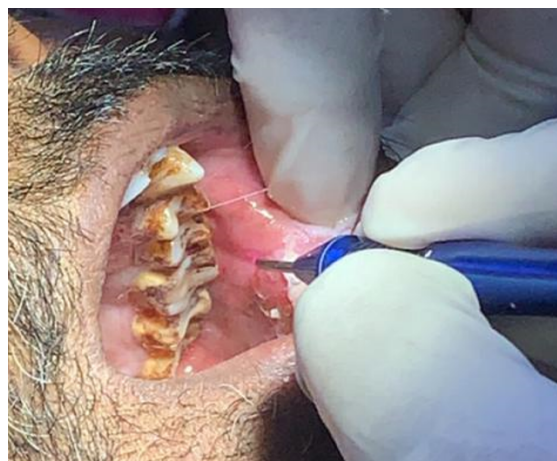

Fig. 4: Laser excision of the lesion

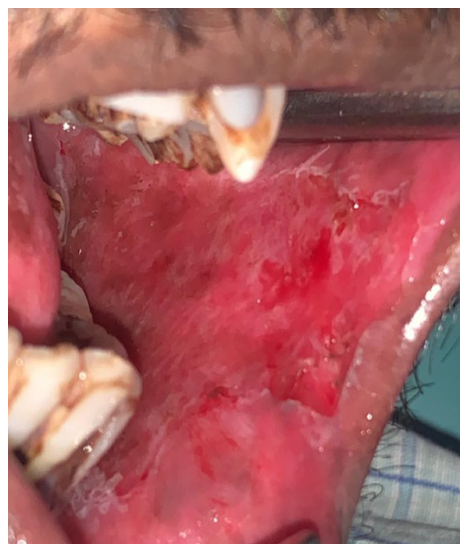

Fig. 5: Surface of mucosa immediately after excision

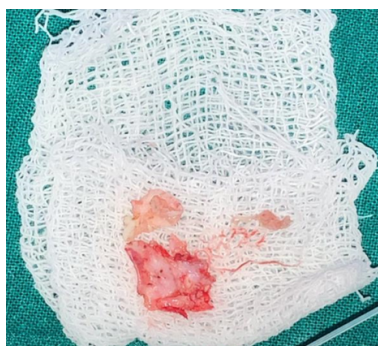

Fig. 6: Charred tissue obtained from the lesion

3. Case Report 2

A 47-year old male patient reported to OPD of Dental College and Hospital with a chief complaint of pain in lower right posterior region of the jaw. Examination revealed severe occlusal caries with 46 with a periapical abscess. Clinical examination also revealed presence of a single, raised, well-defined non-scrappable, linearly spread, densely keratotic plaque for which a diagnosis of homogeneous leukoplakia was made. Vital staining was performed using toluidine blue staining. There was heavy uptake of stain indicating higher indicating a higher risk of dysplastic changes. Incisional biopsy was performed under local anesthesia. Histopathological examination revealed presence of a hyperkeratotic lesion with mild dysplasia. Complete excision was done using Zolar™ photon diode laser of wavelength 810nm with entire set up including fiber stripper, fiber cleaver and protective eyewear using pulse mode. The laser unit was operated by a well -functioning foot control machine and the entire extent of the lesion was ablated steadily with a smooth finger grip. Follow up post 15 days after surgery revealed that healing was satisfactory and patient was completely asymptomatic. Antibiotic cover was prescribed for 5 days.

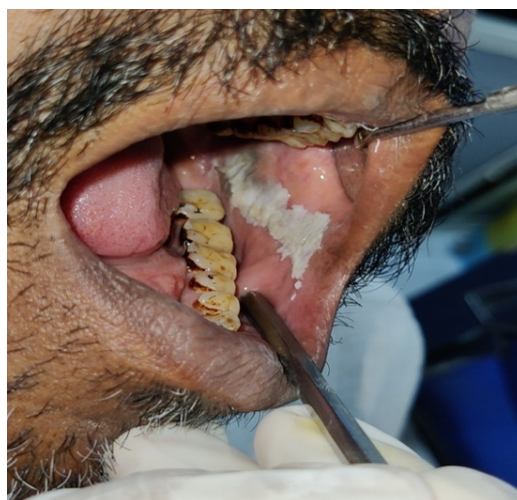

Fig. 8: Homogenous leukoplakia on left buccal mucosa

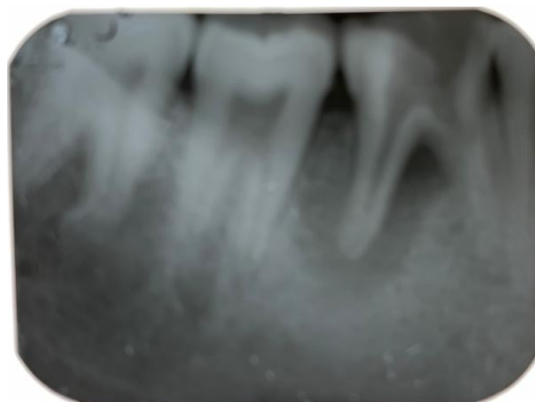


Fig. 9: IOPA of the patient showing periapical abscess with moderate to severe bone loss

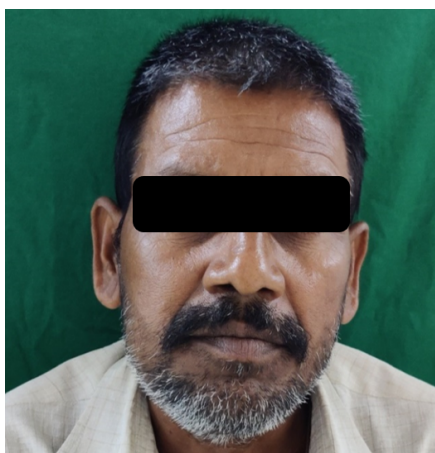

Fig. 7: Profile of the patient

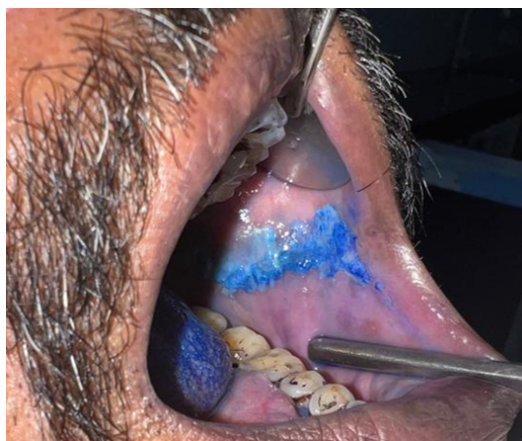

Fig. 10: Toluidine blue staining of the lesion

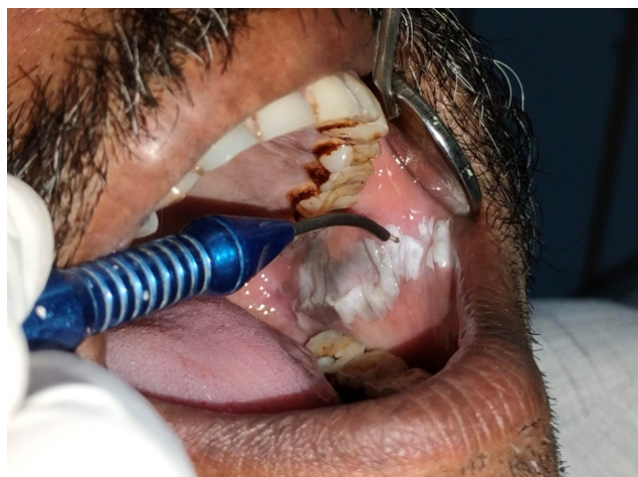

Fig. 11: Laser excision of lesion

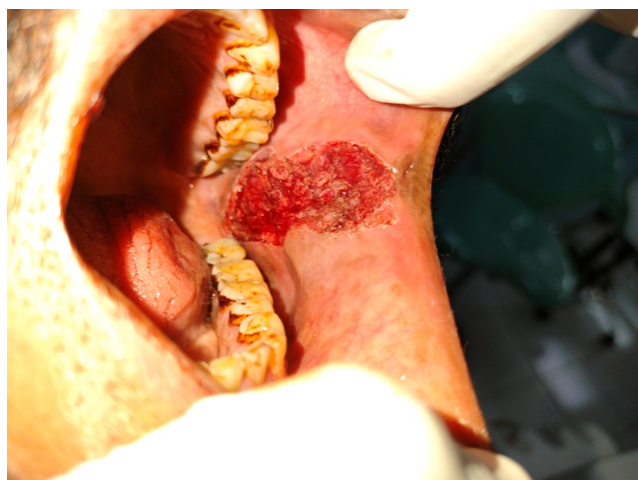

Fig. 12: Oral mucosa post laser excision

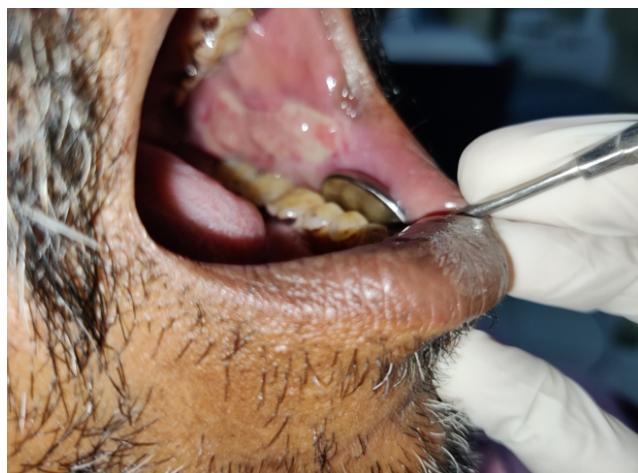

Fig. 13: Healing of oral mucosa 5 days after surgery

4. Discussion

The term 'Leukoplakia' was coined by Schwimmer in 1977. Clinically, the presentation varies from being focal to covering extensive part of oral mucosa; and from faint white plaques to very thick, opaque, heavily keratinized appearance. Diagnosis of leukoplakia is mainly clinical, and treatment depends upon the degree of extension of the lesion. Elimination of the causative agent is first and foremost option towards management. The two cases reported here had a positive history of placing smokeless tobacco in the buccal mucosa and had extensive, raised lesions of leathery consistency extending across the entire mucosa on the affected side.

Management of leukoplakia includes diverse modalities such as surgical and non-surgical treatment options. Non-surgical treatment includes administration of variety of drugs whereas surgical treatment includes conventional surgery using scalpel practiced traditionally. However, higher chances of post-operative infection, pain and scarring post suturing make it an unpleasant experience. Introduction of Laser technology has handed the oral diagnostician a new tool to perform surgery with minimal pain and discomfort and faster healing. For soft tissue ablation, CO₂, diode lasers and Neodymium: yttrium-aluminum garnet (Nd: YAG) lasers are used most commonly. Due to its design, laser technique allows a site specific approach without damaging any part of adjacent mucosa in minimally invasive manner. The Laser probe ablates the tissue precisely covering its entire extent. Post-operative healing is rapid and usually yields satisfactory results. The biggest advantage of laser is that it provides minimal intraoperative hemorrhage with less post-operative inflammation and minimal scarring. However, one of the pitfalls of laser techniques is that no tissue is available for histological examination post-surgery unlike conventional surgical technique. Nonetheless, laser resection of potentially malignant lesions like leukoplakia offers better clinical results with least complications.

Literature suggests that surgical resection with Lasers is a better appreciated surgical method for leukoplakia in past few years.¹ Ishi et al² conducted a study on 97 lesions of oral leukoplakia with an aim to assess the rate of recurrence and malignant transformation following laser resection. Their results revealed that only 1.2% patients treated with laser reported malignant transformation and the rate of recurrence was found to be 29%. The malignant transformation was highest seen in tongue lesions followed by gingival lesions. Based on the results, they concluded that management of oral leukoplakia with lasers lessens not only recurrence and malignant transformation, but also postoperative dysfunction. Hence, laser surgery is an excellent treatment procedure for management of potentially malignant lesions. Similarly, in a case series reported by Katara et al,³ five patients with diagnoses of arteriovenous malformation, homogeneous leukoplakia,

mucocoele, traumatic fibroma, and erosive lichen planus were treated with a diode laser of wavelength 940nm. On the basis of regular follow up, they observed that complete healing of the lesion was rapidly achieved with minimal discomfort. Hence, they concluded that soft tissue lasers provide higher precision, a clean surgical field with minimal blood loss, accelerated wound healing, and fewer postoperative complications. These findings are consistent with the cases reported in this article, where the treatment yielded excellent results and minimal complications. In addition, both the patients were symptom free in the follow up period recorded. Nammour et al⁴ evaluated cases of leukoplakia treated using CO₂ laser excision following which they concluded that laser treatment offers significantly the highest success rate.

Previous studies have reported good post-operative healing with no complications in case of laser resection of leukoplakia.^{2–6} Wladimir Gushiken de⁷ in their reported analysis of 37 cases of laser excision of leukoplakia, reported that in 13/37 patients, leukoplakia recurred; and 8/37 patients, a malignant transformation occurred. Frame et al. have reasoned that the new epithelium formed after laser application which migrates from the periphery to cover the wound may originate from an area of potentially unstable mucosa thereby explaining the recurrence. Hence, even though effective, laser treatment cannot avoid the clinical outcome of recurrence or malignancy. In our cases, both cases were evaluated after 1 week, 15 days and 1 month, and, did not report any post-operative pain, swelling, edema, or any other complications and painless procedure also enhanced their compliance towards treatment. Thus, an important goal of using Lasers is to achieve removal of the lesion with minimal risk of malignancy in the future.

5. Conclusion

Application of Lasers in potentially malignant lesions such as leukoplakia is advantageous, because the tissue reaction is usually superficial in the form of hyperkeratosis and chances of invasion into underlying mucosa are comparatively very few. Management of leukoplakia using Lasers provides an economical, less traumatic technique with minimal post-operative complications. The ease in handling Lasers provides better manipulation and visibility of the surgical field. Cases treated with laser excision of leukoplakia should be closely monitored for recurrence and should be followed up periodically in order to examine

development of any new lesion. In conclusion, Laser surgery is a state of the art technology that best aligns with the desired outcomes for treatment of oral potentially malignant lesions such as leukoplakia.

6. Source of Funding

None.

7. Conflicts of Interest

None.

Acknowledgements

None.

References

1. Deliverska E, Petkova M. Management of oral leukoplakia - analysis of the literature. *J IMAB*. 2017;23(1):1495–1504.
2. Ishii J, Fujita K, Munemoto S, Komori T. Management of oral leukoplakia by laser surgery: relation between recurrence and malignant transformation and clinicopathological features. *J Clin Laser Med Surg*. 2004;22(1):27–33.
3. Katara A, Waghmare M, Kadakia N, Samson S, Minhas R. A case series of treatment of oral mucosal lesions using diode lasers. *Sci Dent J*. 2021;5(1):47–51.
4. Nammour S, Zeinoun T, Namour A, Vanheusden A, Vescovi P. Evaluation of Different Laser-Supported Surgical Protocols for the Treatment of Oral Leukoplakia: A Long-Term Follow-Up. *Photomed Laser Surg*. 2017;35(11):629–38.
5. Chaudhri S, Singh A, Tiwari JD. Oral Leukoplakia Management using Diode LASER: A Case Report. *J Clin Diagn Res*. 2019;13(8):4–6.
6. Azevedo L, Tuma M, Orsini S, Migliari D. Laser Surgery of Extensive Homogeneous Oral Leukoplakia Histologically Suggestive of Proliferative Type: A Case Report. *Case Rep Dermatol*. 2021;13(2):317–20.
7. Campos WG, Esteves CV, Gallo CB, Domaneschi C, Aranha ACC, Lemos C. Treatment of oral leukoplakia with CO₂ laser (10,600 nm): analysis of 37 cases. *Braz Oral Res*. 2022;36:e14.

Author biography

Smita Ajit Bacholkar, 3rd Year PG Resident  <https://orcid.org/0000-0002-2909-7382>

Amita Navalkar, Professor  <https://orcid.org/0009-0007-3188-4725>

Cite this article: Bacholkar SA, Navalkar A. Managing leukoplakia with diode laser: A report of two cases. *Int J Oral Health Dent* 2023;9(1):65–69.