

Palatal Perforation Secondary to Tertiary Syphilis: An Uncommon Presentation and Diagnosis of Exclusion

Sarika Sharma^{1,*}, Sudhanshu Sharma²

¹Consultant, Dept. of Dentistry, R.K Hospital and Research Centre Pandav Nagar, New Delhi

²Assistant Professor, Dept. of Dermatology and Venereology
Shaheed Hasan Khan Mewati Government Medical College, Mewati, Nalhar, Haryana-122107

***Corresponding Author**

E-mail: drsarikasharma27@gmail.com

Abstract

Syphilis is re-emerging as a leading sexually transmitted disease among patients living with acquired immune deficiency syndrome [AIDS]. Dental practitioners are very often seen oral abnormality in the form of palatal perforation but it is very unlikely to see palatal perforation as sole manifestation of tertiary syphilis. Here we present a 36 years old male patient presented with hard palate perforation without any other oral or systemic complaints. Purpose of this case report is to aware dentist about emergence of syphilis as a cause of oral cavity ailment.

Key words: Palatal perforation, tertiary syphilis, treponema pallidum

| Access this article online | |
|--|---|
| Quick Response Code: | Website: www.innovativepublication.com |
|  | DOI: 10.5958/2395-499X.2016.00009.5 |

Introduction

Even after advancement of diagnostic tools, treatment options and preventive measures for sexually transmitted diseases (STD) the incidence of syphilis is rising worldwide[1]. Oral manifestation of syphilis is not very common and palatal perforation secondary to syphilis as a first differential diagnosis is not considered in usual practice. Recent interest has focused on the altered presentation in HIV positive men who are at greater risk of tertiary stage syphilis and have thus increased the likelihood of clinicians witnessing its signs and symptom. Here we present a case of palatal perforation caused by tertiary syphilis. By the reporting of this case we would like to aware dental fraternity regarding reemergence of tertiary syphilis as a possible cause of palatal perforation and keep this as differential diagnosis in mind whenever they come through this type of cases.

Case report

A 36 years old male patient came to the outpatient department of R.K. hospital. His chief complaints were of difficulty in intake of liquid and solid food because of evasion of food and drink through the hard palate to nasal cavity. There is alteration of voice because of palatal perforation. He reported that initially there was appearance of pin head size hole in upper part of mouth

3 months back; it was gradually increased in size to attain coin size lesion.

On general physical examination patient was fairly built and all vital parameters were within normal limit. On systemic examination there was no abnormality detected. On intraoral examination there was a clean based punch out ulcer present on the posterior aspect of hard palate measuring 1.5x2.5 cm in size, yellowish well defined margin and 3x5 mm hole in the centre [fig. 1]. The teeth were distorted and stained. Other than this rest of oral mucosal areas like tongue, soft palate, oropharynx, gingiva, buccal mucosa were normal. Extra oral examination showed no facial abnormality and there was no limitation of mouth opening. On palpation there was significant enlargement of bilateral cervical lymph node. On the basis of history and examination we kept the differential diagnosis of tuberculosis, rhinoscleroderma, actinomycosis, tertiary syphilis.

On haematological study his total leukocytes count was 13500, differential leukocyte count was P-35, L-55, E-8, M-2 and E.S.R-58. Beside this all routine haematological parameters were within normal limit. VDRL test detected titre of 1:32 (strongly positive), TPHA test was also positive. Montoux test showed 5x5 mm induration (negative) fungal culture and bacterial culture was negative for both rhinoscleroderma and actinomycosis respectively. To further confirm the diagnosis mucosal punch biopsy was taken from margin of ulcer under local anaesthesia with the help of 2.5 mm punch and was sent for histological assessment.

The punch biopsy specimen histopathological showed palisaded pattern of the macrophages and fibroblasts, other than these non-specific features plasma cells and fibrotic tissue surrounding the margins was also seen [fig. 2]. Therefore, the histopathological examination confirmed the clinical diagnosis of tertiary syphilis.

With the help of above findings we put our final diagnosis as palatal perforation secondary to tertiary syphilis.

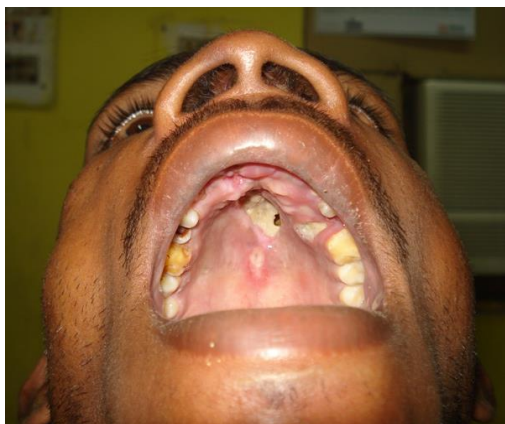

Fig. 1: clean based punch out ulcer present on the posterior aspect of hard palate measuring 1.5x2.5 cm in size, yellowish well defined margin and 3x5 mm hole in the centre

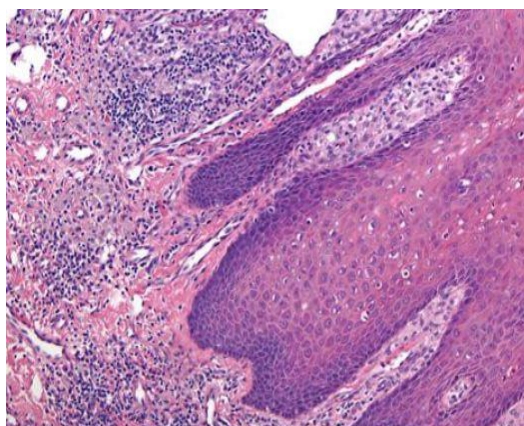


Fig. 2: Non-specific inflammatory infiltrate along with plasma cells and fibrotic tissue surrounding the margins

Discussion

Syphilis is an priority contagious disease among all STD in recent years. It has been return back after emergence of HIV. It can manifest as oral mucosal abnormality in any stage. Ardent information of its various oral presentations is essential for appropriate diagnosis and satisfactory management.

The causative microbe of syphilis is the spirochete *treponema pallidum*. Humans are the solitary identified vectors[2,3]. The route of transmission are through oral-genital, oral-anal, or other sexual contact, transfusion with contaminated blood, direct contact with contaminated material, and intra-uterine transmission[3].

Syphilis been recognized for several centuries as a strong and potentially lethal ailment following its beginning in Europe at the end of the fifteenth century[2]. In 1943 with the discovery of effectiveness of penicillin in the cure of syphilis drastically reduce its

incidence among STD but since the appereance of AIDS there is re-emergence of syphilis as common STD. In the United States, gonococcal infection, herpes genitalis and HIV are three top STD ahead of syphilis.[3].

Genital ulcer secondary to syphilis causes breech in genital mucosa that directly help in the entrance of HIV viral particles and thats why syphilis consider as a prime risk factor for HIV infection. When person with syphilis coinfectd with HIV than there was marked reduction in the efficacy of the treatment[4]. In HIV patients, syphilis may pursue a wicked and lengthened path; it is linked with grave neurological problems and recurrent relapses after usual treatment[2, 4].

Syphilis can be inborn or acquired[2]. The acquired type divided as primary, secondary, latent, and tertiary, according to the duration after contact; primary and secondary are consider when it presents less than one year; if clinical features present for more than one year than it considered as latent syphilis. Congenital syphilis is transmitted to infant inside the uterus through infected mother and according to the onset of anifestation of disease it can be divided as early onset or late onset congenital syphilis.

Tertiary syphilis can be defined as appearance of new lesions in untreated patient after one year of primary lesions[3]. The typical notorious lesion of this stage is gumma. It shows the chronic hypersensitivity reaction against *treponema pallidum*[3]. Clinical features can occur after a unpredictable latency and more commonly affect cutaneous, cardiovascular, and nervous system[2].

In the oral mucosa gumma usually affects hard palate and start with a well defind central ulcerative lesion. Gradually it increases in size and perforate in the centre to the nasal cavity. The tongue looks atrophic, fissured, or lobulated, and leukoplakic plaque is generally present on the dorsal surface. There are chances of malignant changes in gummatous lesion so regular biopsy is recommended in every six months[3]. Tertiary syphilis represents hypersensitivity reaction to spirochete so it is not infectious.

Infection can acquire by direct contact with syphilitic ulcer or blood containing treponemal bodies. Transmission occurs through epithelial breaks and spread occurs via the lymphatic and circulatory systems[6]. The incubation time vary from 10 to 90 days and once the patient is infected than it is very contagious in initial one year if patient not take proper treatment[7]. Tertiary syphilis develops 3-10 years later in 30-40% of patients[5]. It results from the improper treatment or if patient not take treatment for syphilis[8]. Clinical features mainly seen because of endarteritis obliterance of any part of the body[9].

Generally there are three stages of the syphilis but tertiary syphilis also there which is consider more as hypersensitivity reaction instead of active treponemal infection. Oral mucosal lesions can be seen in the any

type of syphilis in any stage and they are very specific to help the diagnosis in doubtful cases. Oral chancre is hallmark lesion of the primary disease, mucosal patch is specific lesion of the secondary stage[9]. Tertiary stage is non-communicable hypersensitivity reaction which clinicopathologically consists of localized granuloma which is called as gumma; the pathognomic lesion of tertiary syphilis. Gumma is asymptomatic but very destructive lesion of this stage and if not manage on time it can causes perforation of underlying structure and cause permanent deformity[7,8,9]. Systemic complications most seriously affect the cardiovascular and nervous systems but are very uncommonly seen[7]. Differential diagnosis of palatal perforation include dental prostheses users, Hansen disease, tertiary syphilis, tuberculosis, rhino scleroderma, naso-oral blastomycosis, leishmaniasis, actinomycosis, histoplasmosis, coccidiomycosis, diphtheria ,lupus erythematosus, sarcoidosis, Crohn's disease, Wegener granulomatosis, neoplasm of nasal sinus, cocaine, heroine, narcotics abuse, following a tooth extraction and oro-antral fistula[10].

Histopathologically gumma consist of non-specific inflammatory infiltrate, endarteritis oblitrens, granuloma, few plasma cells and fibrotic tissue but all of these features are imprecise and does not help in establishing the diagnosis[9]. Serological testing like VDRL test is imprecise; it shows fulminating disease in untreated patients. Confirmatory tests like TPHA will be positive even after successful treatment[7]. Patient management also includes the testing of active treponemal infection in recent or old partners and any other communicable infection.

Treatment of palatal perforation includes treatment of systemic component as well as local component. Opinion of genito-urinary and ENT consultant is also important in the management of syphilis. Penicillin is the main treatment modality and supported with preventive advice and regular visit to physician[7]. Treatment of late syphilis will not reverse the tissue damage but it may result in some improvement. Dental management can resume once the VDRL is negative.

Specific management of the palatal defect may be to do nothing, to seal the defect or to repair the defect. Obturators are a successful method of managing the speech and masticatory problems. Surgery is another option but extensive scarring insyphilitic lesions makes any attempt at palatal repair hazardous[11,12].The patient should remain under review to check for progressive necrosis. Reconstruction is again controversial due to the aetiology of tissue damage. Ischaemia and necrosis render the tissues more likely to breakdown following surgical repair. The better option seems to be the non-surgical conservative approach.

When repair is indicated it is the site and size of the defect which dictates the most appropriate type of flap or graft[12]. In most cases palatal defects and the floor of the nose are usually grafted using standard cleft palate surgery techniques[13]. For the palate local flaps are the best option wherever possible[1]. A recent case, of congenital syphilis, reported successful repair of a large palatal defect using a tongue flap. The success was attributed to the excellent vascular supply and the proximity of the donor and recipient sites[14,15]. Speech therapy was advised as part of the rehabilitation programme. Distal flaps may be an option particularly for large defects. Recent evidence suggests promising results are obtainable with the use of microsurgical forearm flaps[14].

Conflict of Interest: None

Source of Support: Nil

Reference

1. Alam F, Argiriadou A, Hodgson T, Kumar N, Porter S Primary syphilis remains a cause of oral ulceration. *British Dent J* 2000;189:352–354.
2. Monhian N, Murr AH, Mandpe AH, Baehner FL. Pathology forum. Quiz case 1. Secondary syphilis. *Arch. Otolaryngology-Head Neck Surg.*, 2001,127,217-9.
3. Siegal MA. Syphilis and gonorrhoea. *Infect. Dis. Dent.*, 1996,40,369-83.
4. Amador RV., Garcia DLR, Guevara MG, Gutierrez ER, Teran RG. Oral secondary syphilis in a patient with human immunodeficiency virus infection. *Oral Surg., Oral Med., Oral Pathol., Oral Radiol. Endod.*, 1996,81,652-4.
5. Botha PJ, Kruger HEC. A case of oral syphilis. *SADJ* 1999;54:134–135.
6. Ramstad T, Traaholt L. Destruction of the soft palate and nose by tertiary 'benign' syphilis. A case report. *J Oral Rehabil* 1980;7:111–115.
7. Health Protection Agency. HIV and other Sexually Transmitted Infections in the United Kingdom In 2002. Annual Report, November 2003. www.hpa.org.uk/infections/annul 2003.
8. Kearns G, Pogrel MA, Honda G. Intraoral tertiary syphilis (gumma) in a human immunodeficiency virus- positive man: a case report. *J Oral Maxillofac Surg* 1993;51:85–88.
9. Cawson RA, Odell EW. *Essentials of oral pathology and oral medicine*. 6th ed. pp 175–176. London: Churchill Livingstone, 1998.
10. Villa PD. Midfacial complications of prolonged cocaine snorting. *J Can Dent Assoc* 1999;65:218–223.
11. Mosannen Mozaffari P, Seyyedi S, Amir Chaghmaghi M. Palatal Perforation: Causes and Features. *Webmed Central ORAL MEDICINE* 2011;2(4):WMC001890.
12. Cottrell DA, Mehra P, Malloy JC, Ghali GE. Midline palatal perforation. *J Oral Maxillofac Surg* 1999;57:990–995.
13. Deutsch HL, Millard DR. A new cocaine abuse complex. *Arch Otolaryngol Head Neck Surg* 1989;115:235–237.
14. Bhatt AP. Case of the month. Tertiary syphilis. *J Indian Dent Assoc* 1984;56:IBC.
15. Marshall DM, Amjad I, Wolfe SA. Use of the radial forearm flap for deep, central, midfacial defects. *Plast Reconstr Surg* 2003;111:56–64.